

CT Trumps SPECT for Cost-Effective Screening

Average 12-month downstream CAD-related costs were \$1,716 higher in patients who underwent SPECT.

BY KERRI WACHTER
Senior Writer

WASHINGTON — Coronary CT angiography appears to be a less expensive alternative to myocardial perfusion SPECT imaging as an initial diagnostic screen for coronary artery disease, according to an analysis of data from two large regional health plans presented at the annual meeting of the Society of Cardiovascular Computed Tomography.

The average 12-month downstream coronary artery disease–related cost for patients who underwent coronary CT angiography (CTA) as an initial screen for coronary artery disease (CAD) was \$1,716 lower per patient than for those who underwent SPECT, said Dr. James K. Min of Cornell University, New York. By comparison, the average cost of a nuclear study ranged from \$3,000 to \$4,000, he said.

“CT may be a potential, cost-efficient alternative to SPECT for the initial evaluation of patients with suspected coronary artery disease,” said Dr. Min.

The researchers analyzed private payer data from two large regional health plans with more than 6.5 million members from 2002 to 2005. The database included membership information, pharmacy claims, and inpatient and outpatient service claims.

The researchers identified patients

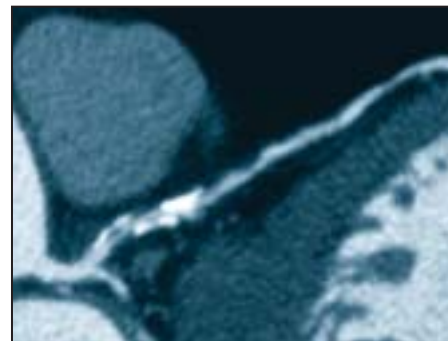
who underwent CTA or MP SPECT imaging as an initial diagnostic screen for coronary artery disease. Information was collected for 1 year prior to and 1 year after the test.

Only patients without known coronary artery disease were included. These were patients who did not have any coronary artery disease–related procedure codes for the previous 12 months. CT and MP SPECT claims included only those with coronary heart disease codes.

For each patient, the researchers calculated a cardiac risk score. The score was a weighted average of several risk factors, including use of digitalis, anticoagulant agents, antiplatelet agents, ACE inhibitors, β -blockers, antihypertensive medication, and antidiabetic medications, as well as the presence of other clinical cardiac conditions. The researchers also assessed each patient’s overall health status using the Charleston Comorbidity Index.

Each patient in the CTA group was matched with four patients in the SPECT group based on age, gender, and cardiac risk score. Both groups had an average age of 51 years. About two-thirds of the patients in each group (68%) were women. The average cardiac risk score was 0.20 in the CTA group and 0.19 in the SPECT group.

A total of 1,833 patients were identified



A CTA reveals diffuse, mixed plaque in the left anterior descending artery.

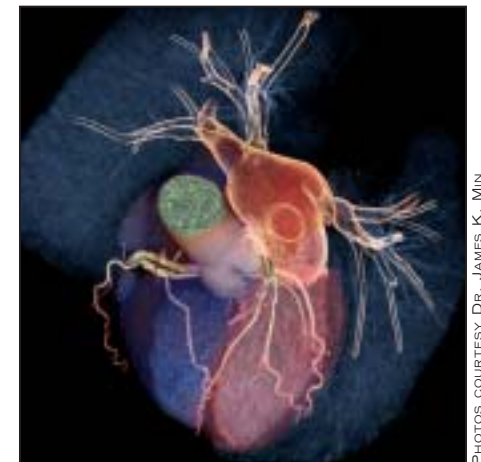who had an initial diagnostic screen with CTA; they were matched with 7,332 patients who had SPECT imaging.

In addition to a cost difference for the two modalities, the researchers noted that the use of antiplatelet therapy was greater among SPECT patients after the initial diagnostic test.

There was also a trend toward greater use of ACE inhibitors and statins in the SPECT group, though this did not achieve significance.

“In terms of follow-up diagnostic tests, patients who initially underwent CT angiography were more likely to undergo nuclear stress testing in the follow-up period, while patients who underwent nuclear stress testing were more likely to undergo invasive coronary angiography,” said Dr. Min. Looking at any diagnostic test, there was an 18% relative risk reduction in patients who underwent initial coronary evaluation with CT angiography.

The researchers also looked at clinical



Here, a multidetector CT volume rendered image shows calcification in the left anterior descending and right coronary arteries.

outcomes. Patients who underwent initial SPECT imaging had a higher rate of surgical or percutaneous interventions in the follow-up period compared with those who had CTA—1.2% compared with 0.4%, respectively.

“CTA patients experienced lower rates of both hospitalization as well as angina or myocardial infarction,” Dr. Min said at the meeting.

“From this we tentatively conclude that compared to MP SPECT patients, patients who underwent CT as an initial diagnostic test incurred lower 12-month total coronary disease-related costs,” said Dr. Min.

Dr. Min disclosed that he receives research support from GE Healthcare, which manufactures both technologies. ■

Combined Therapy Raises Risks in Peripheral Arterial Disease

BY KATE JOHNSON
Montreal Bureau

For patients with peripheral arterial disease, there is substantial risk and no benefit to combining antiplatelet and anticoagulation therapy, according to the results of a large randomized trial.

“We found that combination therapy was not more effective than antiplatelet therapy alone in preventing major cardiovascular complications and was associated with a substantial increase in the risk of life-threatening bleeding,” wrote Dr. Sonia Anand of McMaster University, Hamilton, Ont., and her coinvestigators on the Warfarin Antiplatelet Vascular Evaluation (WAVE) trial (*N. Engl. J. Med.* 2007;357:217-27).

“The totality of evidence shows clearly that the addition of an anticoagulant to an antiplatelet drug results in increased rates of bleeding complications,” wrote Dr. Emile Mohler III of the University of Pennsylvania, Philadelphia, in an editorial appearing in the same issue of the journal (*N. Engl. J. Med.* 2007;357:293-6).

The trial compared outcomes in 1,081 patients randomized to antiplatelet therapy alone and 1,080 patients randomized to a combination of antiplatelet and oral anticoagulant therapy. The mean age of the

patients was 64 years, 74% were male, and the mean follow-up time was 35 months.

There were two coprimary composite outcomes: The first was myocardial infarction, stroke, or death from cardiovascular causes; the second was MI, stroke, severe ischemia of the peripheral or coronary arteries leading to urgent intervention, or death from cardiovascular causes. The safety outcomes were life-threatening, moderate, or minor bleeding episodes.

No significant differences were observed

Treating 1,000 patients with combination therapy as compared with antiplatelet therapy alone for 3 years would lead to 24 fewer cardiovascular events but 28 more episodes of life-threatening bleeding.

between groups for either of the primary outcomes. The first end point occurred in 12.2% of the combination group and 13.3% of the antiplatelet group (relative risk [RR] 0.92), whereas the second end point occurred in 15.9% of the combination group and 17.4% of the antiplatelet group (RR 0.91).

The differences emerged in the safety outcomes. Compared with the antiplatelet group, the combination group showed in-

creases in both life-threatening bleeding (4.0% vs. 1.2%, RR 3.41) and moderate bleeding (2.9% vs. 1.0%, RR 2.82).

“According to our data, treating 1,000 patients with combination therapy as compared with antiplatelet therapy alone for 3 years would lead to 24 fewer cardiovascular events but 28 more episodes of life-threatening bleeding, resulting in a net increase in serious adverse outcomes,” wrote Dr. Anand and her coauthors.

WAVE’s findings of increased bleeding associated with combination therapy (as opposed to antiplatelet therapy alone) differ from a similar comparison of treatments in patients with coronary artery disease (*N. Engl. J. Med.* 2002;347:9609-74) but are consistent with the results of another trial involving patients with peripheral arterial disease (*Lancet* 2000;355:346-51), the investigators noted.

“Therefore, it appears that patients with peripheral arterial disease who are treated with oral anticoagulation may be more likely to have bleeding complications ... than are patients with coronary artery disease.” The reasons for this difference may be that patients with peripheral arterial disease are older, have more systemic atherosclerosis (including cerebrovascular disease), and have more coexisting conditions, they suggested.

The authors noted that the WAVE results are consistent with those of the Department of Veterans Affairs Cooperative Studies Program, the only other large randomized trial comparing these two therapies (*J. Vasc. Surg.* 2002;35:413-21). However, despite this, their results were not what they had expected.

“On the basis of previous clinical trials, we expected that the rates of minor, and possibly of moderate, bleeding would be significantly increased in the combination-therapy group. However, we also expected that the benefits of treatment would outweigh the risks,” the investigators wrote.

There is a rationale for this hypothesis, noted Dr. Mohler. Antiplatelet treatment has proven benefits for peripheral arterial disease, a common feature of which is atherothrombosis, whereas anticoagulation therapy has proven benefits for venous thrombosis.

“Therefore, the addition of oral anticoagulation to antiplatelet treatment might be presumed to be beneficial for the management of atherothrombosis in patients with peripheral arterial disease as well,” he wrote.

A possible reason that this was not found in the WAVE trial could lie in “the differences in thrombus formation between the arterial and venous systems,” he suggested. ■