

Squamous Cell Carcinoma Risk Helps Refine Treatment Options

BY HEIDI SPLETE
Senior Writer

SAN DIEGO — The art of treating skin cancer involves knowing which lesions are high risk and which are low risk, Dr. Ronald P. Rapini said at a meeting sponsored by the American Society for Mohs Surgery.

Patients with high-risk squamous cell carcinomas (SCCs) can be viable candidates for Mohs surgery. High-risk SCCs include those greater than 2 cm in size or 1 cm in depth or those in highly vascular areas such as the lips, said Dr. Rapini, professor and chairman of dermatology at the University of Texas, Houston.

"I think squamous cell is harder to see on slides than basal cell," Dr. Rapini said. When scanning with low power, remember that SCC tends to show up as the color pink, and it can be subtle within the dermis and muscle. For example, SCC often features atypical cells, but well-differentiated SCC might not show atypical cells.

Perineural invasion is present in approximately 10%-20% of SCCs and is more common when the tumor is recurrent or deeper than 2 cm, and approximately 40% of SCC patients report pain or nerve palsy.

Dr. Rapini said that "usually SCCs must be approximately 1 cm thick before they metastasize." Recurrent tumors, tumors that arise from burn scars, and post-radiation tumors are additional examples of high-risk SCCs, as are poorly differentiated tumors, tumors with perineural invasion, and tumors in highly vascular locations, such as the lips or ears. SCCs in transplant patients and in those with pseudoglandular changes are also more likely to be severe.

Spindle cell tumors are a particular problem. The "big three" diagnoses on sun-fried skin are atypical fibroxanthoma, spindle cell squamous carcinoma, and spindle cell melanoma, he said.

Dr. Rapini also discussed other severe types of SCC:

► **Keratoacanthoma.** Specific criteria for a keratoacanthoma diagnosis—a central crater, lack of atypia in histology, and rapid growth—are worthless because they are so common to other cancers, he said. "The claim to fame of keratoacanthoma is spontaneous regression, but if you have a rapidly growing tumor you don't wait for it to regress," Dr. Rapini said, describing a keratoacanthoma as pale and glassy, with not a lot of atypia. "But if there are a lot of atypical cells, I'll just call it SCC," he said.

► **Basosquamous cell carcinoma.**

This condition includes features of both SCC and basal cell carcinoma. Don't call it basosquamous simply because it is keratinizing under ulcers—that is just BCC, Dr. Rapini said. Some basosquamous cell carcinomas have clear cells as well, he added.

► **Verrucous carcinoma.** "I think of this as a wart that went amuck," Dr. Rapini said. This carcinoma appears pale and glassy, with minimal atypia. It does not metastasize, and it looks like a huge, nasty wart. The three most common variations occur on the sole of the foot (epithelioma cuniculatum), the genitals (Buschke-Lowenstein tumor), and mouth (oral florid papillomatosis).

Low-risk categories of SCC include actinic keratosis, Bowen's disease, and inverted follicular keratosis.

Some doctors call an actinic keratosis (AK) a superficial squamous cell carcinoma. AKs are often multifocal, and they can cause problems in the margins during Mohs surgery because they resemble SCC. Some surgeons use Mohs to get the invasive tumor out, and then treat the patient with imiquimod or freeze the edges of the wound after Mohs to treat any precancerous changes in the wound edge. On histopathology, an AK often alter-

nates between pink and blue in the stratum corneum.

"In my opinion, Bowen's [squamous cell carcinoma in situ] is rarely an indication for Mohs surgery," Dr. Rapini said. Most states do not routinely cover Mohs surgery to treat Bowen's disease, and it is rarely necessary. He advised any surgeon who thinks that Mohs is indicated to document the reasons in the patient's chart and use code 173.8 (this depends upon the individual insurance carrier).

The best skin cancer surgeon uses multiple modalities, including Mohs, radiation, and imiquimod.

DR. RAPINI

It has some AK features, but it is not as atypical as SCC.

SCC has many look-alikes, including hypertrophic lichen planus, hypertrophic lupus, prurigo nodularis, sweat duct metaplasia, and healing wounds.

Muscle degeneration also can mimic the squamous cell. "Damaged skeletal muscle may look bizarre, and it can be mistaken for SCC," Dr. Rapini said. "If you aren't sure, you can do a keratin stain."

Adnexal cell metaplasia, sweat ducts, and hair follicles can become metaplastic and strange looking, but none of these are SCC. A tangential section of epidermis—especially if it includes an AK—also can resemble a SCC if it is cut at a 45-degree angle. "A lot of people with squamous cell have AKs in the margins, and you may feel like you can't get clear because their whole face is one big AK," he noted.

When faced with a possible SCC, it's important to determine which lesions are superficial squamous cells and which ones are deep and aggressive. "I think the best skin cancer surgeon uses multiple modalities, including Mohs, radiation, and imiquimod, depending on the individual patient," Dr. Rapini said. ■



Use Low-Power Scanning to Find the BCC

BY HEIDI SPLETE
Senior Writer

SAN DIEGO — When it comes to evaluating basal cell carcinomas for Mohs surgery, experience trumps criteria, Dr. Ronald P. Rapini said at a meeting sponsored by the American Society for Mohs Surgery.

The more slides that physicians review, the better they are at distinguishing basal cell carcinoma (BCC) from other conditions, said Dr. Rapini, professor and chair of dermatology at the University of Texas, Houston, and the M.D. Anderson Cancer Center.

The main problem with BCC as it relates to Mohs surgery is that the cancer tends to resemble follicles, sweat ducts, and sebaceous glands in Mohs sections, he explained.

To best evaluate histopathology slides for basal cell carcinoma, the surgeon should scan images on low power—the equivalent of flying over the tumor in a blimp and looking at it from a distance—and then zoom in for a closer look at anything that appears suspicious.

Get a special condenser for your microscope in order to have a 2x objective view, Dr. Rapini said. These condensers are more expensive but are worth it.

"You have to get in your blimp and look at the tumors from far away," he said. First find the tumor, then note the ink, then correlate it with the Mohs map of the problem area. "I prefer to look at the slide first and then look at the map. Even if the technician has flipped the sections by mistake, you can tell the orientation of the specimen from looking at the ink," Dr. Rapini said.

Looking for a BCC on a histopathology slide is sort of like finding a single black sheep in a herd of white sheep. "Look for bluish aggregates that don't look like they belong," he suggested.

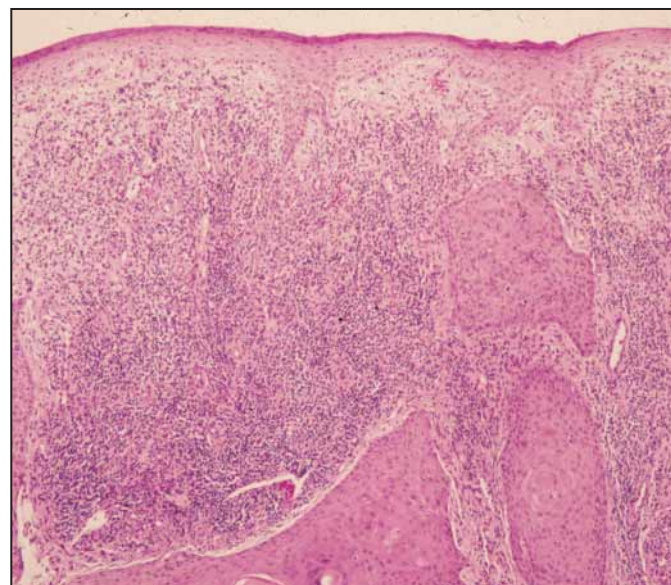
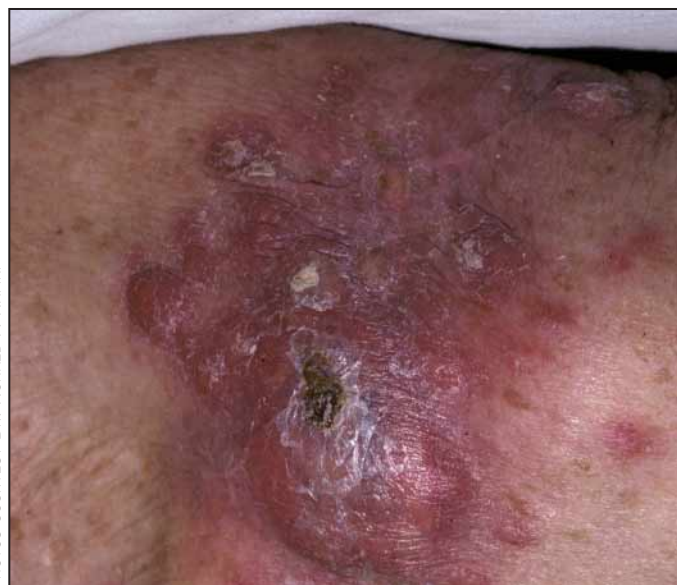Sometimes tumor cells will look like follicles, and sometimes they will clump together. When toluidine blue stain is used, purplish smudges of mucin are more apparent around tumors than around follicles, which can help distinguish between them.

"If you are unsure, scan on low power, and then get closer," Dr. Rapini said. Thick or fixed sections may have brownish areas that make tumor spotting more difficult, and these require a closer look with a higher-powered objective.

BCC often can be distinguished by looking for signs of an inflammatory reaction. Basaloid cells have the ability to differentiate toward sweat ducts, follicles, and sebaceous glands, but this rarely changes the prognosis.

The principal types of basal cell carcinoma are nodular, pigmented, superficial (also known as multicentric), and sclerosing (also known as morpheaform). The term "infiltrating BCC" is also used,

Continued on following page



The patient on the left has recurrent squamous cell carcinoma with satellite nodules and would not be a good candidate for Mohs surgery. The image on the right shows pseudocarcinomatous hyperplasia in a previous biopsy site of a Spitz nevus.

Continued from previous page

but the definition depends on the user; the term has been used to describe any deeply invasive BCC and also has been used as a synonym for sclerosing or morpheiform BCC.

Micronodular BCC is a term currently in vogue in dermatology circles, even though its characteristics have been demonstrated in only one paper.

"It's supposed to be more aggressive than the average basal cell, but in my opinion, this definition is overrated," Dr. Rapini said. Any BCC can be aggressive or nonaggressive. Ordinary nodular BCC can get into bone, for instance, and sclerosing BCC can sometimes prove only a minor problem.

When the tumor does penetrate the bone, a multidisciplinary approach may be needed, including collaboration with a radiation therapist or orthopedist.

Folliculocentric basaloid proliferation is something else to consider in cases of potential BCC. Dr. Rapini cited the journal article that described funny-looking follicles (*Arch. Dermatol.* 1990;126:900-6). "These follicles are benign, but they just look strange," Dr. Rapini said.

"There may be some sort of phenomenon where the nearby basal cell stimulates the follicular infundibulum," he added.

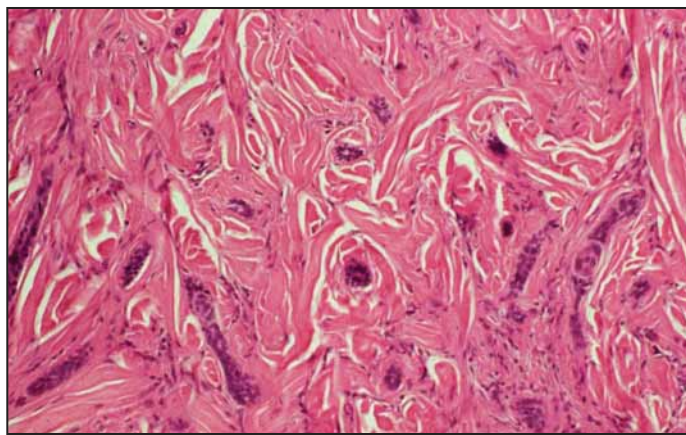
It's critical to remember that evidence of follicular differentiation does not rule out the possibility of BCC, Dr. Rapini noted. However, if papillary mesenchymal bodies, hair bulbs, or hair shafts are present, the area is more likely to be benign than cancerous.

Dr. Rapini recommends deeper cuts and a higher-powered examination to look for things like necrosis and stromal retraction. "The presence of lymphocytes can help distinguish BCC from follicles, but that isn't always reliable, especially in patients with rosacea," he said.

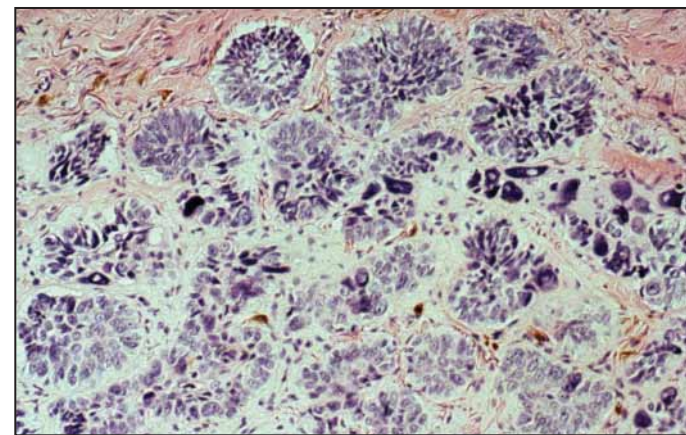
Even when there is follicular differentiation, physicians should not rule out BCC in a patient with a solitary tumor, especially in sun-damaged skin. A benign trichoepithelioma, for instance, can be confused with BCC. With regard to these tumors, Dr. Rapini said, "when in doubt, cut it out."

Dr. Rapini pointed out that breast cancer is the most common tumor to metastasize in the skin, and it can look like a basal cell or sclerosing basal cell carcinoma. A breast cancer tumor usually sits in the dermis, however, without connecting to the surface, and the patient usually mentions a history of breast cancer. Most of these metastases occur on the chest, he said.

Other conditions that simulate basal cell carcinoma include ameloblastoma (a dental tumor inside the mouth), cloacogenic carcinoma (anus), hair follicle tumors, sweat gland tumors, and sebaceous gland tumors. ■



The histopathology of metastatic breast cancer can resemble sclerosing or infiltrating basal cell carcinoma.



Pleomorphic basal cell carcinoma, which is essentially a BCC with giant atypical cells, behaves like any other BCC.

PHOTOS COURTESY DR. RONALD P. RAPINI

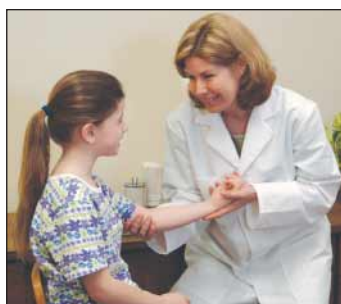Steroid-free pruritus relief for your eczema and atopic dermatitis patients



SARNA® Sensitive Anti-Itch Lotion

- Pramoxine hydrochloride 1%, a highly effective and well-tolerated antipruritic
- Breaks the Itch-Scratch cycle
- No fragrance or paraben preservatives; non-irritating, non-sensitizing
- Moisturizing emollient lotion with dimethicone and petrolatum
- Steroid-free and non-greasy

Available without a prescription
Use only as directed.



Stiefel Laboratories, Inc.
Coral Gables, FL 33134
1-888-STIEFEL (784-3335)
www.stiefel.com

SARNA is a registered trademark of Stiefel Laboratories, Inc.
Research in Dermatology is a trademark of Stiefel Laboratories, Inc.
©Copyright 2005 Stiefel Laboratories, Inc. All rights reserved. SRNSENS-06-2005-USA