

Intensive Glycemic Control May Cause Harm in TBI

BY JANE SALODOF MACNEIL
Contributing Writer

PHOENIX, ARIZ. — Intensive glycemic control—while beneficial for ICU patients in general—may be harmful to patients with traumatic brain injury, Paul M. Vespa, M.D., warned at a meeting sponsored by the Society of Critical Care Medicine.

“When you use intensive glycemic control, you see a higher incidence of abnormal markers in the microdialysis. We don’t know yet whether that’s going to be bad for the brain,” said Dr. Vespa, director of the neurocritical care program at the University of California, Los Angeles.

He urged monitoring of microdialysis values to prevent adverse effects in traumatic brain injury (TBI) patients receiving intensive glycemic control.

Dr. Vespa reported on a small, prospective study that used the Kety-Schmidt method to measure glucose metabolism in 50 patients with TBI who received intermittent subcutaneous insulin (goal of 100-160 mg/dL). Positron emission imaging (PET) was used to measure glucose and oxygen metabolism in 20 patients given continuous insulin infusions (goal of 90-120 mg/dL).

“There was no relationship between serum glucose and PET-derived measure of whole brain glucose metabolism,” Dr. Vespa said.

A microdialysis catheter was used for constant monitoring of the injured area of the brain during continuous insulin infusions in the 15 patients with baseline hyperglycemia. Ten responded with a 70% reduction on average in microdialysis glucose.

In responders, microdialysis values fell below 2 mmol/L 31% of the time, according to Dr. Vespa. In this same group, lactate/pyru-

vate ratios rose above 40 about 60% of the time. Nonresponders had low microdialysis glucose 10% of the time and high lactate/pyruvate ratios 23% of the time.

Dr. Vespa said these values put patients in a “danger or distress range” that has been associated with poor outcomes in published studies. These patients also had elevated lactate/pyruvate ratios, which he described along with low brain glucose as “surrogate markers of brain distress.”

His group is continuing its investigation but with a keen eye on microdialysis values.

“When we are treating the heart with a medication, we monitor the heart, we monitor cardiac enzymes, et cetera. When we treat the brain, most people are not monitoring the brain,” he said.

“This is a study that shows when we take a general medical critical care practice like insulin therapy and apply it to the brain-injured patient, we should be monitoring that patient’s brain.”

Michael Diring, M.D., chair of the SCCM session on clinical neuroscience research, praised Dr. Vespa for raising a red flag, but questioned whether the drop in microdialysis glucose is harmful in the absence of a change in glucose metabolism. Glucose levels went down in the blood, but the brain was using the same amount of glucose.

“So I don’t know what that fall in the microdialysis means. It may not mean anything,” said Dr. Diring of Washington University School of Medicine in St. Louis.

Dr. Vespa noted that in general, intensive insulin therapy has been shown to be beneficial for other types of critical care patients, who often develop hyperglycemia and insulin resistance although they were not diabetic prior to their illness. ■

MRS Shows Differences in Postinjury Brain Metabolism

BY JANE SALODOF MACNEIL
Contributing Writer

PHOENIX — Measurement of N-acetylaspartate with magnetic resonance spectroscopy shows regional differences in brain metabolism after traumatic injury, according to a report at a congress of the Society of Critical Care Medicine.

Paul M. Vespa, M.D., director of neurocritical care at the University of California, Los Angeles, described the ongoing observational study being done by neurosurgeons in the university’s brain injury research center.

He reported that N-acetylaspartate (NAA) levels were most reduced in the area of the brain with the most damage ($P = .0001$), but he noted that other areas also showed effects.

“Even normal-appearing brain regions have low NAA,” he said, showing a skull-like image he called a “phantom replacement model.”

Circles that looked like ping-pong balls represented different concentrations of NAA and filled the model, which was matched with microdialysis.

“You can determine a map of NAA and get actual NAA values throughout the brain,” he said.

NAA is a metabolic marker for mitochondrial dysfunction and corre-

sponded to elevated lactate/pyruvate levels, another sign of distress, in 20 patients studied so far, according to Dr. Vespa. The lowest levels were seen in patients with the longest duration of high lactate/pyruvate levels, he said.

As described by Dr. Vespa, measuring NAA with magnetic resonance spectroscopy (MRS) holds promise as a noninvasive way of assessing damage to areas of the brain missed by microdialysis monitoring.

Microdialysis has the advantage of being continuous, he said, but it only allows a small section to be monitored. MRS can take a picture of the whole brain, he continued, but it can only be used once daily at most and usually only once per hospitalization.

“It [MRS] will be done as a snapshot,” he said. “It won’t be a monitor, but it will be an image of the whole brain. And you will be able to know whether certain segments of the brain are at risk.”

The technology is currently available and in clinical use with brain tumors, according to Dr. Vespa. Before MRS measurements of NAA can be used in assessing traumatic brain injury, these findings need to be confirmed by studies comparing findings to the cerebral metabolic rate of oxygen, he said, adding that those studies are in progress. ■

It won't be a monitor, but an image of the whole brain. 'And you will be able to know whether certain segments of the brain are at risk.'

Consider MRI for Patients Whose CT Doesn't Match Symptoms

BY KATE JOHNSON
Montreal Bureau

CHICAGO — Magnetic resonance imaging can pick up acute cervical spine trauma that is not visible on computed tomography scans, and should be considered in certain trauma patients, according to a study presented at the annual meeting of the Radiological Society of North America.

“Certainly, there is an added cost to ordering an MRI, compared to CT, but when you consider it in the context of such potential catastrophic consequences as quadriplegia, it may not be so expensive,” remarked Joseph Jen-Sho Chen, a 4th-year medical student at the University of Pittsburgh, who presented the research.

Although CT screening is widely accepted as being the standard of care for acute cervical spine injuries, it is not perfect,

Mr. Chen told this newspaper.

“CT is very good for finding bone fractures, but it is known to be very poor for finding soft tissue, ligamentous, and spinal cord injuries, which are much better diagnosed by MRI,” he said.

He estimated that the cost of an MRI is about double that of a CT scan.

In his retrospective review, he assessed the benefit of MRI within 72 hours of a negative CT scan of the cervical spine in 91 level I and II trauma patients.

Almost half (45%) of the cases involved motor vehicle accidents, 29% involved falls, 10% involved other vehicles, 8% involved assault, 4% involved sports, and the rest involved pedestrian/vehicle or occupational accidents.

One-third of the patients presented with focal neurologic deficits, one-third had neck pain, 21% had mental status changes, and 18% were obtunded.

Of the 91 patients, 43 had pos-

itive CT findings, 5 had equivocal findings, and 43 had a negative CT, he said.

Of those patients with a negative CT, 34 had a negative MRI, but 9 (21%) had positive MRI findings.

Additional findings uncovered by MRI included cord compressions (five patients), cord contusion/edema (four), ligamentous injuries (three), epidural hemorrhage (two), and prevertebral edema (one).

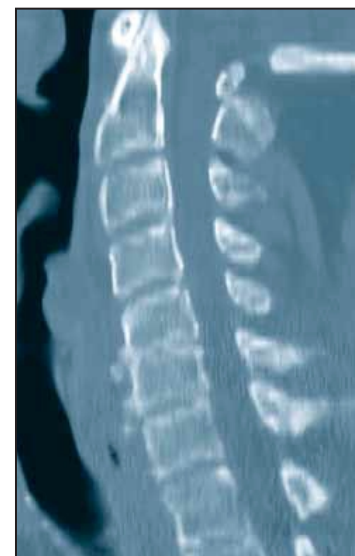
Three of these patients had minor changes to their management based on the additional MRI findings (extended cervical collars) and six had major changes that involved surgery, he said.

Mr. Chen said five of the six patients with additional findings on MRI would likely have received an MRI in most settings, because they had focal neurologic deficits, which is considered an indication for MRI.

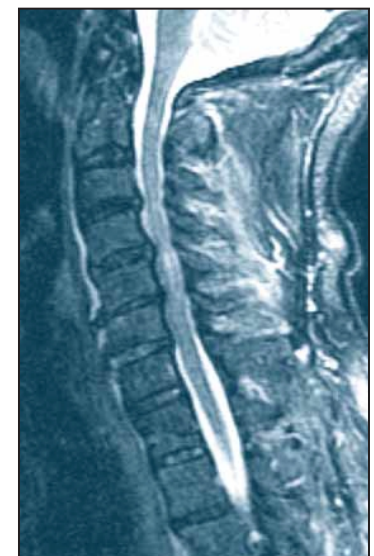However, one patient might not have been referred for MRI in many hospitals because his only complaint was neck pain, Mr. Chen said.

“Definitely patients with focal neurologic deficits should go on

to MRI after a negative CT but also I think [it’s necessary for] patients whose physical symptoms don’t match with the CT scan ... like this patient with severe neck pain and no CT findings,” he said. ■



CT of a trauma patient shows no evidence of osseous injury.



MRI, 36 hours later, shows injuries and cord contusion.