

## Cell-Based Joint/Tissue Repair Doable; Cost Poses Challenge

BY JOHN R. BELL  
Associate Editor

Researchers in joint and tissue repair have mastered the art and science of harvesting skeletal tissue in vitro.

The next challenges to be faced are developing the best repair strategies and making the technologies cost effective, according to Dr. Francesco Dell'Accio and colleagues, who spoke at a translational science session on joint and tissue repair at the annual European Congress of Rheumatology in Amsterdam.

"Cell-based tissue repair is progressively exiting the experimental, 'proof of principle' phase," said Dr. Dell'Accio of King's College London in an interview.

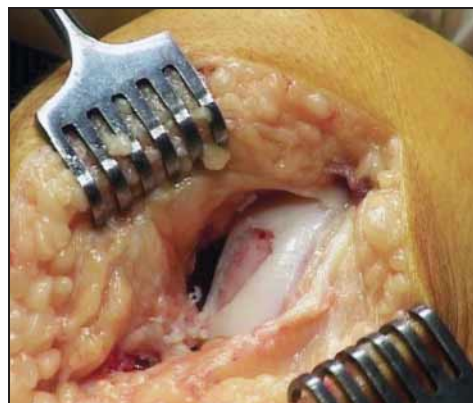
"Obtaining skeletal tissues in vitro from a variety of mature or stem cell populations is not a big challenge anymore. However, for cell-based repair strategies to reach the routine clinical applicability, we should develop cell preparations that consistently and reproducibly differentiate into the desired tissues in the diseased microenvironment." Another important issue is to make such technologies cost effective. Allogeneic stem cell technologies or in situ recruitment of resident cells are important opportunities.

"Finally, biodegradable matrices and scaffolds that allow at the same time delivery (ideally arthroscopically) and containment of the cell preparation and control on tissue formation, patterning and maturation may prove of crucial importance," Dr. Dell'Accio said.

New technologies may soon allow rheumatologists to perform procedures that

traditionally have been the exclusive realm of orthopedists, he noted. "For many years, skeletal tissue repair has been predominantly of orthopedic interest because the inflammatory environment of rheumatic joints has been an obstacle for effective tissue regeneration and for the difficulty of the surgery required. Recently, however, the development of potent tools to control inflammation and the potential of these technologies to be delivered arthroscopically may allow the clinical rheumatologist not only to control inflammation but also to achieve tissue repair and reduce the disability of many rheumatic patients."

It was noted that major new trial data are coming soon, as well as important changes in the regulatory path in Europe to allow development of these treatments into products—notably, a central route through the European Medicines Agency's Committee for Advanced Therapies. ■



Cell-based tissue repair could relieve the pain of superficial osteochondral defects.

## Case: Biologic Effective in Refractory Necrotizing Scleritis

BY NANCY WALSH  
New York Bureau

GLASGOW, SCOTLAND — Treatment with a biologic agent may be life- and sight-saving in cases of refractory necrotizing scleritis, as was the case for a 60-year-old man with a 10-year history of rheumatoid arthritis and a 2-week history of red, painful eyes and blurred vision.

The usual treatment involves systemic corticosteroids and immunosuppressants. Cyclophosphamide is the immunosuppressive drug of choice, Dr. Ismael Atchia explained in a poster session at the annual meeting of the British Society for Rheumatology.

The patient in question had joint stiffness and swelling, vasculitic lesions on the fingers, and the articular deformities typical of chronic RA, according to Dr. Atchia of the rheumatology department, Sunderland (England) Royal Hospital. He appeared cachectic and had several decubitus ulcers. He had been treated with non-steroidal anti-inflammatory drugs, but had never received any disease-modifying antirheumatic drugs.

Ocular examination revealed intense bilateral inflammation manifesting as fulminating, necrotizing scleritis with severe bilateral peripheral ulcerative keratitis that threatened corneal perforation. Laboratory investigations revealed elevated inflammatory markers, with an erythrocyte sedimentation rate of 139 mm/hr, a C-reactive protein

measurement of 149 mg/L, and a positive rheumatoid factor titer of 1:640.

Treatment of the ocular symptoms consisted of intensive topical lubrication with carmellose as well as prophylactic chloramphenicol and autologous serum eyedrops. He also received temporary punctal plugs and underwent bilateral temporary lateral tarsorrhaphies.

Systemic therapy included pulses of intravenous methylprednisolone plus oral prednisone (60 mg/day) along with cyclophosphamide (15 mg/kg) with mesna coverage on three occasions during the ensuing 6 weeks, Dr. Atchia noted. The vasculitic skin lesions cleared with the immunosuppressive treatment, but ocular deterioration continued until the right eye perforated at the temporal limbus.

The patient then received intravenous infliximab (3 mg/kg), plus oral methotrexate (10 mg weekly) and continued treatment with oral prednisone. Additional doses of infliximab were given at weeks 2 and 6.

Within 2 weeks of the first infliximab dose, the patient's eyes improved dramatically, according to Dr. Atchia.

"This case suggests that biologic agents may be considered in refractory cases of sight- and life-threatening scleritis. However, these agents are expensive and have potentially serious side effects, so their long-term efficacy and safety for use in inflammatory eye disease remain to be determined," he concluded. ■

## Remission Achieved by 23.8%

Abatacept from page 1

of abatacept of approximately 10 mg/kg, given as an intravenous infusion on days 1, 15, and 29, and every 4 weeks thereafter.

A significant difference was seen between the two groups on the primary end point of ACR 20 response at 6 months, with 67.9% of patients receiving abatacept achieving this, compared with 39.7% of those receiving placebo, according to Dr. Emery. ACR 50 and 70 responses also were significantly higher in the abatacept group, and this was maintained at 12 months. (See box.)

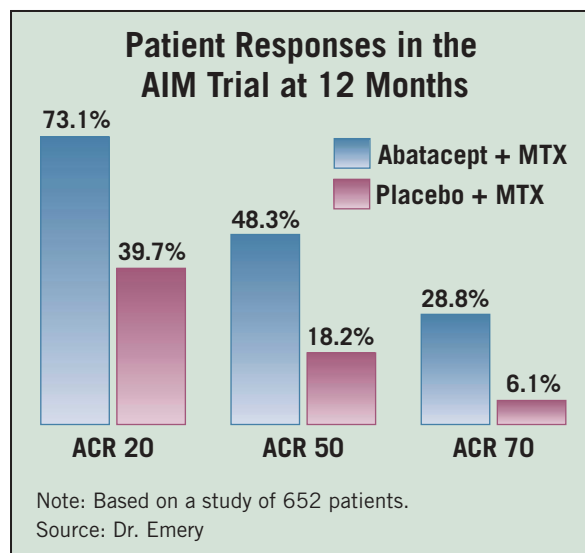
Clinical remission, defined as a disease activity score (DAS 28) of less than 2.6, was achieved at 6 months by 14.8% of patients in the active treatment group and by 2.8% of those in the placebo group. At 1 year, clinical remission had been reached by 23.8% and 1.9% of those in the abatacept and placebo groups, respectively, according to Dr. Emery.

In a second study—the long-term 2-year extension phase of an earlier phase IIb double-blind trial—84 patients receiving abatacept participated and continued to achieve ACR 20, 50, and 70 responses equivalent to those

reached during the 1-year blinded phase of the study.

During the long-term extension, the overall pattern of adverse events was similar to that seen during the double-blind phase of the study, with no new signals or safety concerns (N. Engl. J. Med. 2005;353:1114-23).

Dr. Emery disclosed that he has provided expert advice and lectures for Bristol-Myers Squibb Co., which sponsored these studies. ■



## Hand Bone Loss May Portend RA Diagnosis in Those With Joint Pain

Hand bone loss as noted on a dual-energy absorptiometry scan may make earlier diagnosis of rheumatoid arthritis possible in patients with joint pain, reported Dr. Paul Emery and his colleagues at the University of Leeds, (England).

Dual-energy absorptiometry (DXA) scans in 74 patients with undifferentiated arthritis lasting less than 12 months showed significant changes in hand bone mineral density (BMD) in patients who were eventually diagnosed with rheumatoid arthritis (RA), Dr. Emery and his colleagues reported. "This longitudinal study supports the view that hand BMD loss, even at the earliest stages of the disease process, is related to measures of disease activity and severity in rheumatoid arthritis," the investigators wrote (Ann. Rheum. Dis. 2006;65:736-40).

The study participants were mostly women (88%), with an average age of 44 years. They underwent serial BMD measurements of the hands, femoral neck, and spine (L2-L4) using serial DXA scans at baseline, and at 3, 6, and 12 months, the investigators reported.

None of the patients had received disease-modifying drugs or prednisone prior to the start of the study.

Patients had ongoing diagnostic tests for RA during the study period. Thirteen patients were eventually diagnosed as having RA, 19 patients were determined to have inflammatory nonrheumatoid joint disorders, and the remaining 42 patients were diagnosed with noninflammatory joint disorders, Dr. Emery and his fellow investigators reported.

The results revealed that at 12-month follow-up, none of the patient groups sustained significant bone loss at the femoral neck and spine.

However, patients who were eventually diagnosed with RA had significant hand BMD loss at 12 months, compared with the other patient groups.

In patients diagnosed with RA, hand BMD loss was 4.27%; the inflammatory non-RA group had a 0.49% loss; and the noninflammatory joint disorder group had a BMD loss of 0.87%, the investigators reported.

—Sarah Pressman Lovinger