

Skin Lesions Can Flag Inherited Internal Diseases

BY DOUG BRUNK

EXPERT ANALYSIS FROM THE ANNUAL MEETING OF THE CALIFORNIA SOCIETY OF DERMATOLOGY AND DERMATOLOGIC SURGERY

SANTA BARBARA, CALIF. – Sometimes, changes in skin appearance serve as the first marker of inherited internal disease.

Dr. Bruce H. Thiers highlighted common dermatologic signs associated with several of these syndromes:

► **Cowden syndrome.** This autosomal dominant syndrome is a marker for the eventual development of breast cancer and thyroid tumors. It is characterized by wartlike papules known as trichilemmomas. “They can occur anywhere, especially on the face,” said Dr. Thiers, of the department of dermatology and dermatologic surgery at the Medical University of South Carolina, Charleston.

“You can also see other benign lesions like angiomas and lipomas. I’ve had a few patients with Cowden syndrome who have a strong history of breast cancer and who have elected to have prophylactic mastectomies.”

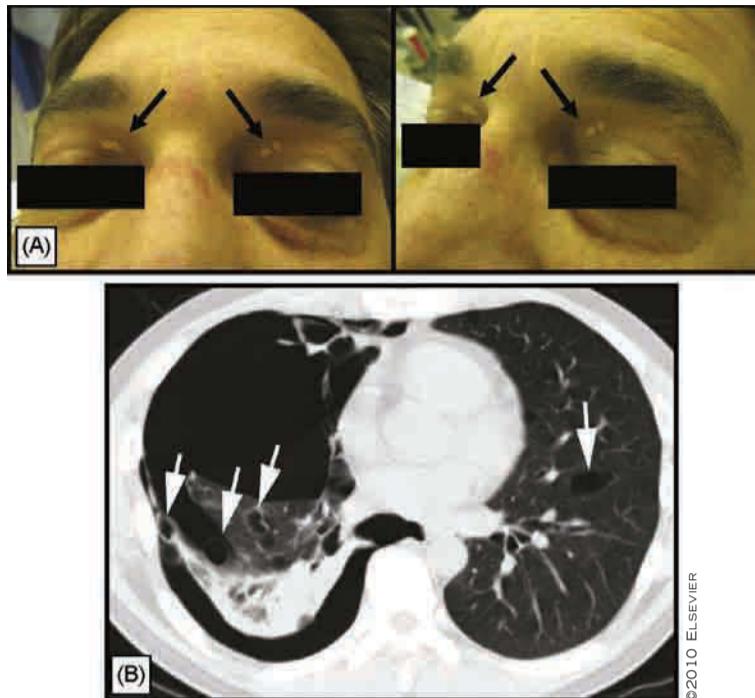
Up to 50% of women with Cowden’s disease get breast cancer, and 10% are diagnosed with thyroid cancer, he added.

► **Gardner syndrome.**

This condition typically presents as deforming epidermoid cysts, though it may also include fibromas, lipomas, leiomyomas, trichoepitheliomas, and neurofibromas. About one-half of patients develop osteomas involving the membranous bones of the face and head. “Many reference sources say that the incidence of colon cancer in Gardner syndrome nears 100%,” said Dr. Thiers. “The standard of care in these patients appears to be frequent colonoscopies with consideration of prophylactic colectomy.”

► **Muir-Torre syndrome.**

This condition is most often associated with carcinoma of the lower gastrointestinal tract, “although the tumors tend to be less aggressive than they are with Gardner syndrome,” Dr. Thiers said. The characteristic lesion is a sebaceous neoplasm, usually located on the trunk. “It could be benign, like a sebaceous



Multiple fibrofolliculomas inferior to the brow (A), and right pneumothorax, right lower lobe atelectasis, and multiple bilateral thin-wall cysts (B), are characteristic of Birt-Hogg-Dubé syndrome.

adenoma, or it could be a sebaceous carcinoma.”

► **Birt-Hogg-Dubé syndrome.** This condition is associated with kidney cancer and is marked by benign fibrofol-

liculomas and trichodiscomas that most often occur on the head and neck. “These patients have an increased incidence of pneumothorax as well,” he said.

► **Hereditary leiomyomatosis and renal cell cancer syndrome.** This condition is marked by cutaneous leiomyomas and papillary renal cell carcinoma. The skin lesions typically occur before the age of 25.

“These patients not only have an increased risk of kidney cancer, but these tumors tend to occur at a very young age, and they tend to be quite aggressive,” Dr. Thiers noted. “If you see a patient with multiple leiomyomas, realize

that this might not be purely a cutaneous phenomenon but part of a significant paraneoplastic syndrome.”

Dr. Thiers said that he had no relevant financial conflicts to disclose. ■

Atopic Children at Increased Risk of Contact Dermatitis

BY DAMIAN McNAMARA

EXPERT ANALYSIS FROM A SEMINAR ON WOMEN’S AND PEDIATRIC DERMATOLOGY


SAN FRANCISCO – What do you consider when one of your atopic pediatric patients has recalcitrant dermatitis? Or a new-onset dermatitis that lasts longer than 2 months? It might be time to expand your differential diagnosis to consider contact dermatitis, said Dr. Sharon Jacob.

There is a high prevalence of allergic contact dermatitis in moderate to severe atopic patients. Also, think systemic allergic contact dermatitis in highly sensitized children. Although more commonly reported in adults, systemic allergies can affect pediatric patients, Dr. Jacob said at a meeting sponsored by Skin Disease Education Foundation (SDEF).

Exposure to nickel, cobalt, fragrances, formaldehyde and balsam of Peru – including from dietary sources – can trigger a systemic reaction. Systemic allergy “should be considered in children with a positive patch test who fail to improve with skin contact avoidance,” she said.

A diet devoid of the suspected trigger(s) for 6 weeks or

more can make a difference for some recalcitrant children, said Dr. Jacob, an assistant clinical professor of medicine (dermatology) and pediatrics at the University of California, San Diego, and at Rady Children’s Hospital. Such an avoidance diet improved the outcome for eight pediatric patients with systemic allergies, according to a recent report from Dr. Jacob and Dr. C.



Nickel, cobalt, formaldehyde, and balsam of Peru can trigger a systemic reaction in atopic children.

DR. JACOB

Matiz (*Pediatr. Dermatol.* 2010 Aug 27 [doi: 10.1111/j.1525-1470.2010.01130.x]).

An avoidance diet is particularly challenging for children with allergy to balsam of Peru. This allergen is found in many foods, including tomatoes, citrus, and certain spices, according to a study in adults (*J. Am. Acad. Dermatol.* 2001;45:377-81).

“The food we have the most problem with is ketchup. Ketchup and pizza are the bane of my existence,” Dr. Jacob said.

Keep the diet simple if possible and encourage adherence with incentives for the child, such as a points and rewards system, she added.

Be careful how you counsel these children, Dr. Jacob said. “Start off with the fact they cannot have asparagus – ‘Yes!’ – or spinach – ‘Yay!’ Then mention ketchup, chocolate, and soda, and you become the evil contact dermatologist.”

Sometimes an affected anatomic site is an important clinical clue. For example, Dr. Jacob described a 10-month-old child with generalized dermatitis who also presented with specific perioral dermatitis. “When we see this we think balsam of Peru.” Involvement of the eyelids is another clinical clue.

Another interesting case Dr. Jacob presented was a toddler with a fragrance contact allergy that triggered a systemic reaction. Initially, however, she had to figure out how a toddler could have an allergy to fragrance. She discovered that the toddler became sensitized from “conjugal contact” – or a physical transfer – of fragrance from the mother’s neck. Following this discovery, the child was do-

ing well until a flare associated with vanilla teething wafers. “It’s amazing how much vanilla is everywhere.”

When an allergen or chemical is transferred by the patient to another site on their body, it is called “ectopic dermatitis.” Dr. Jacob cited the case of a 3-year-old whose older sister lacquered her fingernails, for example. The younger child scratched other areas and reacted to the tosylamide formaldehyde resin on her nails.

If you have a child whose controlled condition suddenly worsens in their atopic areas, consider these potential culprits: lanolin, neomycin, and bacitracin, Dr. Jacob said.

Lanolin is derived from the sebaceous gland in sheep. Although removed from most wool clothing during processing, it remains in cashmere clothing to keep it soft. “Lanolin is a top offender in children – because it is used in emollients,” Dr. Jacob said.

Also assess these patients for exposure to plants in the Compositae family – including feverfew and chamomile.

Keep in mind some components may be found in preparations you prescribe for their atopic dermatitis, such as bisabolol, an alcohol compound

derived from chamomile and found in Aquaphor ointment (Beiersdorf Inc.) and sometimes prescribed for atopic dermatitis in children (*Pediatr. Dermatol.* 2010;27:103-4)

Also watch out for emulsifiers used in diaper creams and topical steroids, including sorbitan sesquioleate. Reports of contact dermatitis to this sorbitan are increasing (*Dermatitis.* 2008;19:339-41).

Dr. Jacob noted that patch testing of children for contact allergies is “off-label” – not approved by the Food and Drug Administration.

A meeting attendee asked Dr. Jacob about the youngest age patient that she will patch test. “I have patch tested a patient as young as 10 months old. But I generally do not patch test children under 5 years old unless absolutely indicated,” she replied.

She first tries “preemptive avoidance” of suspected allergens in these young children before patch testing.

SDEF and this news organization are owned by Elsevier. Dr. Jacob is a speaker for Coria Laboratories, Astellas Pharma, and Shire. She is also an independent investigator for Allergan, maker of the T.R.U.E. test. ■