

New Surgical Technique for Repairing Ingrown Toenails

ARTICLES BY
BETSY BATES
Los Angeles Bureau

FLORENCE, ITALY — An alternative to the classic, 150-year-old surgical technique for repairing ingrown toenails may be associated with fewer recurrences and a much-improved aesthetic result, two dermatologists reported at the 13th Congress of the European Academy of Dermatology and Venereology.

Bernard Noël, M.D., and his coauthor Renato G. Panizzon, M.D., maintain that their technique is superior to Emmert plasty, a procedure that consists of a rather superficial wedge excision of granulation tissue, as well as the adjacent nail bed and the corresponding matrix.

To refine Emmert plasty, however, they first had to scrutinize its steps to understand why it has a recurrence rate as high as 10%-30%.

Dr. Noël and Dr. Panizzon, professor of dermatology at the University of Lausanne (Switzerland), theorized that recurrences may be related to the surgical target of Emmert plasty: the nail, which is narrowed by the radical surgery and sometimes left in a dystrophic state that may be vulnerable to the same pressure that led to the ingrown nail initially.

Moreover, when a significant portion of the nail bed is sacrificed and the nail width is permanently reduced, aesthetic results are often "unsatisfactory," according to Dr. Noël, chief of dermatologic surgery and the wound

healing clinic at Centre Hospitalier Universitaire Vaudois of the University of Lausanne.

By contrast, their approach preserves the nail apparatus while deeply targeting the granulation tissue and reducing the size of the toe itself. "The breadth of the toe extremity is clearly reduced in a way that radically reduces the lateral pressure exerted by the shoes," Dr. Noël said.

"The great toe looks thinner, with a nail plate covering almost completely the distal phalange, reducing, therefore, the risk of recurrence," he noted.

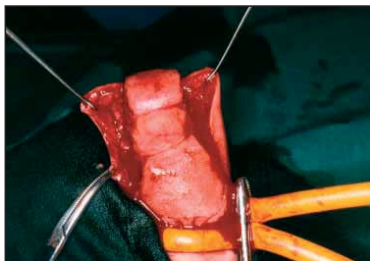
The procedure is performed using a digital block and tourniquet at the toe base. Large, deep excisions remove granulation tissue before the wounds are closed in standard fashion. Among 10 patients followed for a year or more, there has been a 100% success rate and no incidence of recurrence, Dr. Noël and Dr. Panizzon reported in their detailed poster presentation.

The authors believe their findings bode well for patients who are prone to develop ingrown toenails,

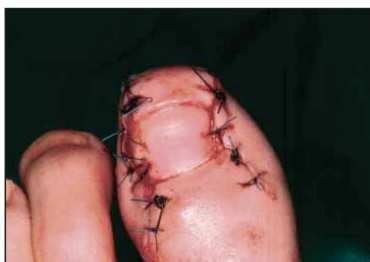which are the most common of all toenail disorders, believed to account for as many as 20% of foot-related physician visits.

Excessive pressure on the lateral toenail due to body weight, ill-fitting shoes, or improperly cut toenails all have been cited as contributors to the inflammation and the formation of granulation tissue that causes nails, usually of the great toe, to become ingrown.

When patient education and conservative therapy fail, repeated recurrences can lead to infections and extreme discomfort. ■



Granulation tissue is removed by using large and deep excisions.



The breadth of the toe is clearly reduced but the nail apparatus is preserved.

PHOTOS COURTESY DR. BERNARD NOËL

If the Shoe Doesn't Fit, Look At the Foot and the Patient

FLORENCE, ITALY — Shove variably shaped human feet into uniformly shaped shoes, some with pointy toes and impossibly narrow widths, and the result will be toenail trauma, one of the most common etiologies of toenail disorders.

Friction of a patient's foot against his or her shoe may cause hyperkeratosis, nail fractures, onycholysis, and/or hematomas, said Bertrand Richert, M.D., a specialist in the nail unit of the department of dermatology at the University of Liège, Belgium, at the 13th Congress of the European Academy of Dermatology and Venereology.

But although shoes get all the bad press, sometimes the anatomy of a patient's foot adds to the problem, Dr. Richert said.

For example, in a classic Greek-type foot, the second toe is longer than the first.

Because most shoes don't accommodate this foot pattern, the second toe has to bend to fit, causing frictional onycholysis, hyperkeratosis of the nail, and sometimes, hemorrhages of the second toe.

"All forces while walking are exerted on the tip of the second toe," he said.

Another common but often-overlooked foot variation causes a shiny dermatosis at the hyponychium and onycholysis with hyperkeratosis on the great toenail.

"Check the foot on a lateral view and you've got the answer. This is hallux erectus," Dr. Richert explained.

In this condition, the great toe veers upward, where it rubs against

the roof of any shoe. The resulting clinical picture can look like psoriasis of the nail or onychomycosis, when the actual culprit is the shape of the foot.

"If you clip off the onychoclavus, you'll reveal the hyperkeratotic process," he said. "This condition is sometimes really painful. People are just unable to wear shoes [until the lesion is trimmed]."

Dr. Richert urged colleagues to carefully examine their patients' bare feet and their shoes before reaching a conclusion about a toenail diagnosis.

What looks like melanoma may actually be a hematoma caused by pressure on the toe by footwear.

Frictional melanonychia can be present on the fifth, fourth, or third toes.

Joggers, tennis players, and squash players often present with lateral nail fractures caused by forceful pressure exerted by the tip of the shoe.

Forceful pressure exerted over time can activate melanocytes.

"Be very careful not to miss a melanoma in situ," he said.

Hallux valgus, the abnormal angulation of the great toe, can cause overlapping of the second toe over the first, or occasionally the first toe over the second, he added.

Surgical excision of hyperkeratotic tumors or lateral horns may be necessary to resolve traumatic toenail issues, but the first and most important treatment approach is conservative, consisting of selection of proper footwear and use of silicon prosthetic devices that can accommodate anatomic foot variations within patients' shoes. ■

Joggers, tennis players, and squash players often present with lateral nail fractures caused by forceful pressure exerted by the tip of the shoe.

Ultrasound, Dermoscopy May Alleviate Need to Biopsy the Nail

FLORENCE, ITALY — High-resolution ultrasound and dermoscopy hold promise for distinguishing straightforward benign nail conditions from suspicious lesions that require a biopsy, researchers said at the 13th Congress of the European Academy of Dermatology and Venereology.

High-frequency ultrasound is valuable because it clearly visualizes landmarks of the normal nail, said Gregor Jemec, M.D., of Roskilde Hospital in Copenhagen. The technique reveals the bilamellar structure of the nail plate with a well-hydrated deep layer, the matrix, a clear subungual space, and bone. These structures are preserved with ultrasound even when the patient is wearing acrylic nails or when there are traumatically induced waves across the nail plate.

The higher the frequency of the ultra-

sound, the more detailed the image. The lowest frequency useful for imaging nails is 15 MHz, while a 28-MHz transducer provides strikingly detailed images of nail structure, Dr. Jemec said.

In discussing patients with psoriasis, Dr. Jemec said the distal portion of the nail may reflect disruption of the nail plate and a hypochoic region, although the matrix is unaffected. By measuring the distance between the nail plate and underlying bone, ultrasound may provide a way to quantify the thickness of psoriatic plaques, either for research purposes or to gauge the effectiveness of therapy, Dr. Jemec said.

He noted that using ultrasound with Doppler enables subungual tumors to be visualized. For example, abnormal blood flow can point to glomus tumors.

Dermoscopy is very useful for determining which pigmented nail conditions warrant a biopsy, explained Luc Thomas, M.D., professor of dermatology at the Hospital de l'Hotel-Dieu in Lyon, France.

He suggested using an antiseptic gel or ultrasound gel to enhance the resolution of dermoscopic images.

In studying dermoscopic images of 148 pigmented nails and comparing them with results from biopsies, Dr. Thomas and his associates noted a number of patterns that provided important diagnostic clues:

► **Blood spots.** Blue-purple following a recent injury and brownish-black later in the healing process, these round spots at the proximal edge of the nail, as well as filamentous patterns at the end of the nail, strongly suggest subungual hemorrhages rather than melanocytic pigmentation.

However, they do not rule out melanoma.

► **Brown longitudinal parallel lines.** These structures are key to distinguishing suspicious lesions that should be biopsied. Are the lines irregular in color, spacing, or thickness? Is the parallel pattern of the lines disrupted?

► **Brown or black background coloration.** This finding suggests melanistic hyperplasia, due to nevi or melanoma.

► **A homogeneous gray background.** This finding does not suggest melanocytic hyperplasia but rather other diseases or characteristics, including unguis lentigo, ethnic pigmentation, or drug- or trauma-induced hyperpigmentation.

► **Micro-Hutchinson's sign.** This rare finding, defined as the absence, or very faint pigmentation, of the cuticle, was seen only in patients with melanoma. ■