

Most Yogurt Probiotics No Match for Infection

BY TIMOTHY F. KIRN
Sacramento Bureau

SALT LAKE CITY — Many physicians who see a patient with acute gastroenteritis suggest the patient go home and eat some yogurt, in Dr. Yoram Elitsur's experience. But, most commercial yogurt probably contains too little *Lactobacillus* species to be of any use, according to his testing of 10 popular brands.

"I am not saying they are cheating us," Dr. Elitsur, director of pediatric gastroenterology at Marshall University, Huntington, W.Va., said in an interview. "All I am saying is that there is not enough *Lactobacillus* in there to treat acute gastroenteritis."

Several studies have suggested that probiotics, such as *Lactobacillus* and *Bifidobacterium* species, may be of benefit in treating acute gastroenteritis, reducing the duration of diarrhea. Surprisingly, they may be more effective when the cause of the gastroenteritis is viral, rather than bacterial, Dr. Elitsur said in a poster presentation at the annual meeting of the North American Society for Pediatric Gastroenterology, Hepatology, and Nutrition.

But the concentration of live *Lactobacillus* species needed to be present is between 10^9 and 10^{11} colony-forming units (CFU) per day.

Dr. Elitsur tested 10 brands of yogurt that said on the label that they were live- and active-culture products. He cultured them on *Lactobacillus*-specific agar plates, and performed polymerase chain reaction (PCR) testing to see if indeed the strains of bacteria in the yogurt were *Lactobacillus acidophilus* and/or *Bifidobacterium bifidum*, the

probiotics shown most often in other studies to be beneficial in gastroenteritis. He found that only the capsule probiotic (Culturelle) that he tested and used as a control had a concentration of live bacteria in the necessary, recommended amount, and that that product had barely the minimum of 7.7×10^9 CFU. Of the 10 yogurt brands, all but one met the National Yogurt Association's minimum concentration, but none had the concentration necessary to provide a benefit for acute gastroenteritis. The brand that did not meet the National Yogurt Association's minimum concentration of 10^8 CFU/g was YoBaby (Stonyfield Farm), which had 4.8×10^7 CFU/g.

The other brands tested included Dannon DanActive, Dannon Fruit on the Bottom, Dannon Activia, Yoplait, Breyers Light Probiotic Plus, Breyers Fruit on the Bottom, Kroger Blended, Kroger Fruit on the Bottom, and Great Value.

The PCR testing showed that only three brands had any live *Bifidobacterium* species.

According to his testing, a child would have to consume about 100 containers of these yogurts in order to get enough probiotic to treat gastroenteritis, Dr. Elitsur said in the interview.

"Anyway you look at it, these companies cannot claim that their yogurt is sufficient to treat gastroenteritis in children," he said.

But then, none of them do make that specific claim, or they would be subject to drug regulation, he added.

Dr. Elitsur said he had no conflicts of interest with any of the products mentioned. ■

Cases of Rocky Mountain Spotted Fever Increase Almost Threefold

BY DOUG BRUNK
San Diego Bureau

SAN DIEGO — Cases of Rocky Mountain spotted fever increased nearly threefold between 2001 and 2005, John Openshaw reported at the annual meeting of the Infectious Diseases Society of America.

An increase in the number of suburban homes that encroach on rural areas is one possible reason for the spike in reported cases, although "increased physician awareness and increased surveillance efforts are [also] involved," Mr. Openshaw said during a press briefing. "The true explanation is likely a combination of many factors."

Rocky Mountain spotted fever is caused by the *Rickettsia rickettsii* bacteria, which are typically spread through tick bites. Early signs of the fever include acute onset of fever and other flulike symptoms, followed by rash.

"The biggest problem is that people often don't remember being bitten by a tick, and by the time the classic rash appears, the disease has already progressed significantly, and it may be too late," Dr. David Swerdlow, previous team leader for the rickettsial zoonoses branch of the Centers for Disease Control and Prevention, said in a prepared statement.

Researchers analyzed data from the National Electronic Telecommunications System for Surveillance and found that during 2001-2005, there were 6,598 cases of Rocky Mountain spotted fever reported in 45 states, said Mr. Openshaw, a medical

student at the University of Pennsylvania, Philadelphia, who worked on the study during a CDC Applied Epidemiology Fellowship in 2006.

The disease resulted in death in 22 people (0.3%) in that period.

The number of cases in the United States increased nearly threefold over the period, from 695 cases in 2001 to 1,936 cases in 2005. The incidence was higher in suburban areas than it was in rural areas, and the largest increase was in the southern Atlantic states.

Despite the increase in the number of cases, the rates of hospitalization fell from 29% in 2001 to 18% in 2005, and the rates of complications from the disease fell from 8% to 4%.

Immunocompromised patients were most likely to be hospitalized with the disease (41%), followed by adults over the age of 70 years (40%) and children under the age of 5 (35%).

Mr. Openshaw also reported that 53 counties in the United States had a fivefold increase in the incidence of Rocky Mountain spotted fever. Moreover, about half of the 1,079 counties reporting disease were newly affected during the study period.

The disease was reported in every state, except Alaska, California, Hawaii, Maine, and Washington.

"Physicians should be aware of the increase in Rocky Mountain spotted fever," he said, adding that they should also be aware of "the difficulty in diagnosing a lot of these patients and the importance of proper treatment." ■



Physicians should be aware of the difficulty of diagnosing these patients and the importance of proper treatment.

MR. OPENSHAW

Textbook Pattern Is Not at All Common in Secondary Syphilis

BY KERRI WACHTER
Senior Writer

BALTIMORE — Secondary syphilis doesn't always have the textbook lichenoid-psoriasiform appearance, said Dr. Timothy H. McCalmont, a professor of clinical pathology at the University of California, San Francisco.

"There's been a resurgence in syphilis. Keep it on your differential diagnosis short list," said Dr. McCalmont. "The mi-

croscopy of this disease is highly varied and the textbook descriptions that are out there are perhaps a little bit on the simplistic side," he said at the annual meeting of the American Society of Dermatopathology.

Dr. McCalmont and his colleagues reviewed their experience with syphilis, which included 23 specimens from 22 patients with a confirmed diagnosis of syphilis. The

confirmation was made by immunohistochemistry, polymerase chain reaction-based assay, or serology.

Histopathologically, most of the 23 samples did not demonstrate the textbook lichenoid-psoriasiform pattern. A lichenoid infiltrate was present in 11 of the specimens (48%),

'Keep [syphilis] on your differential diagnosis short list.' The microscopy of this disease is highly varied and the textbook descriptions are 'perhaps a little bit on the simplistic side.'

whereas psoriasiform epidermal hyperplasia was present in only 8 (35%). Clear involvement of the epidermal-dermal junction was found in 18 (78%). However, 5 (22%) showed wholly dermal involvement.

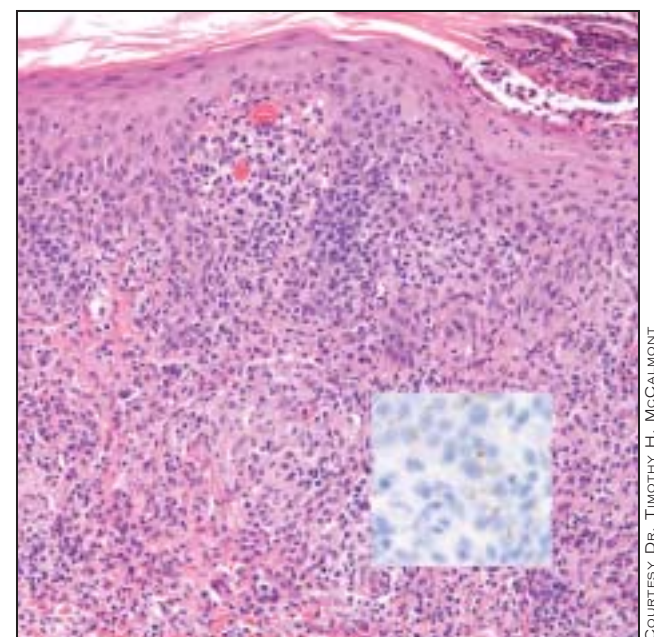
The dermal infiltrate included histiocytes in all specimens, neutrophils in 11 (48%), and plasmacytes in 22 (96%). However, plasmacytes were conspicuous in only

7 specimens (30%). Eosinophils are generally not found in syphilis, and none were found in any of these specimens.

"If you see a juxtaposition of eosinophils and plasma cells, then it's probably not syphilis," said Dr. McCalmont.

When using immunoperoxidase staining for *Treponema pallidum*, look for organisms at the perijunctional zone. "They often tend to have a coiled morphology that is easily picked up on staining," said Dr. McCalmont. The organism load is usually high.

There are a variety of different patterns that can be seen with secondary syphilis, said Dr. McCalmont. In addition to the prototypic lichenoid-psoriasiform pattern, granulomatous, sarcoidlike, and lupus-like patterns can be seen. ■



The main image shows the textbook 'lichenoid-psoriasiform' configuration that is commonly seen in biopsies of secondary syphilis. The inset image shows how the immunoperoxidase staining for *T. pallidum* readily demonstrates the causative spirochetes.