

Parkinson's Mutant Gene Proving to Be Common

BY CHRISTINE KILGORE
Contributing Writer

Neurologists for the first time have reason to be optimistic about the potential usefulness of genetic testing for Parkinson's disease, following two reports that a specific mutation in the *LRRK2* gene is relatively common in patients with Parkinson's disease, according to Dr. Zbigniew Wszolek, professor of neurology at the Mayo Clinic in Jacksonville, Fla.

Specifically, the *LRRK2 G2019S* mutation occurs in 13%-41% of cases in North African Arab and Ashkenazi Jewish patients, according to the two reports. Dr. Wszolek cautioned that uncertainties about the precise penetrance of the mutation mean that "the counseling [for asymptomatic patients] needs to be cautious."

LRRK2 (leucine-rich repeat kinase 2) is the most recent gene to be implicated in Parkinson's disease, and the *G2019S* mutation is the first genetic mutation that appears to be relatively common. The mutation has been linked with autosomal dominant forms of Parkinson's disease.

Reports published in the past year or so on patients primarily of European ancestry—including three reports published last year (CLINICAL NEUROLOGY NEWS, March 2005, p. 24)—have shown that the *G2019S* mutation explained up to 2% of cases of sporadic Parkinson's and 5%-7% of familial cases. The latest reports, which were published as letters to the editor in the New England Journal of Medicine, described a much higher frequency of the *G2019S* mutation among North African Arabs and Ashkenazi Jews.

Researchers at the Beth Israel Medical Center, New York, detected the *G2019S* mutation in 22 of 120 (18%) Ashkenazi Jewish patients with Parkinson's disease and only 4 of 317 (1%) Ashkenazi Jewish patients without the disease.

When there was a familial pattern, 30% (11 of 37 patients) carried the mutation. In the absence of a family history, 13% (11 of 83) had the mutation, reported Laurie J. Ozelius, Ph.D., of Albert Einstein College of Medicine, New York, and associates (N. Engl. J. Med. 2006;354:424-5).

In the other letter, Suzanne Lesage, Ph.D., and colleagues from the French Parkinson's Disease Genetics Study Group described how they looked for the *G2019S* mutation in 104 North African Arabs with Parkinson's disease and 151 healthy Arab controls, and found the frequency to be 37% in familial cases and, "more unexpectedly," 41% in sporadic cases (N. Engl. J. Med. 2006;354:422-3).

Matthew Farrer, Ph.D., of the Morris K. Udall Parkinson's Disease Research Center of Excellence at the Mayo Clinic in Jacksonville, cautioned against putting too much weight on such "convenience sample" reports because they are based on patients who present to the clinic and fall short in terms of epidemiologic rigor. That said, the reports are receiving growing appreciation among experts for showing an interesting pattern of frequency of the mutation in idiopathic or sporadic cases of Parkinson's disease, he said. Frequencies are low in Northern Europe and North America (1%-3%), are higher in Southern Europe (about 10% in southern Spain, for

example), and explode in North Africa (as high as 41%).

Moreover, the mutation is associated with the same haplotype in different populations, which indicates the existence of a common ancestor.

More research needs to be done on the precise penetrance of the mutation for testing and counseling to be more meaningful. Penetrance in carriers at this point is known to be age dependent, increasing from approximately 20% at age 50 to 90% at age 80 and up, Dr. Wszolek said.

Overall, "we can educate as much as we can on the current status of the gene. But the management of the disease doesn't change," Dr. Wszolek said. "We can tell patients that the disease related to this gene is generally well-managed, and the medications are well tolerated." A test for the mutation is not yet commercially available.

The clinical phenotype of both homozygous and heterozygous carriers of the *G2019S* mutation (clusters of homozygotes have been identified) largely mirrors that of typical late-onset, levodopa-responsive, idiopathic Parkinson's disease, Dr. Farrer said. Still, the phenotype varies, even within families, he said.

The most striking variability, though, concerns the neuropathologic features of the disease, he said.

Most cases of *LRRK2* Parkinsonism show the Lewy body disease that is consistent with a postmortem definitive diagnosis of Parkinson's disease. Some cases have tau-positive neurofibrillary tangles without Lewy bodies. Such multiple pathologic expressions have occurred within families as well.

IMAGE OF THE MONTH

Approximately only 75% of patients diagnosed with idiopathic Parkinson's disease (PD) actually prove to have the disease at autopsy. Common alternative diagnoses include multiple system atrophy (MSA), progressive supranuclear palsy (PSP), and corticobasal degeneration (CBD). Clinically differentiating parkinsonian syndromes has proved particularly difficult early in the course of the disease.

"There are a lot of different parkinsonian disorders that look like classical Parkinson's disease, but they have a different prognosis. The typical therapeutic strategies, like deep-brain stimulation and even dopamine agonist drugs, don't work for these patients," said Dr. David Eidelberg of the neurosciences research center of the North Shore-Long Island Jewish Health System in Manhasset, New York. "The prognosis [for the parkinson variant disorders] is uniformly bad. If you have PSP or MSA, for example, not only is your prognosis unfortunately not as good, but surgical treatments are not as effective either," said Dr. Eidelberg.

A number of studies using [¹⁸F]-fluorodeoxyglucose (FDG) positron emission tomography have described characteristic glucose metabolism patterns in patients with PD, MSA, PSP, and CBD. Dr. Eidelberg and his colleague Dr. Thomas Eckert have demonstrated the utility of such imaging as an adjunct to clinical evaluation in differentiating parkinsonian syndromes early in the disease process (Neuroimage 2005;26:912-21).

For this 65-year-old patient and others for whom the clinical diagnosis is uncertain, FDG PET can provide additional information with which to differentiate PD and variant syndromes. Patients at the neurosciences research center are required

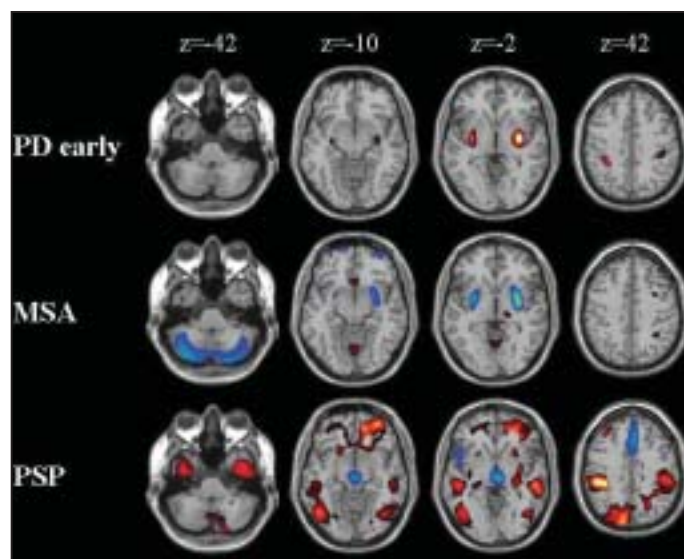
to fast overnight, and antiparkinsonian medications are withheld at least 12 hours before scanning. Scanning yields 35 two-dimensional image planes with an axial field view of 14.5 cm and a transaxial resolution of 4.2 mm in all directions.

For routine visual reading by experts familiar with typical uptake patterns for the different syndromes, the scans are reconstructed, corrected for attenuation, and smoothed for each subject. Images are displayed as a series of 35 transaxial slices.

Dr. Eidelberg, Dr. Eckert, and their colleagues have developed a computer-supported tool that allows nonexperts to read FDG PET scans. The technique uses statistical parametric mapping for all image processing and analyses. Images are spatially normalized and then a smoothing filter is applied to the images. Template statistical maps have been developed to aid in PET scan interpretation. Any voxels showing increased or decreased metabolism in the patient groups (PD, MSA, PSP, or CBD), compared with a group of healthy controls are overlaid onto T1 magnetic resonance template images. These templates are used to assist in the differential diagnosis of single scans.

Individual patient scans can then be compared statistically with a reference group of healthy control subjects. All voxels showing increased or decreased glucose metabolism above a statistical threshold, compared with that of the control group, also are overlaid into the T1 MRI maps. The hallmark of glucose metabolism in

PD patients is increased metabolism in the putamen and globus pallidus and is present bilaterally without regard to the affected side, as seen in this patient's scan. Increased metabolism also is observed in the ventral thalamus, the motor cortex, and the cerebellum. Abnormal reductions in glucose metabolism are present bilaterally in the parietal and occipital association areas and in the dorsolateral prefrontal cortex.



FDG-PET of PD case shows increased metabolism in the putamen and globus pallidus (red/yellow). MSA shows reduction (blue) in the putamen and cerebellum. In PSP, reduction occurs in frontal regions, brain stem, caudate nucleus.

MSA metabolism is characterized by marked bilateral reductions in the putamen and in the cerebellum (see image). Increased metabolism is seen in the frontal and superior parietal and cortical areas and in the thalamus. Hypometabolism is seen in the brainstem.

The distinguishing features of PSP metabolism are the presence of metabolic decrements in midline frontal regions and

in the brainstem (see image). Decreased metabolism is also noted bilaterally in the caudate nucleus. Increased metabolism is seen bilaterally in the cortical motor areas, the parietal cortex, and the thalamus.

Glucose metabolism in CBD is characterized by a distinctive asymmetrical cortical activation (relative hypometabolism contralateral to the most affected side) and asymmetrical basal ganglia metabolism (relative hypometabolism contralateral to the most affected side). Hypometabolism is also seen in the paraventricular areas, the brain stem, and the midline frontal areas (see image).

Dr. Eckert, Dr. Eidelberg, and their colleagues used this computer-assisted technique to aid in the differential diagnosis of parkinsonism in a group of 135 patients for whom the clinical diagnosis was uncertain at the time of referral for imaging. The technique was compared with the final clinical diagnosis, which is the preferred diagnostic method.

The computer-assisted reading technique produced the correct diagnosis in 92% of all subjects—98% for early PD. A sensitivity of 100% and a specificity of 86% were obtained in identifying early PD patients (duration of symptoms less than 5 years), as compared with normal controls. A sensitivity of 96% and a specificity of 91% were achieved for PD patients, compared with patients with presumed atypical parkinsonism. This patient was diagnosed with early PD and was started on dopaminergic medication for 6 months after imaging. Symptoms markedly improved.

—Kerri Wachter