

VTE Risk Tied to Metastatic Disease in Breast Ca

BY BRUCE JANCIN
Denver Bureau

SAN ANTONIO — The incidence of venous thromboembolism in the year following breast cancer diagnosis is roughly 1%, Dr. Helen K. Chew reported at a breast cancer symposium sponsored by the Cancer Therapy and Research Center.

That's a lower figure than previously reported in some clinical trials. But the trials typically feature lengthy exclusion criteria and involve hundreds of patients, whereas Dr. Chew's data carry the authority of big numbers: to be exact, all 108,255 women with breast cancer diagnosed in California during a 4-year period and followed through the California Cancer Registry and California Patient Discharge Data set.

By far the strongest predictor of venous thromboembolism (VTE) in this cohort was the presence of metastatic disease at breast cancer diagnosis. It was associated with a 6.3-fold increased risk, compared

with patients who had localized cancer, said Dr. Chew, director of the breast cancer program at the University of California, Davis, cancer center.

The incidence of VTE was 0.6% in the first 6 months following breast cancer diagnosis and a cumulative 0.9% at the 12-month mark. It fell off thereafter such that the cumulative 2-year incidence was 1.2%.

In a multivariate analysis, regional disease at the time of breast cancer diagnosis—present in 31% of patients—was as-

sociated with a 2.2-fold increased risk of subsequent VTE, compared with localized disease, which was present in 61% of the women. Women age 65 or older had an 80% greater risk than those younger than 45.

The presence of a single comorbidity was associated with a 2.2-fold greater risk of VTE than in women with no comorbid conditions; patients with three comorbid conditions had a 3.3-fold increased risk, compared with those who had none.

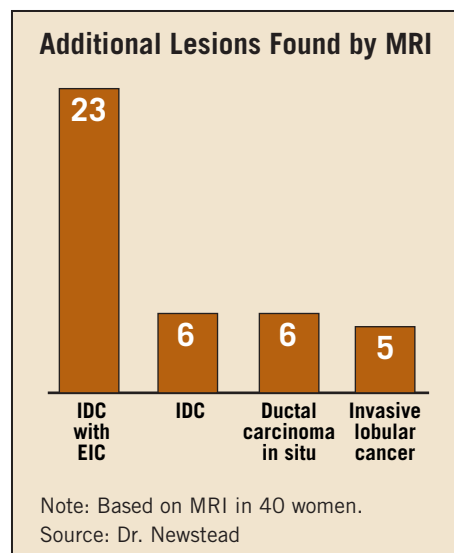
Women of Asian heritage were 70% less likely to experience VTE than whites. Patients who underwent major surgery were half as likely to develop VTE as those who didn't, although Dr. Chew suspects the association isn't causal and more likely reflects localized disease and overall good health. "Patients with metastatic disease generally wouldn't undergo breast cancer surgery," she noted.

Breast cancer histology wasn't predictive of VTE risk. ■

Continued from previous page

"MR is a sensitive modality for detection of early recurrent tumor, and breast cancer recurrence must be differentiated from acute and subacute posttreatment changes. Most recurrent tumor, unlike unrecognized residual tumor, usually presents at least 2 years following breast conservation treatment. Normal parenchymal enhancement usually is diminished after breast irradiation. Recurrent tumor may therefore be readily visible in the postradiation breast," they said.

False-positive findings are not a problem with high-resolution MRI and correct procedure, according to Dr. Newstead. "When we find something on MR that wasn't seen before on mammography or ultrasound, typically we'll bring the patient back for a repeat ultrasound and mammogram. If we see something, we'll do a biopsy right then. But if we can't find anything [with conventional imaging]—which happens in about 40% of our cases—and MR is the only finding, then we'll bring the patient back and repeat the MRI study. If it still looks worrisome, we'll go ahead and biopsy at the same time, so she only has to come back once," Dr. Newstead explained. ■



To help optimize calcium absorption . . .

D

is the difference

- Vitamin D is key to calcium absorption
- According to a large-scale study, 90% of adults aged 51 to 70 don't get enough vitamin D from their diet¹

CALTRATE® 600+D contains vitamin D for enhanced calcium absorption

caltrate.com

Caltrate®

FOR BONE AND COLON HEALTH

Reference: 1. Moore C et al. J Am Diet Assoc. 2004;104:980-983.

Wyeth
Consumer Healthcare
© 2006 Wyeth Consumer Healthcare 1/06 CAL0067