

# Patients Report Satisfaction, Some Pain With Fraxel

BY DOUG BRUNK  
San Diego Bureau

CARLSBAD, CALIF. — The Fraxel laser is “not a panacea,” but patients will see improvement, Dr. Elizabeth F. Rostan said at a symposium on laser and cosmetic surgery sponsored by SkinCare Physicians.

“Patients can achieve significant improvement in fine and deep lines, there’s high patient satisfaction, and importantly, husbands, family members, and friends see improvement. Sometimes if we do a non-ablative [procedure] with [intense pulsed light] they come back in and say ‘my husband doesn’t see any [difference],’” she said while explaining the pros and cons of fractional resurfacing for skin rejuvenation.

One negative is the pain caused by Fraxel treatment. This turns out to be a benefit, though, because any other procedure will probably be perceived as less painful by the patient. “I hear this all the time as I’m injecting filler into their faces: ‘This is nothing compared to that Fraxel,’” she said.

Since many patients looking for improved appearance actually have significant photodamage, the “nonablative meth-

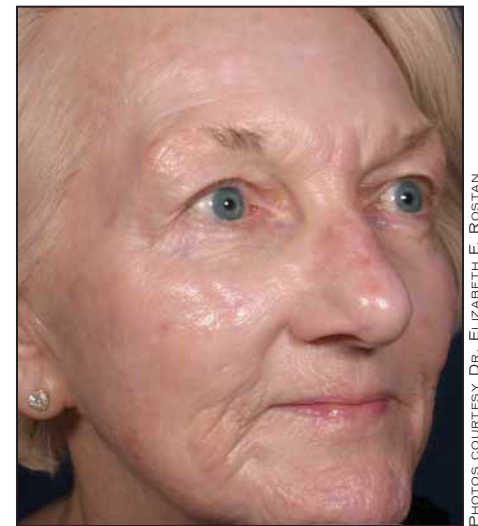
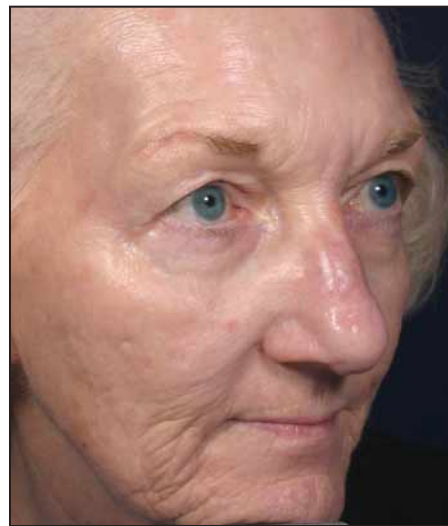ods that we offer them really won’t achieve everything that they want to achieve,” said Dr. Rostan, a dermatologist who practices in Charlotte, N.C.

The Fraxel also is very effective for acne scars. “In fact, this is one of my primary mechanisms of treating acne scars, including younger patients,” said Dr. Rostan, who disclosed that she has previously lectured about Fraxel on behalf of its manufacturer, Reliant Technologies Inc.

For patients who are not ideal candidates for ablative resurfacing—including smokers, those with multiple medical problems, those on immunosuppressant medications, and those for whom close follow-up is not possible—the Fraxel laser is a good option, especially since “I cannot give away CO<sub>2</sub> resurfacing in my area,” she said.

The side effects of ablative resurfacing, such as pigmentary lesions, poor wound healing, infection, and prolonged redness, “have not been fully observed in fractional resurfacing.” On the downside, “there are limited results on lip lines and minimal skin tightening,” Dr. Rostan said.

The procedure can be effective for melasma, but the results have been inconsistent.



This patient underwent Fraxel laser treatment for acne scars, lines, and wrinkles. At right is her outcome at 10 months after five treatments.

PHOTOS COURTESY DR. ELIZABETH F. ROSTAN

“I do have some patients who have not responded in a satisfactory way,” she said.

It is, however, safe and effective for non-facial rejuvenation. “You can get nice improvement on the neck, chest, and hands,” but some areas are difficult to treat, including clavicles and the sternal notch.

Recovery downtime is minimal, but Dr.

Rostan tells patients that posttreatment redness and swelling can occur and last several days. Mild bronzing can last 3-14 days.

The need for multiple treatments can be a problem. For most patients, at least five treatments are required, and each visit involves applying the blue tint, anesthetic ointment, and time for cleanup. ■

## Risk-Benefit Analysis Urged Before Combining Lasers

CARLSBAD, CALIF. — Treating pigmented lesions by combining different lasers “is tempting, since the single-modality approach remains imperfect,” Dr. Jerome M. Garden said at a symposium on laser and cosmetic surgery sponsored by SkinCare Physicians.

The number of available options is “wide open. You can use different wavelengths and different pulse durations. But there is a serious potential for greater side effects,” and it’s worthwhile to ask, “Is it worth it, and is there something as good and maybe safer?” he said.

As a case in point, he discussed a recent study in which researchers used the CO<sub>2</sub> laser and the Q-switched alexandrite laser to treat congenital nevocellular nevi in 11 patients (*Dermatol. Surg.* 2005;31:518-21). The nevi were first treated with one or two CO<sub>2</sub> laser passes to peel off the dermis. This was followed by treatment with the Q-switched alexandrite laser.

The average improvement was 51%-70%, but nearly 30% of patients had hypertrophic scarring. The researchers were “able to get rid of the nevus, but [they] also scarred the whole area, which is something you’re not trying to do,” said Dr. Garden of the department of dermatology at Northwestern University, Chicago.

In a more recent study, researchers used the 532-nm Nd:YAG laser followed by the 1064-nm Q-switched Nd:YAG laser to treat patients with acquired bilateral Hori’s nevus (*Dermatol. Surg.* 2006; 32:34-40). Patients’ right cheeks were treated with the 532-nm laser plus the 1064-nm laser, while the left cheeks were treated with the 1064-nm laser alone. The combination treatment yielded more effective results, but the combined approach also caused more postinflammatory hyperpigmentation.

“I think the reason was that there was just more heat to the area,” Dr. Garden said.

He shared his own experience with one patient whose pigmented lesions he treated with a Q-switched ruby laser and a long-pulsed diode laser. The patient got some reduction in color, but also experienced hypertrophic scarring. “It’s interesting that [this combination approach] is helpful. Unfortunately, because we are tossing in more energy, it’s also very scary in terms of the outcome,” he said.

Dr. Garden disclosed that he has received equipment from Candela, Hoya ConBio, Palomar, and Sinon. He has also received research funding from Candela.

—Doug Brunk

## Anesthesia, Suture Advice Top Procedural Pearls for Defect Closure

BY ROBERT FINN  
San Francisco Bureau

MONTEREY, CALIF. — Closing defects is one of the most challenging tasks in dermatologic surgery, but at the annual meeting of the Pacific Dermatologic Association, Dr. Michael J. Fazio shared several clinical pearls that make the job easier and improve the cosmetic results.

To start with, “don’t scrimp on the setup,” said Dr. Fazio of the University of California, Davis. “Get yourself some nice instruments. I always like to use the golden-handled instruments that have a bit of a sharper edge to them. They last longer, and they sharpen better. They’re a little more expensive, but they go on forever.”

Dr. Fazio finds that skin hooks provide a more delicate and elegant way of handling tissue, compared with forceps. With forceps, it’s important not to pinch down too tightly. Tissue held by the forceps may become necrotic.

Dr. Fazio is a proponent of using bicarbonate in local anesthesia, and he recommends that any physicians who are not using bicarb should try a self-injection. They’ll see that the injection is far more painful without bicarbonate. He recommends a 1:10 dilution, adding 5 mL of stock bicarbonate solution to 50 mL of lidocaine with epinephrine. Bicarbonate can destabilize the lidocaine solution over a long period of time, but that’s usually not an issue in a busy dermatologic surgery practice.

When preparing to remove a lesion, mark the favorable lines of closure before injecting the anesthetic, which may cause distortion. During creation of the ellipse, it’s important that it be long enough; Dr. Fazio prefers that the length be at least three times as long as the width. Inexperienced residents are often reluctant to lengthen the ellipse sufficiently, fearing that the scar will be too large. “If you make a quality scar, you’re not going to see it,” Dr. Fazio said. “If you make a scar and it’s too small,

you’re going to have lumps on both sides [that] are going to be very noticeable.”

Undermine the entire ellipse, the ends as well as the sides, to allow the tissue to slide. As the ellipse is closed it will tend to elongate, and if the ends aren’t mobile they will pucker up.

“As I got older and more experienced I started letting things heal more by second intention,” Dr. Fazio said. But one needs to be selective in allowing things to heal by themselves. The results tend to be better on convex surfaces of the face than on concave surfaces, for example.

Be aware that wounds healed by second intention tend to shrink by about 50%, so it’s not a good idea around free tissue margins such as the eye, nose, and mouth. But on the upper forehead—or even on the scalp in patients lacking hair—second-intention healing can work superbly, especially with a large defect in which it would otherwise be necessary to mobilize a large flap and undermine a wide area.

Second-intention healing also works well in the extremities, and Dr. Fazio prefers this to skin grafts. With split-thickness skin grafts, patients often complain about pain at the donor site, the graft itself can easily become infected, and it can take up to 3 months to heal.

Dr. Fazio’s favorite suture materials are 6-0 fast-absorbing gut and 5-0 monofilament. He advocates closing defects subcutaneously so that the cutaneous sutures are used only for epidermal kissing. He has his patients return in a week for suture removal, but the fast-absorbing gut will be mostly or entirely gone by then, so the return visit is mainly for patient reassurance.

Dr. Fazio favors subcutaneous mattress sutures, which work as well as cutaneous vertical mattress sutures but don’t give the railroad-track effect. He applies the subcutaneous sutures every 2-4 mm along the scar line so that there’s tension on the surface. He then closes the epidermis with a running suture using the 6-0 fast-absorbing gut. ■