

## Children With Migraines Get Inadequate Care at Adult EDs

BY AMY ROTHMAN SCHONFELD  
Contributing Writer

MONTREAL — Children with acute migraine are less likely to be treated according to practice guidelines or with a medication of proven efficacy for pediatric populations, or to have been effectively treated at all if they are cared for in an adult rather than pediatric emergency department, according to a presentation by Dr. Lawrence Richer at the 10th International Child Neurology Congress.

“Adult and pediatric ERs within the same city differ in their treatment of headaches and migraines in children,” commented Dr. Richer, a pediatric neurologist at the University of Alberta, Edmonton, who said this choice “remains the single most important factor in determining outcome.”

Investigators conducted a chart review of 382 children treated for headache or migraine between July 2003 and July 2004 in four emergency departments (three adult, one pediatric) in Edmonton. Of these children, 65% were seen in the pediatric emergency department. The children ranged in age from 2 to 17 years, with a mean age of 11.4 years. About 12% had a previous head injury, and about 11% had symptoms of recent infection.

Richer found management differed between adult and pediatric emergency departments. Children with acute migraines were more likely to have blood work, a lumbar puncture, or a computed tomography scan or other neuroimaging procedure if they were treated at an adult ED than if they went to the pediatric ED.

Children in adult EDs were less likely to be given more than one treatment and more likely to be discharged while symptoms remained unresolved.

NSAIDs—most often acetaminophen—were the most popular first-line therapies in both EDs. Opiates such as codeine and morphine were used less often, although when given they were administered more frequently for children seen in adult EDs than pediatric EDs. Dopamine antagonists were more often prescribed in pediatric than adult EDs. Oral or intravenous triptans were not used in the emergency setting.

Do these treatment choices reflect practice guidelines? In December 2004 (midway through the patient acquisition phase of Dr. Richer’s study), the American Academy of Neurology released guidelines for treating patients with pediatric migraine, and these guidelines were endorsed by the American Academy of Pediatrics and the American Headache Society (Neurology 2004;63:2215-24).

Although no agents are currently approved by the Food and Drug Administration for the acute treatment of migraine in children or adolescents, the guidelines indicated evidence that ibuprofen was effective and acetaminophen was probably effective. No mention was made of the use of opioids. While the guidelines indicated that no adequate data supported or refuted the use of any oral or subcutaneous triptan preparation, good data were available favoring the use of sumatriptan nasal spray for adolescents—a medication apparently not offered by the emergency departments surveyed. ■

## Ibuprofen Found to Be Leader In Pediatric Migraine Relief

BY AMY ROTHMAN SCHONFELD  
Contributing Writer

MONTREAL — Ibuprofen significantly alleviated children’s headache symptoms compared with placebo, according to findings from a metaanalysis of randomized controlled trials that focused on drug therapy for pediatric migraines, Dr. Lori L. Billingham said at the 10th International Child Neurology Congress.

Of more than 4,000 possible inclusions identified from six electronic bibliographic databases, 14 studies met all inclusion criteria. Two randomized controlled trials (RCTs) demonstrated that ibuprofen significantly alleviated headache symptoms, provided complete headache relief, and prevented headache recurrence compared to placebo; no benefits, however, were found for acetaminophen or dihydroergotamine compared to placebo. In one RCT, the dopamine antagonist prochlorperazine was more effective than the NSAID ketorolac, said Dr. Billingham, a neurology resident at the University of Alberta, Edmonton.

As a group, the triptans were better than placebo for alleviating headaches (RR 1.13; 95% CI 1.06, 1.20) and providing complete headache relief (RR 1.34; 95% CI 1.18, 1.52), with sumatriptan the only effective individual medication of the class. Rizatriptan improved headache relief compared with standard care. ■

The metaanalysis also showed a very high placebo rate of 47% for headache alleviation and 21% for headache relief, said Dr. Billingham. Because this problem has become a major impediment for clinical trials, new and innovative study designs are needed to evaluate the efficacy of therapies.

Taken together, these reports reveal disconnection between evidence and practice for acute treatment of pediatric migraines. For instance, there is no evidence to support the use of opiates—but opiates are offered, especially in adult emergency departments. On the other hand, there is evidence to support the use of triptans, especially intranasal sumatriptan, for acute migraine relief—but these were not options in either the adult or pediatric emergency department setting. The evidence also suggests that ibuprofen is a better choice than acetaminophen for pediatric migraine. The high placebo rate noted in RCTs suggested that no treatment or just supportive treatment (e.g., intravenous fluids) may sometimes be an appropriate path to follow.

The results also underscore the need for practice management guidelines to ensure consistency of diagnosis and treatment of pediatric migraines in the acute setting, as well as to highlight the need for more RCTs to assess the safety, tolerability, and efficacy of medications such as dopamine antagonists for migraines in children. ■

## Prevalence of LCMV in Kids May Be Higher Than Expected

BY DOUG BRUNK  
San Diego Bureau

TUCSON, ARIZ. — Although only 49 cases of lymphocytic choriomeningitis virus have been reported in the medical literature worldwide, Dr. Marilyn Baird Mets has a hunch that the prevalence could be much higher.

Since 1997, she has seen seven children with the condition present to Children’s Memorial Hospital, Chicago, where she is head of ophthalmology. Subsequently, three other clinicians have called her with reports of positive cases: one from the western suburbs of Chicago, one from Los Angeles, and one from Fort Collins, Colo.

“This virus is out there,” Dr. Mets said at the annual meeting of the Teratology Society. “Obstetricians should be telling their patients not to work around rats in medical labs during their pregnancy [and] not to get a hamster for their 4-year-old if they’re going to have other children. It’s a

preventable disease, but people need to know about it.”

Discovered in 1933 and classified in the 1960s as a prototype for the arena virus, lymphocytic choriomeningitis virus (LCMV) is harbored in mice and transferred vertically by uterine infection. “There is documented infection to humans from wild mice, lab mice, rats, and hamsters,” said Dr. Mets, also professor of ophthalmology and surgery at Northwestern University, Chicago. “Transmission is thought to be airborne or contamination of food by infected mouse urine. There has also been experimental transmission demonstrated by ticks, fleas, mosquitos, and bedbugs.”

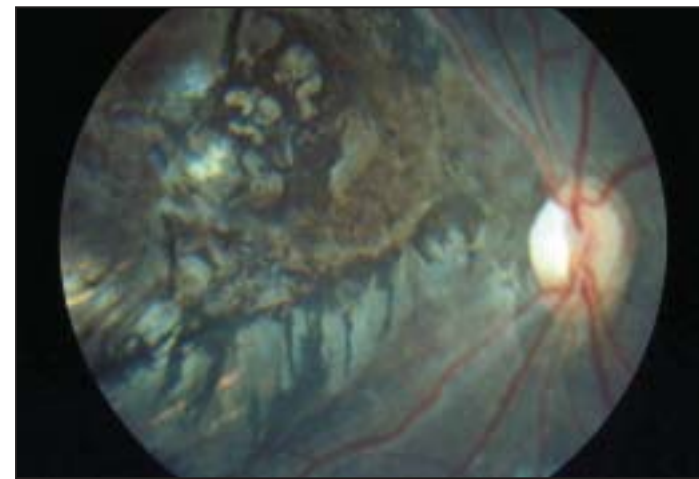
About one-third of adults who acquire LCMV are asymptomatic. Of the remaining two-thirds, about half have central nervous system disease. Illness occurs in a biphasic pattern. “First there’s an acute febrile illness with myalgias and headache,” she said. “Later on, meningeal signs may develop, and rarely encephali-

tis, myocarditis, parotitis, orchitis, and pneumonia. Very rarely, fatal systemic disease is reported.”

It’s the causative agent in about 10% of aseptic meningitis cases.

LCMV was first described as a fetal pathogen in Great Britain in 1955. The first case of congenital LCMV in the United States was reported in 1993. The baby was born with a birth weight of 2,898 grams. During pregnancy the mother lived in a well-maintained inner-city apartment. At 5 months’ gestation, she had a febrile illness that lasted a week. The child was born with hydrocephalus and microphthalmos of the right eye. The right eye had leukocoria, a cloudy vitreous, and exudative retinitis.

A review of 26 infants with LCMV published in 1997 revealed that 88% had chorioretinopathy, 45% had hydro-



Optical scan shows right eye of a 22-month-old child with congenital LCMV who was referred for marked visual delay.

cephalus, and 13% had microcephaly.

Diagnosis is made by IgG indirect fluorescent antibody, which is commercially available. “Or you can get an IgG ELISA at the [Centers for Disease Control and Prevention],” Dr. Mets said. “Complement fixation testing lacks the sensitivity” of the other two tests.

The differential diagnosis includes toxoplasmosis, rubella, cytomegalovirus, herpes simplex virus, enteroviruses, syphilis, parvovirus B19, and West Nile virus. ■



**There is documented human infection ‘from wild mice, lab mice, rats, and hamsters.’**

DR. METS