

# MR Perfusion Imaging Bests SPECT in Large Study

BY BRUCE JANCIN  
Denver Bureau

STOCKHOLM — Magnetic resonance perfusion imaging proved markedly superior to single-photon emission computed tomography for the detection of coronary artery disease in the largest comparative trial to date, Juerg Schwitter, M.D., reported at the annual congress of the European Society of Cardiology.

Results of the Magnetic Resonance Imaging for Myocardial Perfusion Assessment in Coronary Artery Disease Trial (MR-IMPACT) prompted speculation that single-photon emission computed tomography (SPECT) will gradually fade from the cardiac diagnostic imaging scene.

MR-IMPACT involved 241 patients with known or suspected coronary artery disease (CAD) studied by both MR first-pass perfusion imaging and SPECT at 5 U.S. and 13 European medical centers. All participants also underwent quantitative coronary angiography as the standard of comparison. The MR and SPECT data were



interpreted by three blinded reviewers each, with scoring of 16 segments per heart, explained Dr. Schwitter of the University of Zurich.

MR displayed 91% sensitivity and 67% specificity for detection of patients with single-, double-, or triple-vessel CAD, compared with 74% and 57%, respectively, for SPECT. For double- or triple-vessel disease, MR had 90% sensitivity and 67% specificity, while SPECT showed 76% sensitivity and 57% specificity. Thus, while MR missed 1 in

**Improved CAD diagnostics are needed if physicians are going to reduce the rate of fatal MI.**

DR. SCHWITTER

10 cases of CAD, SPECT missed 1 in 4. Artifacts made a diagnosis impossible in 5% of the MR studies. The MR perfusion technique employed a contrast agent called Omniscan (gadodiamide). Omniscan has been on the U.S. market since the mid-1990s for central nervous system MR and is at present under review by the Food and Drug Administration and European authorities for a proposed cardiac MR indication.

The cardiac MR perfusion technique was safe. It was associated with only a single adverse event, a case of angina that rapidly re-

solved, according to Dr. Schwitter.

The cardiologist said physicians too often adopt a reactive strategy to heart disease, waiting to act until after symptoms announce its presence. He sees MR perfusion imaging as occupying a key role in a more proactive management strategy that detects CAD in its early stages.

"The 2004 statistics indicate that in the United States about 60% of cardiac deaths occur before patients reach the hospital, or the death occurs in the emergency department before patients reach the catheterization laboratory for percutaneous intervention. So I think there is a strong need to improve diagnostics for the detection of coronary artery disease if we want to significantly reduce the rate of fatal MI," he argued.

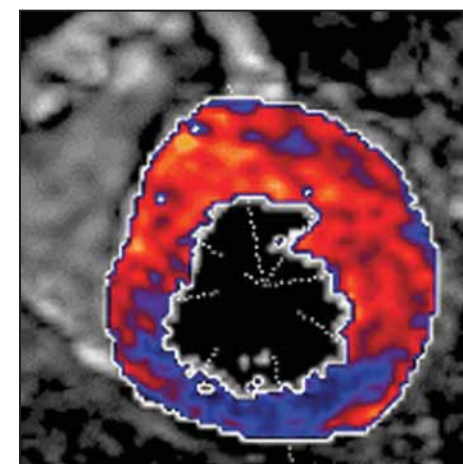
SPECT is not a patient-friendly technique. The test entails a substantial radiation exposure, takes about 4 hours, and requires two trips to the nuclear medicine facility. In contrast, MR first-pass perfusion imaging is fast and radiation free. But it requires a relatively healthy patient. For example, it can't be done in patients with a pacemaker, added Dr. Sechtem, a cardiologist at Robert Bosch Hospital, Stuttgart, Germany.

He predicted the multibillion-dollar-per-year perfusion imaging business will witness a gradual shift from SPECT to cardiac

MR in response to MR-IMPACT and other studies. But it won't happen overnight.

"SPECT is definitely not a technique to do away with immediately. It is supported by a large body of evidence showing that it's clearly applicable, very robust, valid, and it includes a lot of prognostic data," Dr. Sechtem observed.

MR-IMPACT was sponsored by GE Healthcare, which markets Omniscan. To demonstrate the perfusion technique's versatility, the study also included MR scanners made by all of the major manufacturers. ■



MR image showing reduced blood supply to the heart muscle (blue area).

COURTESY DR. JUERG SCHWITTER

## Nuclear Cardiology Promises Greater Accuracy, Better Images

BY ROBERT FINN  
San Francisco Bureau

SAN FRANCISCO — The near future of nuclear cardiology will be a bright one, with several important developments expected within the next 3 years, Manuel D. Cerqueira, M.D., said at a cardiovascular imaging conference sponsored by the American College of Cardiology.

New technology and improvements to current technology will lead to more information and greater efficiencies, said Dr. Cerqueira of the Cleveland Clinic.

He highlighted a number of advances: ▶ Attenuation from the breast and diaphragm and scatter from the liver and gut are big problems, especially in women and obese patients. Scanners with combined single-photon emission computed tomography (SPECT) and CT are beginning to address these issues.

A combined, six-slice, SPECT/CT provides high-quality SPECT images with attenuation, scatter, and resolution correction. It also provides calcium scoring and CT coronary angiography.

But these scanners are expensive, quite large, and require shielding. "We had to basically take two imaging rooms and combine them to put this system in place," Dr. Cerqueira said, adding that new, smaller systems will soon become available.

▶ PET scanners and combined PET/CT scanners will also make important contributions to cardiology. PET has much higher spatial resolution than SPECT, about 4-

5 mm, vs. 16 mm. Attenuation correction can be quite accurate with these systems, and they can be used to make precise measurements of absolute myocardial blood flow and coronary flow reserve. This is important in the context of balanced disease, which is otherwise difficult to diagnose.

▶ Single acquisition rest/stress testing using two isotopes may soon become a reality. Dr. Cerqueira envisions a protocol involving an initial infusion of 4.5 mCi of thallium-201, followed 30 minutes later by a stress test. At the conclusion of the stress test would be an infusion of 9.0 mCi of technetium-99m, followed 30 minutes later by the acquisition of a rest image.

▶ Just a stress study, with no accompanying rest study, could be used to improve efficiency in certain patients. The best candidates would be patients judged to be of low risk on the basis of risk factors, calcium scoring, or biomarkers. If the stress study is normal, they wouldn't need a rest study, but if the stress study is abnormal, management decisions could be made on the basis of that study alone, or a rest study could be ordered.

▶ New systems to image vulnerable plaques may soon become a reality. Several constituents of vulnerable plaques provide inviting targets for radiotracers. These include LDL cholesterol, oxidized LDL cholesterol, HDL cholesterol, membrane components of macrophages such as metalloproteinases, G-protein signaling or tyrosine kinase from smooth muscle cells, and clotting components. ■

## Echo Beats Nuclear Stress Test in Some Women at Risk for CAD

BOSTON — Contrast stress echocardiography is significantly more specific and no less sensitive than nuclear stress testing for evaluating chest pain in women who have a low to medium probability of coronary disease, a study has shown.

The findings suggest the ultrasound technique should be the preferred diagnostic test in this population, particularly because nuclear stress testing in women is complicated by a higher false positive rate than in men, Kenneth Ford, M.D., reported in a poster presentation at the annual meeting of the American Society of Echocardiography.

In comparing the accuracy of the two imaging modalities, Dr. Ford and his colleagues at Western Baptist Hospital in Paducah, Ky., enrolled 250 women with chest pain who were considered to be at low to intermediate risk for coronary artery disease (CAD). Women's average age was 53 years, and the average follow-up time was 543 days. Coronary disease risk-prediction factors included hypertension, diabetes, smoking, vascular disease, and family history.

Each woman underwent gated single-photon emission computed tomography (SPECT) with attenuation correction and contrast echocardiography, both at rest and immediately after a standard treadmill test, and each was injected with a weight-adjusted dose of sestamibi at peak stress followed by a 0.5-cc bolus of echo contrast. A single radiologist who was blinded to the stress echo results read all of the nuclear images.

"Patients with a reversible nuclear perfusion defect or a stress-induced wall motion abnormality on echocardiogram were urged to undergo a cardiac catheterization," Dr. Ford noted.

Of the 250 women, 16 had significant CAD defined as more than 60% stenosis in the "culprit" vessel prompting major cardiac events during the study follow-up period, said Dr. Ford.

Major cardiac events included the need for percutaneous coronary intervention (PCI) or coronary artery bypass graft surgery (CABG), myocardial infarction (MI), and death. Of the 16 patients with significant disease, 13 underwent PCI, 2 required CABG, and 1 suffered MI.

The sestamibi test correctly identified 8 of the 16 true positive conditions; the ultrasound test correctly identified 12 of them. Because of the small numbers, the difference in the sensitivity rates was not statistically significant, said Dr. Ford.

The difference between the specificity achieved by each of the diagnostic imaging techniques was significant, Dr. Ford said. Among the 234 women without significant coronary disease, the sestamibi tests produced 15 false positives, for a specificity of 94%, compared with 2 false positives—specificity of 99%—from the ultrasound images.

The lower false positive rate of stress echo tests results in fewer unnecessary heart catheterizations in younger women with intermediate to low risk for heart disease, Dr. Ford noted.

—Diana Mahoney