

## Bigger Fibroids, Better Outcomes

Ultrasound from page 1

beam and we can see exactly where the target is, and the MR also monitors the temperature within the fibroid. We also can monitor normal tissue to make sure it isn't damaged."

The availability of 3-D scanning allows the radiologist to make sure no bowel lies between the transducer and the target tissue. Later, results of the procedure are checked by injecting a contrast agent that is not absorbed by dead tissue, which shows up as a black spot on the radiograph.

A total of 149 patients were treated at five centers, including Johns Hopkins Hospital, Baltimore; the Mayo Clinic; the Lahey Clin-

ic in Boston; and Radnet Management in Beverly Hills, Calif. Of these, 105 were treated under the initial guidelines, and 44 were treated under the expanded guidelines. The mean age in both cohorts was about 45 years and 90% of the women were white. Symptom improvement was based on the Uterine Fibroid Quality of Life Questionnaire. A healthy person without fibroid symptoms would score about 22 on the document, which ranges from 1 to 100, Dr. Fennessy explained.

"Patients we evaluated for this trial had a mean baseline score of 62. At 3, 6, and 12 months, symptoms were reduced by

nearly half, falling to 35 at 3 months and to 33 at 6 and 12 months," she said, adding that the percentage of patients with significant improvement went from 76% under the initial protocol to 86% in the expanded protocol.

"We also found that the greater the fibroid volume treated, the better the outcome. The goal is not to get rid of the fibroid altogether, but rather to kill the tissue in the center of the lesion so that it can collapse in on itself. And we found no difference in outcome whether we treated a single fibroid or multiple fibroids. Time was the limiting factor; we treated as many

### Percentage of Patients Showing Significant Improvement in Symptoms

	Initial Guidelines (n = 105)	Expanded Guidelines (n = 44)
3 months	76.5%	86.4%
6 months	76.5%	85.7%
12 months	75.8%	85.7%

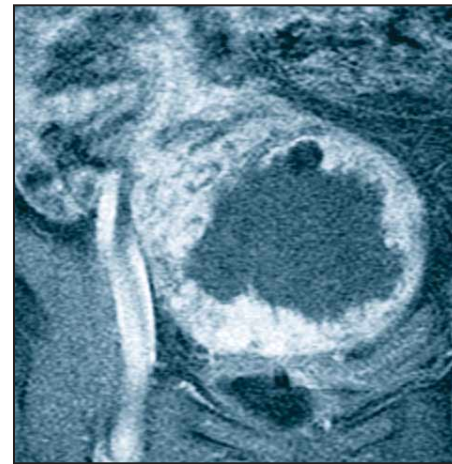
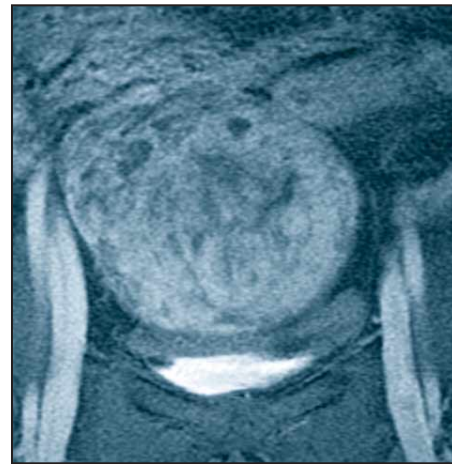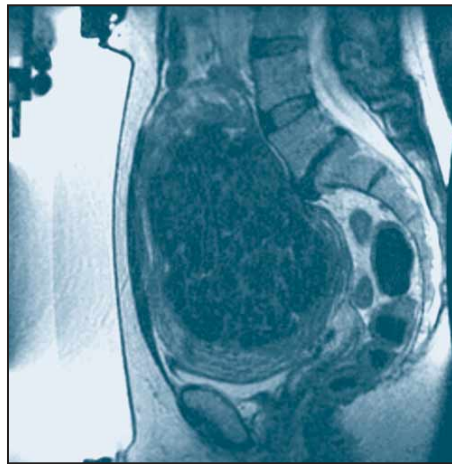
Source: Dr. Fennessy

as we possibly could within the 3-hour time period allowed by the FDA when we did the study," Dr. Fennessy said.

Now that the system—the ExAblate 2000 (InSightec Inc.)—is available commercially, longer treatment periods are possible, she said. The only adverse events the researchers encountered were position-related discomfort and sonication-related pain, which disappeared immediately after treatment stopped.

Patients may still choose myomectomy, which removes the problem completely, but MRgFUS is an option for those who prefer a less invasive treatment, she said.

Though the desire for future pregnancy was exclusionary in this trial, a handful of patients who underwent MRgFUS have since become pregnant. "At the Brigham and Women's Hospital, two of our treated patients had full-term deliveries without problems, and throughout the world, there have been additional babies delivered to women who have undergone this procedure," Dr. Fennessy said. ■



PHOTOS COURTESY DR. FIONA M. FENNESSY

High-intensity ultrasound waves heat and kill fibroid tissue as the patient lies with her uterus over a transducer inside the MRI table (as shown far left). Uterine fibroids are shown before (middle) and after (right) MR-guided ultrasound treatment.

## Adenomyosis Responds to Uterine Artery Embolization, MRI Confirmation Is Key

BY JANE SALODOF  
MACNEIL  
Southwest Bureau

NICE, FRANCE — Uterine artery embolization should not be withheld from women with adenomyosis, according to investigators who conducted a prospective, multicenter study in 42 symptomatic patients.

At a median clinical follow-up of 17 months, 37 women had avoided hysterectomy, Dr. Paul N.M. Lohle reported at the annual meeting of the Cardiovascular and Interventional Radiological Society of Europe.

Pain, bleeding, and mass-related symptoms were improved or resolved in nearly all patients, said Dr. Lohle of St. Elisabeth Hospital in Tilburg, the Netherlands.

Magnetic resonance imaging attested to the effectiveness of embolization in these patients at a median of 12 months. The data presented included median decreases of 45% for uterine volume, 72% for fibroid volume, and 23% for adenomyosis junctional zone thickness.

Investigators claimed a technical success rate of 100% for all 42 bilateral embolizations.

Speaking on behalf of collab-

orators at St. Elisabeth Hospital and at Charité University Hospital in Berlin, Dr. Lohle said they conducted the study because they were not convinced by reports of poor clinical outcomes from embolization in the presence of adenomyosis.

Among possible explanations for poor experiences, Dr. Lohle said, is the fact that magnetic resonance imaging is not always used to diagnose adenomyosis, nor are contrast MRIs always used to check the infarction rate. In addition, he said many clinics use polyvinyl alcohol particles instead of microspheres.

For their study, Dr. Lohle and his collaborators used 500- to 700- $\mu$ m, calibrated trisacryl gelatine microspheres. They set the angiographic embolization end point as complete stasis in the ascending distal part of the uterine artery.

The investigators were able to detect adenomyosis infarctions in 10 women. Dr. Lohle reported the median infarction rate as 100% and the average as 76.5% with a range of 10%-100%.

The trial enrolled consecutive patients from January 1998 to November 2004. All the women, median age 46 years, were premenopausal. Symptoms included

menorrhagia in 41 women, pain in 36, and mass effects in 17.

Seventeen women had adenomyosis without fibroids. For this group, the investigators reported three hysterectomies and one surgical resection subsequent to the embolization procedure. Bleeding was improved in 12 of 13 women with that symptom. Pain and mass effects were improved in all women with those symptoms.

Adenomyosis was the dominant disorder in a second group of 16 women, who also suffered from fibroids. Despite improvements in bleeding and pain, two women subsequently underwent hysterectomy. Among the remaining women, pain and mass symptoms were resolved and bleeding improved or resolved for all the women with those complaints.

No hysterectomies were reported in a third group of nine women with adenomyosis for whom fibroids were the dominant disorder. Pain was resolved in seven of eight patients. Otherwise, mass-related symptoms were completely resolved, and bleeding improved or resolved in all women where they occurred.

Dr. Lohle reported that 34 of the 42 women were satisfied with their procedure's outcomes. ■

## Embolization Radiation Exposure Safely Minimized

BY JANE SALODOF  
MACNEIL  
Southwest Bureau

NICE, FRANCE — German investigators significantly reduced radiation exposures without causing complications in 64 women undergoing uterine fibroid embolization.

Bilateral embolization was possible in 63 patients, Dr. Dierk Vorwerk reported at the annual meeting of the Cardiovascular and Interventional Radiological Society of Europe.

Embolization failed in a single uterine artery in just one woman.

No "specific complications" were found, according to Dr. Vorwerk of the Klinikum Ingolstadt (Germany).

"Strict adherence to simple radiation protection rules decreases dose area product significantly. Dose reduction per image significantly decreases dose but does not increase fluoroscopy time," he said.

From January 2004 through June 2005, he and his colleagues treated 64 patients 32-48 years of age with a unilateral, subradical embolization approach.

In the first consecutive group

(group A) of 26 patients, Dr. Vorwerk used pulsed radiation at 7.5 images per second and digital subtraction angiography (DSA). Radiation doses were reduced by 1.2  $\mu$ Gy per image for group A; the protocol included collimation. Besides DSA runs before and after embolization on each side, aortography was done as the final run.

For a second group of 29 patients, the protocol was revised to a dose of 1.2  $\mu$ Gy per image and maximum collimation with a 40-cm intensifier. DSA runs were only done before catheter placement for group B. There was no aortography.

For the final group of nine patients, the dose was further reduced by 0.48  $\mu$ Gy per image. The investigators also avoided oblique runs.

The physicians maintained average fluoroscopy time at 20.2 minutes, 21.3 minutes, and 19.8 minutes. Area dose product declined significantly from 52.7 Gy  $\text{cm}^2$  (A) to 20.9 Gy  $\text{cm}^2$  (B) to 12.2 Gy  $\text{cm}^2$  (C).

Published studies cited by Dr. Vorwerk had reported mean fluoroscopy times of 11.8 and 22.5 minutes and average dose area product of 59.5 Gy  $\text{cm}^2$  and 85.47 Gy  $\text{cm}^2$ . ■