

# MRI Reveals Missed Cancerous Breast Lesions

BY BRUCE K. DIXON  
Chicago Bureau

CHICAGO — Magnetic resonance imaging done prior to treatment for breast cancer can reveal cancer missed by mammography and ultrasonography, yielding more accurate information about the extent of disease, according to a poster presented at the annual meeting of the Radiological Society of North America.

"We found almost 29% more cancer by doing the magnetic resonance imaging before surgery or radiation therapy than we thought we had diagnosed with standard mammography, ultrasound,



**'We found almost 29% more cancer by doing the magnetic resonance imaging.'**

DR. NEWSTEAD

and clinical examination," said Dr. Gillian Newstead of the University of Chicago in an interview. Identifying more cancer up front will influence the course of treatment and ideally produce a more positive long-term outcome, she said.

The researchers classified newly diagnosed breast cancers in 140 women (mean age 56.5 years), of which 53.5% were invasive ductal carcinoma (IDC) with extensive intraductal component (EIC). Additional lesions identified by MRI in 40 women included 26 in the same quadrant, 11 in a different quadrant, and 3 in the contralateral breast. Specifically, 23 of the lesions were identified as IDC with EIC, 6

as IDC, 6 as ductal carcinoma in situ, and 5 as invasive lobular cancer. Clinical management was changed in 31 of the 40 women: 20 underwent more extensive surgery, 8 were converted from breast conservation to mastectomy, and 3 were given additional neoadjuvant chemotherapy.

Although mammography and ultrasonography are still the primary imaging methods for breast cancer screening and diagnosis, the higher soft tissue contrast and gadolinium-enhanced images obtained by MRI improve the sensitivity of detection and allow more accurate evaluation of the cancer. Most breast cancers enhance rapidly after IV injection of contrast agents because of higher vascularity and the angiogenic factors that produce an increase in capillary permeability.

"The MR is looking at the new blood vessel growth, or angiogenesis, in tumors and it's a functional test in that sense, so we see lesions that may not show up on mammograms, especially in dense breasts. And there are some tumors that grow in such a way that makes them more difficult to perceive on a mammogram," she added.

"Patients underwent imaging in the prone position with the breasts gently immobilized within lateral compression plates. Contrast injection was made with IV administration of 0.1 mmol/kg gadodi-

amide followed by a 20-mL saline flush at the rate of 2.0 mL per second. MR images were acquired using a 1.5-T scanner with use of a dedicated breast coil," the investigators said. The resolution on the MRI machine was 1.6 mm.

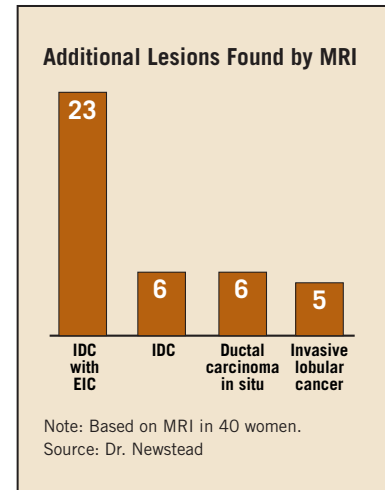
Hospitals have been slow to assimilate MRI into clinical practice because there have been a lot of different techniques proposed by academic centers, Dr. Newstead said. "That's becoming less of an issue as our magnets are getting faster and we don't have to make as many compromises; so I would say that any person with a fairly modern magnet and a modern breast coil should be able to achieve satisfactory resolution both spatially and temporally," she said.

MRI has found a home at the University of Chicago's breast imaging section, not only for pretreatment assessment but also to detect cancer recurrence post treatment and to screen high-risk women. "Early detection of local recurrence improves long-term survival, but postoperative mammographic and ultrasound evaluation often is limited, especially in patients with dense, fibroglandular tissue and postsurgical or postradiation fibrosis," the authors wrote, noting that recur-

rent tumor exhibits early enhancement.

"MR is a sensitive modality for detection of early recurrent tumor, and breast cancer recurrence must be differentiated from acute and subacute posttreatment changes. Most recurrent tumor, unlike unrecognized residual tumor, usually presents at least 2 years following breast conservation treatment. Normal parenchymal enhancement usually is diminished after breast irradiation. Recurrent tumor may therefore be readily visible in the postirradiation breast," they said.

False-positive findings are not a problem with high-resolution MRI and correct procedure, Dr. Newstead said. "When we find something on MR that wasn't seen before on mammography or ultrasound, typically we'll bring the patient back for a repeat ultrasound and mammogram. If we see something, we'll do a biopsy right then. But if we can't find anything [with conventional imaging]—which happens in about 40% of our cases—and MR is the only finding, then we'll bring the patient back and repeat the MRI study. If it still looks worrisome, we'll go ahead and biopsy at the same time, so she only has to come back once," Dr. Newstead explained. ■



## Carefully Communicate Location of Palpable Breast Lumps to Radiologists

BY SHERRY BOSCHERT  
San Francisco Bureau

KAILUA KONA, HAWAII — Inform the radiologist about the specific location of any palpable mass in a patient's breast that prompted you to order a mammogram, Dr. R. James Brenner said at a meeting on medical negligence and risk management.

Avoid vague descriptions like "a general fullness in the breast upper right quadrant" and be more specific—"a palpable lump at 10 o'clock," said Dr. Brenner, chief of breast imaging at the University of California, San Francisco.

If the radiologist doesn't know there's a palpable mass, the patient gets a screening mammography. But mention a palpable mass, preferably with a specific area for interrogation, and the radiologist can perform ultrasound and potentially detect carcinomas that can't be seen by mammography.

"I need to know from the gynecologist that he or she feels something there. Otherwise, this ultrasound is not performed, and the

diagnosis is not made in a timely fashion," he said. "This is an example where the clinician and the radiographic team either sink or swim together."

American College of Radiology guidelines state that ultrasound examinations should be performed for mammographic masses or palpable masses that are insufficiently characterized on mammographic findings. Using ultrasonography for screening is not the standard of care, but is being investigated in a National Cancer Institute trial.

The most common reason for medical malpractice lawsuits is a delay in the diagnosis of breast cancer, according to data from the Physicians Insurance Association of America. The top two defendants are radiologists and ob.gyns. A large percentage of the litigation involves a palpable breast mass discovered by the patient, who then comes to the clinician for an evaluation. Litigated cases often lack documentation of a breast examination.

Clinicians should carefully document that they evaluated a patient for signs and symptoms of breast

cancer, took a thorough clinical history, and referred the patient for genetic counseling if appropriate. Use a stamp or mnemonic in the chart to show that you examined the breasts and regional lymph nodes, Dr. Brenner suggested.

Try to reconcile clinical findings and imaging results. "The interplay between the clinical and mammographic findings often convert subthreshold findings to threshold findings. That needs to be appreciated," he said at the meeting, sponsored by Boston University.

Insist on getting a phone call from the radiologist if there is any suspicious finding on mammography or ultrasound, because written or electronic reports can get lost or misplaced, he added.

When you do get a mammography or ultrasound report, initial it to indicate that you looked at it, and to show a potential jury that it was your decision to do something further or not to do more, Kimberly D. Baker, J.D., said in a legal commentary session after Dr. Brenner's talk. ■

## Older Women Have a Lot Of Faith in Mammography

ORLANDO — Older women with a family history of breast cancer place extraordinary faith in mammography over clinical breast exam for reassurance about their breast health, according to Karen Greco, R.N., Ph.D., lead investigator of a small, qualitative study on mammography decision making.

Furthermore, many of these women may not appreciate their potentially increased risk for hereditary cancer syndromes, added Dr. Greco, who presented her study as a poster at the annual meeting of the Gerontological Society of America.

"The women in my study were not aware that if they had a first-degree relative with breast cancer and another one with ovarian cancer, that there was a connection," she said in an interview. "Although some had been asked about family history they didn't understand what it meant, and

they didn't understand the significance."

Ten of the 16 women in her study had family histories that suggested they could be at risk for a hereditary cancer syndrome, yet they reported they had not received a cancer risk assessment, said Dr. Greco of the Oregon Health & Science University School of Nursing in West Linn.

The study included 16 women over age 65 years (average age 73) who were at increased risk for breast cancer because of family history—at least one first-degree relative diagnosed with breast cancer—and advancing age. The women were interviewed regarding their decisions about screening mammography.

Although 15 of the 16 women had regular visits with their health care provider, and 14 had regular mammograms, less than half (7) said they received regular clinical breast exams, Dr. Greco said.

—Kate Johnson