

Light-Based Therapy Prevents Radiation Dermatitis

LED photomodulation helps avoid skin reactions, treatment interruptions in breast cancer patients.

BY DIANA MAHONEY
New England Bureau

BOSTON — A light-based therapy commonly used in cosmetic dermatology minimizes the occurrence and symptom intensity of radiation-induced dermatitis in breast cancer patients undergoing radiation treatment, according to the results of a recent investigation. The preventive therapy not only minimizes patient discomfort, but also prevents treatment interruptions necessitated by severe skin reactions, said Dr. M. Maitland DeLand at the annual meeting of the American Society for Laser Medicine and Surgery.

Postradiation dermatitis can include reactions ranging from mild to moderate dryness and peeling to significant erythema, hyperemia, and moist desquamation

with loss of epidermal barrier, said Dr. DeLand, a radiation oncologist in Lafayette, La. The investigators hypothesized that targeting these areas with pulses of non-thermal low-energy light via arrays of light-emitting diodes (LED) would interrupt the postradiation inflammatory process and stimulate collagen synthesis, and by so doing strengthen the skin's defenses, she said.

In the pilot study, 18 of 19 women who received LED photomodulation therapy following radiotherapy for breast cancer experienced little to no radiation dermatitis, whereas all 28 matched controls who did not receive the light therapy experienced some degree of skin reaction, reported Dr. DeLand.

The women in the study were 35-80 years old. Prior to radiation therapy, all had undergone single lymph node sam-

pling or axillary dissection; some had chemotherapy. The women in the photomodulation group received the LED treatment immediately following their daily radiation therapy, and were allowed to use a neutral pH ointment for dry skin after each session. The women in the control group followed the same radiation therapy protocol without the LED follow-up, and were also allowed to use the ointment.

Of the 19 women in the treatment group, 7 had no skin reactions, 11 had grade 1 reactions, and 1 patient had a grade 2 reaction. In contrast, 4 of the control patients had grade 1 reactions, 18 had grade 2 reactions, and 6 had grade 3 reactions. In the control group, the skin reactions—specifically, severe erythema and moist desquamation—led to treatment interruptions in 19 patients.

"Only one patient in the [treatment group] had a reaction severe enough to interrupt therapy," Dr. DeLand said. "This is an important finding, because the effi-

cacy of radiation therapy is based on a dose/time relationship. You really want to avoid treatment disruptions" to achieve the best biologic response, she said.

The LED therapy also appeared to provide long-lasting skin benefits. At 3 and 6 months post therapy, the skin texture and pigment of irradiated areas in the women in the treatment group were "excellent," the breast tissue was smooth and supple, and the surgical scars were "barely visible," Dr. DeLand said. In contrast, the women in the control group showed typical signs of late radiation effects, including some atrophy and pigmentary changes and, in some cases, radiation-induced fibrosis, edema, and dermal thickening, she said.

Because LED therapy is "quick, painless, and effective," the treatment option should be made available to all women undergoing breast irradiation, Dr. DeLand concluded.

She reported receiving free use of the device for the investigation but has no financial interest in the manufacturer. ■

Duac Gel Advantageous in Acne; Prevents Drying Seen in BP Alone

BY BRUCE JANCIN
Denver Bureau

KOHOA, HAWAII — Duac, a clindamycin 1%/benzoyl peroxide 5% topical gel containing moisturizers and humectants, offers several advantages for topical acne therapy, Dr. Leon H. Kircik said at the annual



Given the lesser efficacy of single agents, 'why use monotherapy unless the patient is allergic to benzoyl peroxide?'

DR. KIRCIK

Hawaii dermatology seminar sponsored by the Skin Disease Education Foundation.

In this era of growing concern about the emergence of antibiotic resistance, long-term monotherapy with a topical antibiotic is difficult to justify, particularly when there is convincing evidence that adding benzoyl peroxide (BP) greatly reduces the resistance problem. Moreover, the antibiotic/BP combination acts synergistically and addresses more of the multiple underlying pathologic processes of acne than either agent alone, noted Dr. Kircik, a dermatologist in private practice in Louisville, Ky.

"Neither topical erythromycin nor clindamycin alone has as much efficacy as benzoyl peroxide, so why use

monotherapy unless the patient is allergic to benzoyl peroxide?" he asked.

BP's downside is that it's inherently drying, which impairs skin barrier function and reduces tolerability. Duac counteracts this by containing dimethicone as an occlusive agent to trap water in the skin as well as glycerin as a humectant to draw water to the stratum corneum from deeper layers.

Dr. Kircik mentioned the results of a 12-week, double-blind, randomized clinical trial presented by Dr. Emil Tanghetti of the University of California, Davis, at last year's annual meeting of the American Academy of Dermatology in New Orleans. In that study, 121 adults with moderate-to-severe acne received Duac and tazarotene 0.1% cream once daily or tazarotene cream alone.

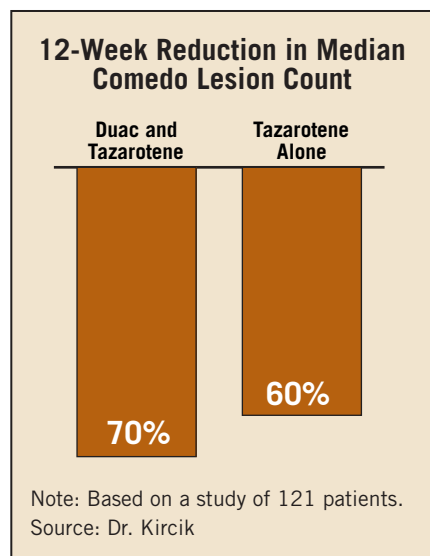
The median comedo lesion count dropped by 70% at 12 weeks in the combined treatment group, significantly better than the 60% decline in the retinoid monotherapy arm. Papules and pustules declined by 63% with combined treatment, compared with 58%

with tazarotene alone. Most impressive of all, Dr. Kircik continued, was the significantly lower incidence of peeling in the combination therapy group at week 4, a time when many patients in clinical practice opt to stop taking their retinoid because of side effects.

Another study led by Dr. Tanghetti involved a head-to-head comparison of Duac and BenzaClin, a competing clindamycin 1%/BP 5% water-based gel that doesn't contain moisturizers. A total of 73% of the 52 participants in the evaluator-blinded, split-face, crossover study rated Duac as significantly better tolerated.

Dr. Kircik is a consultant to Stiefel Laboratories Inc., which markets Duac.

The SDEF and this news organization are wholly owned subsidiaries of Elsevier. ■



Acne Treatment Shifting From Antibiotics Toward Retinoids

BY SHERRY BOSCHERT
San Francisco Bureau

SAN FRANCISCO — Prescribing has been gradually moving away from antimicrobial agents and toward increased use of retinoids in the treatment of acne vulgaris.

The shift toward nonantibiotics, reported in an analysis of national prescription habits between 1990 and 2002, may in part be explained by a growing awareness of antibiotic-resistant *Propionibacterium acnes*, wrote Dr. Suganthi Thevarajah and her associates in a poster presentation at the annual meeting of the American Academy of Dermatology.

The first report of antibiotic resistance to cutaneous *P. acnes* appeared in the late 1970s. The study showed that one in five U.S. patients treated with either topical erythromycin or clindamycin had resistant strains within their pilosebaceous follicles, noted Dr. Thevarajah of Hospital Kuala Lumpur, Malaysia. Dr. Thevarajah led the study while at the Center for Dermatology Research, Wake Forest University, Winston-Salem, N.C. The center is supported by a grant from Galderma Laboratories, which makes acne treatments.

She and her associates retrospectively analyzed data from all 4,922 acne visits from 1990 to 2002 in the National Ambulatory Medical Care Survey. The survey consists of outpatient information obtained from U.S. non-federally employed physicians.

During the 13-year period, there were significant declines in the likelihood of prescribing agents

that relied on antimicrobial mechanisms for controlling acne. Included among these were benzoyl peroxide, topical clindamycin, oral erythromycin, and tetracycline-group antibiotics. In the same time period, there were significant increases in the likelihood of prescribing agents that were not dependent on antimicrobial mechanisms, such as topical retinoids and oral isotretinoin.

"Cross-resistance between erythromycin and clindamycin is increasing. This knowledge may have resulted in a decline in prescriptions for topical antibiotics as seen in our study," Dr. Thevarajah wrote.

While use of tetracycline-group antibiotics decreased overall, their use actually increased among dermatologists. This may be because dermatologists are increasingly prescribing them for their anti-inflammatory effects rather than their antimicrobial properties, she added. Dermatologists were more likely than nondermatologists to prescribe benzoyl peroxide, clindamycin, isotretinoin, topical retinoids, and tetracycline-group antibiotics.

Controls for demographics did not change the utilization findings. Older patients were less likely to receive clindamycin, topical retinoids, benzoyl peroxide, tetracycline-group antibiotics, and isotretinoin. Men were less likely to receive clindamycin and topical retinoids and more likely to receive tetracycline-group antibiotics and oral isotretinoin. Whites were more likely than nonwhites to get isotretinoin but less likely to be given benzoyl peroxide. ■