

Virtual Colonoscopy Has Improved With Age

BY KERRI WACHTER
Senior Writer

WASHINGTON — Improvements in technology and technique are helping to overcome some of the limitations of CT colonography, and this may ultimately lead to its widespread use in screening for colorectal cancer, Dr. Jay P. Heiken said at the International Union Against Cancer Conference.

CT colonography—also known as virtual colonoscopy—allows physicians to look for abnormalities in the colon wall using either the standard two-dimensional format or a three-dimensional approach. The 3-D view allows the physician to see the colon in much the same way that an endoscopist would—navigating the colon forward or backward.

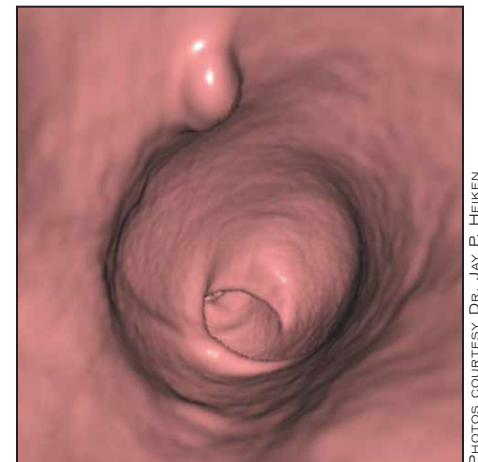
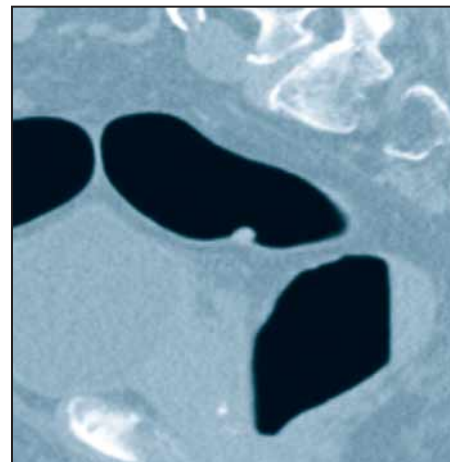
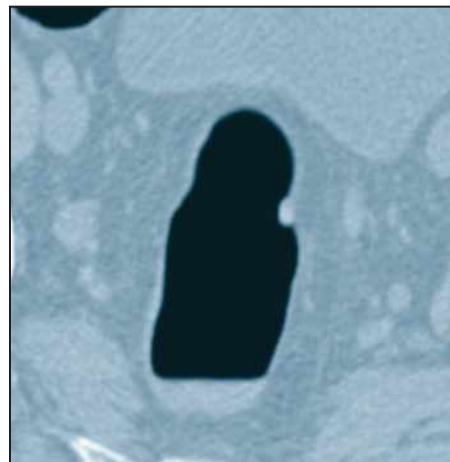
“We can produce images that look just like an endoscopic examination of the colon,” said Dr. Heiken, a professor of radiology at the Mallinckrodt Institute of Radiology at Washington University, St. Louis. “Much of the excitement about this technique revolves around its advantages relative to optical colonoscopy.”

These advantages include the following benefits:

- ▶ A noninvasive technique that requires no sedation.
- ▶ Rapid image acquisition.
- ▶ Accurate localization of lesions.
- ▶ The elimination of blind spots.
- ▶ Extracolonic findings.

The technique is not without disadvantages, however. The first problem is the radiation dose. “I think this really is not a significant problem,” Dr. Heiken said. A number of studies have shown that CT colonography can be performed with a radiation dose substantially lower than that of an air contrast barium enema.

With virtual colonoscopy, it can be difficult to distinguish polyps from residual stool. Stool tagging is a technique that can be used to overcome this obstacle. Small amounts of barium are administered orally the day before the examination. The barium is ingested during the bowel cleansing process and is incorporated into any residual stool in the colon. Residual stool tagged in this way has a very high



Transaxial and sagittal views (left and middle) are shown of a rectosigmoid junction polyp imaged by a conventional CT scanner. A corresponding 3-D endoluminal view is shown of the same polyp (right).

density in a two-dimensional image, which clearly differentiates it from a polyp.

A similar technique can be used to help distinguish polyps from residual fluid, which many bowel preparations can leave behind. Fluid tagging involves administering a small amount of oral iodine the night before the examination. Residual fluid will then appear high in density on a two-dimensional image.

The landmark study for virtual colonoscopy involved 1,233 asymptomatic adults who underwent virtual and optical scans on the same day (*N. Engl. J. Med.* 2003;349:2191-200). The researchers concluded that virtual colonoscopy was comparable to optical colonoscopy for the detection of clinically relevant polyps.

Two subsequent studies found much lower sensitivities for CT colonography, at about 50% (*JAMA* 2004;291:1713-9 and *Lancet* 2005;365:305-11). Neither of the studies involved screening populations, and both used somewhat outdated techniques and two-dimensional images. “We’re now using multidetector scanners that have 4, 16, or 64 detector rows,” Dr. Heiken said. This allows the examination to be performed in a much shorter time than with single-detector scanners. In addition, “our spatial resolution is much greater, so we can identify much smaller polyps.”

Moreover, readers involved in the *JAMA* study were not trained in the reading of virtual colonoscopy images. “Reader training is a critical factor,” he said. All of these as-

pects help account for the low sensitivities.

Importantly, results should be available in 2007 from the U.S. CT Colonography Screening Trial involving virtual and optical colonoscopy of 2,600 asymptomatic adults with average risk for colon cancer. None of the 15 participating institutions has used less than 16-row CT, and most have been using 64-row CT. In addition, stool and fluid tagging are being utilized, and all readers have been trained. The trial is organized by the American College of Radiology Imaging Network and is funded by the National Cancer Institute.

While most of the obstacles to the widespread use of virtual colonoscopy as a screening tool appear to have been addressed, capacity—particularly adequate reader training—remains an issue. “Most of us who have experience with this believe that it takes at least 50-100 examinations to begin to develop the expertise necessary to read these [images] properly and accurately,” Dr. Heiken said. Reader training would have to be ramped up to meet the goal of widespread use.

Perhaps the most important issue is the lack of third-party payment for colorectal screening using CT colonography in the United States.

Still, some innovations on the horizon may hasten the routine use of virtual colonoscopy. The “filet” view opens the colon up electronically to allow it to be viewed like a pathology specimen. “The advantage of that is that it makes it less

likely that we’ll miss things ... around bends. It’s also a much more efficient way of looking at the colon,” Dr. Heiken said.

Computer-aided diagnosis also may soon play a part in virtual colonoscopy. Software improvements could help identify potential polyps missed on visual inspection. The final determination would still be made by the physician. “It will be very important for helping us improve our detection rate, decrease interobserver variability, and ... make our examination more efficient by [more quickly] bringing our attention to lesions that we might have missed,” he said.

Virtual colonoscopy examinations involving minimal bowel preparation might even be possible soon. “One of the big obstacles to colorectal cancer screening is that most patients do not want to have to undergo a rigorous, cathartic bowel preparation,” Dr. Heiken said. Consequently, many patients who should be screened forgo this exam. Some studies have shown that it is feasible to perform CT colonography with stool and fluid tagging but without cathartic preparation and get good results.

Greater patient discomfort associated with colon inflation during virtual colonoscopy is another potential limitation. However, discomfort most often arises from the use of room air to insufflate the colon, Dr. Heiken noted. The use of CO₂ is more comfortable for the patient and the gas is more quickly reabsorbed by the body. ■

Virtual Colonoscopy Fails to Identify Some Advanced Lesions

BY BETSY BATES
Los Angeles Bureau

LOS ANGELES — Virtual colonoscopy missed adenomatous lesions in 12% of patients, including 5% who had advanced lesions detected only on a follow-up optical colonoscopy, researchers reported at the annual Digestive Disease Week.

Investigators at the University of Wisconsin, Madison, studied records of 160 patients who first had virtual colonoscopy performed by primary 3-D read with 2-D resolution and were then sent for optical colonoscopy.

Patients had both tests if a significant portion of the colon was not visualized on virtual colonoscopy, if they had findings of a polyp or mass greater than 10 mm, if virtual colonoscopy detected polyps between 6 mm and 9 mm, or at the patient’s discretion. Lesions less than 6 mm that were seen on virtual colonoscopy were not reported, and patients with these lesions were not referred for optical colonoscopy.

Invasive colonoscopy detected adenomatous lesions not seen on

virtual colonoscopy in 19 of 160 patients. Eight of these patients had previously undetected advanced lesions, defined as any adenoma greater than 9 mm or a

Conventional colonoscopy detected 138 lesions, in a group of 54 patients, that had not been detected on virtual colonoscopy.

lesion less than 9 mm with villous pathology.

The second test also detected a false positive rate of 5% with virtual colonoscopy.

Conventional colonoscopy detected 138 lesions, in 54 patients, that had not been seen on virtual colonoscopy, including 99 lesions that were less than 6 mm, 27 that were between 6 mm and 9 mm, and 12 that were greater than 9 mm. Most of them were hyperplastic.

“These findings suggest that virtual colonoscopy identifies the majority of colorectal polyps with advanced pathology during routine screening examinations,” said Dr. Daniel Cornett of the section of gastroenterol-

ogy and hepatology at the University of Wisconsin, Madison.

But he added that virtual colonoscopy poses a “small risk” of missing polyps with advanced pathology, “especially smaller polyps less than 9 mm in size with villous pathology and larger adenomas that are flat in nature or resemble a mucosal fold.”

Both Dr. Cornett and coauthor Dr. Courtney Barancin, a gastroenterology fellow, expressed concern that some protocols for virtual colonoscopy do not refer for optical colonoscopy patients with lesions less than 6 mm. ■