

Noninvasive Eye Exam Identifies Neuropathy

BY JEFF EVANS
Senior Writer

WASHINGTON — Corneal confocal microscopy can noninvasively reveal neuropathy early in diabetes and help in monitoring treatment response, speakers said at the annual scientific sessions of the American Diabetes Association.

By comparison, the clinical neurologic exam may be easier than corneal confocal microscopy but lacks sensitivity. Nerve conduction studies are time-consuming and only measure the function of large nerve fibers. Quantitative sensory testing also is easier to do, but relies on patient responses. Skin nerve biopsies can provide much information, but are “highly invasive,” said Mitra Tavakoli, a doctoral student at the University of Manchester (England).

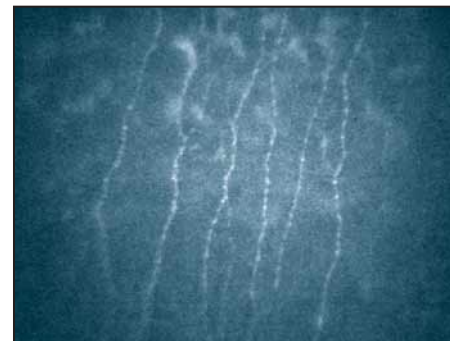
Using a first-generation corneal confocal microscope, the ConfoScan P4 (Tomey

Corp.), she and her colleagues obtain real-time micrographs of the cornea at up to 680 times magnification without directly contacting the eye. They studied 183 people including diabetics without neuropathy; diabetics with mild, moderate, or severe neuropathy; and controls without diabetes.


Diabetic neuropathy was associated with progressive, significant reductions in corneal sensitivity (as measured by non-contact corneal aesthesiometry), nerve fiber density, nerve branch density, and nerve fiber length. Nerve fiber tortuosity also became progressively worse as the severity of neuropathy worsened.

Measurements of corneal nerve morphology obtained with confocal microscopy correlated well with assessments of corneal sensitivity and neuropathy severity, using the Neuropathy Disability Score.

In a poster presented at the meeting, Ms. Tavakoli and her colleagues used corneal confocal microscopy to assess the effec-



Confocal micrographs show nerves in a control patient without neuropathy.



By comparison, nerve density is lower in a diabetic patient with neuropathy.

PHOTOS COURTESY MITRA TAVAKOLI

tiveness of pancreatic transplantation in improving neuropathy in 20 patients with type 1 diabetes (average age, 41 years).

Before transplantation, the diabetic patients had significantly reduced corneal sensitivity and significantly lower nerve fiber density, nerve branch density, and nerve fiber length on corneal confocal micrographs, compared with 18 individu-

als without neuropathy (average age, 55).

At 6 months after transplantation, repeat scans in 11 of the patients who had neuropathy showed that nerve fiber density and length had improved significantly.

In a related study, microscopy had sensitivity (71%) and specificity (77%) comparable with skin punch biopsy specimens (59% and 90%, respectively). ■

Skin Punch Biopsy May Predict, Diagnose Neuropathy Early

BY JEFF EVANS
Senior Writer

WASHINGTON — Analysis of skin punch biopsy specimens may help predict diabetic neuropathy in at-risk patients, diagnose the condition earlier, and assess treatment response, Dr. Michael Polydefkis said at the annual scientific sessions of the American Diabetes Association.

Skin punch biopsy specimens contain small unmyelinated nerve fibers that are damaged in early diabetes. Normative data have shown that the degree of involvement is related to the degree of glucose dysmetabolism, said Dr. Polydefkis, codirector of the cutaneous nerve laboratory at Johns Hopkins University, Baltimore.

Analysis of skin biopsy specimens can help exclude other potential causes of painful feet such as radiculopathy, Morton's neuroma, tarsal tunnel syndrome, and intrinsic foot disease, he said.

A 3-mm diameter, circular skin punch biopsy specimen (about half the size of a pencil eraser) is sliced into about 60 sections, 4 of which are randomly selected for analysis to reduce sample bias since there may be differences in nerve density in different parts of the specimen. Biopsies should be taken at the ankle or other distal sites in patients with early neuropathic symptoms but at the thigh or other proximal sites in those with advanced neuropathy, he said.

In a study of 73 patients with an unknown cause of peripheral neuropathy, Dr. Polydefkis and his associates found that epidermal nerve fiber density (ENFD) in skin punch biopsy specimens was a good marker of early neuropathy. Of the 73 patients, 25 were diagnosed with impaired glucose tolerance (IGT) and 16 had diabetes.

The ENFD in biopsy specimens of patients with dia-

betes or IGT was significantly reduced, compared with healthy control patients. In specimens from the distal leg but not the distal or proximal thigh, diabetic patients had significantly lower ENFD than did patients with IGT. Yet nerve conduction studies yielded normal results on average in both groups.

Dr. Polydefkis and his associates concluded that the measurement of ENFD in skin punch biopsies is a more sensitive marker for detecting neuropathy early than are nerve conduction studies that test the function of large myelinated nerve fibers (*Neurology* 2003;60:108-11).

At the end of an average follow-up of 4.4 years, repeat testing in 29 patients showed that decline in ENFD was greatest in patients with diabetes, followed by patients with IGT and patients with idiopathic neuropathy. ENFD was essentially stable in 10 healthy control patients. “This longitudinal data provide some of the best evidence that the association between IGT and neuropathy is, in fact, causal,” Dr. Polydefkis said.

Information on nerve morphology also can be extracted from skin punch biopsy specimens. In one study, investigators performed nerve conduction studies, quantitative sensory testing, and skin punch biopsies in the proximal thigh and distal leg at baseline and after a mean of 19 months of follow-up in 15 patients with foot pain but few or no symptoms of neuropathy (6 with diabetes, 1 with AIDS, 1 with paclitaxel toxicity, 7 with an idiopathic nature) and 15 age-matched, healthy control patients.

At baseline, patients had significantly lower ENFD in the distal leg than did controls. At follow-up, the ENFD had declined in both biopsy locations but only by a significant amount in the distal leg, compared with the controls (*Neurology* 2003;61:631-6).

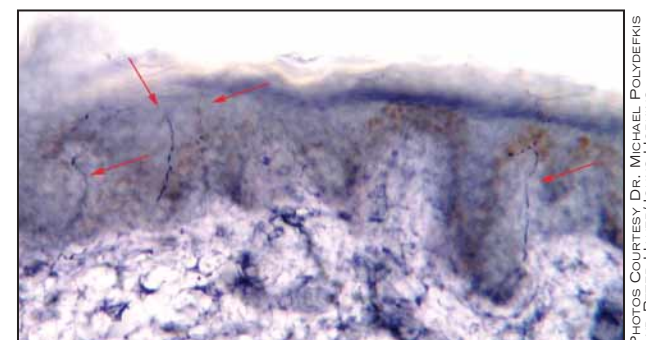
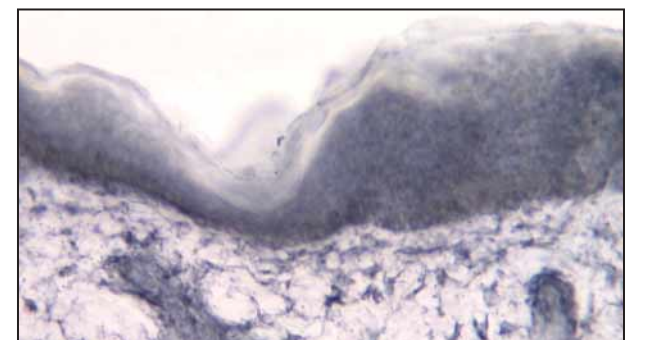
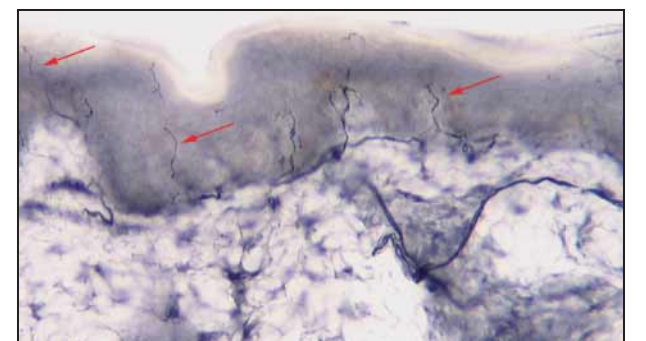
The results of that study provide “evidence that the skin biopsy can be used to predict development of neuropathy,” Dr. Polydefkis said.

Clinically meaningful changes in ENFD are on the order of a loss of 2-3 nerve fibers per millimeter. Diabetic patients who present with painful peripheral neuropathy appear to have ENFD losses in the range of 1 fiber/mm per year, while losses for those with established diabetes and peripheral neuropathy may be slightly higher, he said.

Skin punch biopsies also may help investigators to understand how nerve regeneration occurs after an injury in diabetic patients, Dr. Polydefkis said. In a study of patients who applied capsaicin topically to their distal thighs—causing denervation of the epidermis—he and his colleagues found the rate of regeneration depended in part on the patient's baseline ENFD. Diabetic patients had a signifi-


cantly lower regeneration rate than did healthy control patients even after adjustment for baseline differences; the rate was even lower among diabetic patients with neuropathy than in those without it. After 100 days, neither group of diabetic patients regenerated their ENFD to baseline levels (*Brain* 2004;127:1606-17). (See photos.)

These results suggest that an improvement in regeneration could be an early signal of effectiveness of an intervention for neuropathy, he said. ■



Skin punch biopsies from a healthy individual: normal baseline epidermal nerve fiber density (top, red arrows); complete denervation 2 days after topical capsaicin; and return of normal nerve fiber density after 29 days.

PHOTOS COURTESY DR. MICHAEL POLYDEFKIS AND PETER HAUER, JOHNS HOPKINS CUTANEOUS NERVE LABORATORY



Epidermal denervation indicates small fiber neuropathy in a newly diagnosed diabetic with foot symptoms.