

Transoral Gastroplasty Evaluated in Pilot Study

BY MITCHEL L. ZOLER
Philadelphia Bureau

BERLIN — A new device that makes transoral gastroplasty possible, thereby avoiding any incision, was safe and effective with 3 months of follow-up in a pilot study with 21 morbidly obese patients.

The transoral gastroplasty (TOGa) system uses an orally introduced endoscope to deliver vacuum and staples to create a pouch within the patient's stomach. The procedure uses "exactly the same technique as Mason's gastroplasty," Dr. Jacques Devière said at the 14th United European Gastroenterology Week.

Three months after the procedure, the first 21 patients had lost a mean of about 20% of their excess weight with no severe or long-lasting complications, said Dr. Devière, chief of the division of gastroenterology at Erasme University, Brussels.

The study was sponsored by Satiety Inc., Palo Alto, Calif., which makes the device. A larger study aimed at collecting the data for Food and Drug Administration approval is expected to start next year.

The study enrolled 9 patients in Brussels and 12 at a hospital in Mexico City. All patients had a body mass index (BMI) of more than 35 kg/m² plus at least one comorbidity, or a BMI of more than 40 kg/m². The average BMI of the enrolled patients was 43 kg/m² (range 35-53 kg/m²). The most common comorbidities were hypertension, in 48%, and diabetes, in 33%.

The procedure was done under general anesthesia. The TOGa device, 19 mm in diameter, was inserted through the patient's mouth and down the esophagus to the stomach under direct endoscopic control.

In the stomach, a vacuum pulls the anterior and posterior wall surface into position, with a septum placed between the walls to prevent cross-attachments. Two 4.5-cm staple lines are made with standard, titanium staples to create a restrictive sleeve along the lesser curve of the stomach. The stomach walls are positioned so that the staples produce a four-layer structure. After the sleeve is formed, vacuum is applied a second time and additional staples are placed at the distal end to narrow the outflow tract.

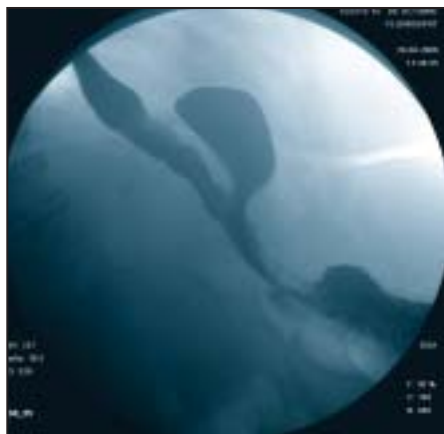
In 11 of 12 of the Mexico City patients, a concomitant laparoscopy was performed so that the procedure could be observed for potential complications, noted Dr. Steven Edmundowicz, chief of endoscopy at Washington University in St. Louis and one of the coauthors of the North American trial.

No serious adverse events occurred, Dr. Edmundowicz said at the annual meeting of the American College of Gastroenterology in Las Vegas. His report was delivered 2 days before Dr. Devière presented the combined study data in Berlin.

All patients were ready to be discharged after 24 hours, and all were discharged within 48 hours of their procedure, Dr.

Devière said at the European meeting, sponsored by the United European Gastroenterology Federation. All complications were mild and all but one resolved within 5 days. These included five patients with pain, four with nausea, four with vomiting, three with dysphagia, and one with pharyngitis. One patient had mild temporomandibular dysfunction secondary to the procedure that lasted for 10 days. It's conceivable that the procedure could be done on an outpatient basis, Dr. Devière said.

One month following surgery, esophagogastroduodenoscopy (EGD) examinations revealed that 100% of the staple line persisted in 7 of 12 Mexico City patients. In the remaining patients, the staple line had separated by as much as half of its



Barium swallow image after procedure shows smaller, reshaped stomach.

original length. "Think of a zipper that would open. It doesn't create quite the length of restriction that we provided," Dr. Edmundowicz said.

The issue appears to be a technical one, requiring adjustment of the staple size to accommodate stomach wall thickness. "Our engineers believe they can actually overcome this challenge," he said. "We need to focus on making that staple line much more durable."

Ironically, the weight loss achieved in patients with a separated staple line did not differ statistically from that with a fully intact closure, so consideration also needs to be given to how long a staple line is actually needed, Dr. Edmundowicz added.

At their 3-month follow-up examination, all 21 patients had lost an average of about 12 kg, similar to what would be expected after conventional gastroplasty surgery, Dr. Devière said.

Besides the reduced hospital stay that's made possible by avoiding incisional bariatric surgery, the new procedure, once perfected, could potentially avoid complications associated with a bowel-to-bowel anastomosis, Dr. Edmundowicz noted at a press briefing during the Las Vegas meeting.

"We're really not hooking bowel to bowel, so we don't have to worry about leakage. We don't have to worry about breakdowns," he said. ■

Betsy Bates contributed to this report from Las Vegas.

Less-Invasive Surgical Options In Development for Weight Loss

BY SHERRY BOSCHERT
San Francisco Bureau

SAN DIEGO — Several experimental treatments for obesity are being developed as alternatives to Roux-en-Y surgery or gastric banding.

Devices that are placed endoscopically or surgically may someday fill a gap between low-risk, low-effectiveness diet/exercise strategies and the higher-risk procedures, Dr. Jeffrey S. Brooks said at a symposium on obesity sponsored by the American Society of Bariatric Physicians.

Only 2% of obese patients undergo Roux-en-Y surgery or gastric banding. Rates of death after open procedures are 2% within a month of surgery and 5% within 1 year (JAMA 2005;294:1903-6). Laparoscopic procedures lower the overall reported mortality rate for Roux-en-Y and gastric banding procedures to 1% or less, he noted.

Alternative devices being investigated include gastric balloons (to fill stomach space and give the sensation of satiety with less food) and gastric stimulation devices (to stimulate quicker gastric emptying). "At least one of these will hit the streets in 2-3 years," said Dr. Brooks, a gastroenterologist and chief scientific officer of a company that is developing one of the balloons.

The saline-filled Bioenterics intragastric balloon (BIB) and the air-filled Heliosphere intragastric balloon are in use in some European and South American countries, Mexico, and Canada, he said.

About 2,500 BIBs have been placed in patients in Italy, and studies have ranged from 30 to a few hundred patients.

The BIB contributes to an average weight loss of 15 kg and a five-point decrease in body mass index (BMI) after 6 months, data suggest. The balloon initially causes severe nausea, but the rate of balloon removal in the first few postoperative days is less than 3%, Dr. Brooks

said. Overall rates of removal due to intolerance range from 3% to 9%.

The BIB deflates prematurely in up to 29% of cases, depending on the study. Intestinal obstruction has occurred in 0.3%-5% of patients, and 3% of patients have suffered gastric perforations. The device is contraindicated in patients who have previously had gastric surgery, because they are at highest risk for perforation.

Although supposedly adjustable to fit the patient's size requirements, the BIB is "quite difficult" and not practical to adjust, Dr. Brooks said.

The Heliosphere balloon is relatively easy to put in but very difficult to take out, he said. This double-walled polymer balloon is covered with silicone. Placed endoscopically, it gets inflated with 650-750 mL of air. Like the BIB, it is used for 6 months as an adjunct to diet and exercise. The removal rate for intolerance is around 6%, and about 2% of the devices deflate prematurely, preliminary data suggest.

A third endoscopically placed balloon currently being developed by Dr. Brooks' company, Spatz-FGIA Inc., is expected to be adjustable, he said. Studies in animals so far show no migration or gastric perforations. Two other companies (Satiety Inc. and Fulfillium Inc.) have filed patents for gastric balloons, but it's unclear if and when they will start clinical studies.

Two kinds of gastric stimulators are in development. One by Transneuronix Inc. provides continuous stimulation, and one by Metacureh provides intermittent stimulation when food is ingested.

Impressive European results with gastric stimulation have not been matched by early U.S. data, he noted. A randomized trial of the Transneuronix device in 190 patients in 2004 found that 27% in the stimulator group and 16% in the control group had lost at least 20% of excess weight 1 year later.

"I think it will work for some patients," Dr. Brooks commented. ■

Unexplained Vision Loss Can Stem From Effects of Intestinal Surgery

Vitamin A deficiency due to malabsorption after intestinal surgery should be suspected in patients with unexplained vision loss, based on data from several cases seen in one neuro-ophthalmic practice between January and December 2005.

Dr. Teresa Chae and Dr. Rod Foroosan of Baylor College of Medicine in Houston described three cases where past intestinal surgery was linked to vision loss. All surgeries took place more than 18 years before onset of symptoms. The patients were older than 65 years, and their vitamin A deficiencies were confirmed with blood tests (Br. J. Ophthalmol. 2006;90:955-6).

Patient 1, a 69-year-old man, presented with a 4-month history of night blindness. He had undergone intestinal bypass sur-

gery 20 years earlier, and had a history of childhood hepatitis. Patient 2, an 80-year-old man, reported 4 months of decreased vision in one eye that worsened at night. His history included Crohn's disease and a partial small- and large-bowel resection for a ruptured ileum at age 44 years.

Patient 3, a 79-year-old woman, reported several months of decreased vision, and her history included cholecystectomy with subsequent surgeries to manage complications. Her surgeries occurred 18-20 years before her vision problems began.

Patients 1 and 2 were treated successfully with vitamin A therapy (200,000 IU per day), administered by intramuscular injection. Patient 3 declined vitamin A therapy and had no additional follow-up care.

—Heidi Splette