

# *C. albicans* appendicitis in a neutropenic patient after induction chemotherapy

Rohtesh S. Mehta, MD, MPH, MS, and David Cohen, MD

Division of Hematology/Oncology, University of Pennsylvania Medical Center, Pittsburgh

A 62-year-old white man with a past medical history of hypertension and essential thrombocytosis diagnosed 17 years ago presented at our institution. He was being treated with hydroxyurea, with which he required occasional blood transfusions and platelets were controlled around  $400 \times 10^9/L$  range. Over a 2-month period, he developed gradually worsening exertional dyspnea, fatigue, decreased appetite, lost about 8 lb in weight. He was found to be pancytopenic, with a total white cell count of  $3.26 \times 10^9/L$  (normal,  $3.8-10.6 \times 10^9/L$ ), his hemoglobin level was 7.9 gm/dL (normal, 12.9-16.9 gm/dL), and his platelet count,  $46 \times 10^9/L$ . A bone marrow aspirate and biopsy revealed 100% cellularity, approximately 8%-10% CD34 positive blasts, and numerous atypical and hypolobated dysplastic megakaryocytes with increased reticulin fibrosis. He was diagnosed with myelofibrosis with underlying myeloproliferative disorder, which seemed to be progressing into a more accelerated phase. He was admitted for induction chemotherapy with cytarabine and idarubicin as a bridge to a matched allogeneic stem cell transplant.

He completed 3 days of cytarabine  $100 \text{ mg/m}^2$  and 7 days of idarubicin  $12 \text{ mg/m}^2$  via a Hickman central venous indwelling catheter. On day 7 of the treatment, as his absolute neutrophil count dropped to  $0.9 \times 10^9/L$ , he was started on prophylactic ciprofloxacin 500 mg p.o. BID, and acyclovir 400 mg p.o. TID. Fluconazole was held due to mild hyperbilirubinemia (total bilirubin, 2.2 mg/dL [normal, 0.3-1.5 mg/dL]). On day 11, he spiked a fever of 100.5°F when his absolute neutrophil count was  $0.4 \times 10^9/L$  (normal,  $0.8-3.6 \times 10^9/L$ ). He was started on cefepime; 2 days later, intravenous vancomycin was added as he contin-

ued to have intermittent fevers. He was asymptomatic and had no obvious source of infection. His intravenous catheter site appeared clean and nontender, and his blood and urine cultures were negative as was his chest X-ray. However, as he continued to have intermittent high-grade fevers up to 102.5°F, despite broad spectrum antimicrobials, consultation was sought from the infectious disease physician. On day 15, he was started on voriconazole 400 mg BID. The results of an *Aspergillus galactomannan* antigen test was negative (0.1; reference range, < 0.5).

On day 18, the patient developed mild right lower quadrant abdominal pain associated with mild dyspnea at rest. On examination, he was in mild distress due to pain. His blood pressure was 114/80 mmHg; heart rate, 80 beats/min; respiratory rate, 28 breaths/min; pulse oximetry, 94% on 2-liter nasal cannula oxygen. His lungs were clear to auscultation. The patient was mildly tender in right lower quadrant with mild guarding but no rebound tenderness. Bowel sounds were present. A computed tomography (CT) scan of abdomen and pelvis with contrast showed a dilated appendix up to 1.3 cm in diameter with surrounding fat stranding suggestive of acute appendicitis. No fluid collection or dilated bowel loops were noted (Figure 1). A CT scan of the chest with contrast showed multiple bilateral lung nodular opacities; the largest one in the right middle lobe, was 3 cm in size.

The patient underwent emergency laparotomy and appendectomy, which revealed the presence of an inflamed appendix adherent to the right pelvis side wall, with no gross evidence of tumor. On gross pathological examination, the vermiform appendix showed roughened serosal surface with fibrous adhesions. The appendiceal wall was thickened and focally hemorrhagic. Grey-tan exudate was noted within the lumen. No gross perforation was identified. Histological sections showed an

Manuscript received April 22, 2013; accepted May 6, 2013.

**Correspondence** Rohtesh S. Mehta, MD, MPH, MS, Division of Hematology/Oncology, UPMC Cancer Pavilion, Room 463, 5150 Centre Avenue Pittsburgh, PA 15232 (mehtars@upmc.edu).

**Disclosure** The authors have no disclosures.

Commun Oncol 2013;10:244-246 © 2013 Frontline Medical Communications  
DOI: 10.12788/j.cmonc.0032

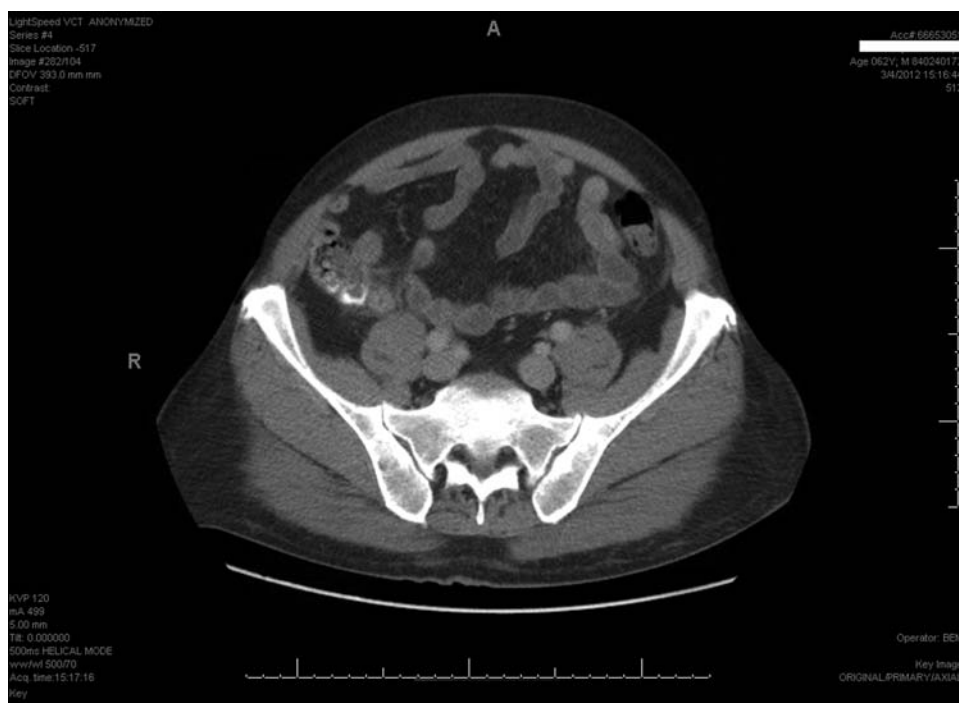appendix lined by a reactive colonic mucosa with diffuse mucosal ulcerations covered by a fibrinopurulent exudate. The muscularis propria was expanded by a dense reactive mixed inflammatory infiltrate primarily composed of lymphocytes, plasma cells, macrophages, neutrophils, mast cells and hematopoietic precursor elements (Figure 2, panel A). The fibrinous exudate contained fungal organisms which on higher magnification showed presence of both pseudohyphae and budding spores, morphologically most consistent with *Candida albicans* (Figure 2, panel B). Grocott Methenamine silver (GMS) stain was performed to confirm the presence of fungal organisms (Figure 2, panel C). Immunostains for CD3, CD20, CD68, and kappa/lambda light chains revealed a mixed population of reactive lymphocytes, histiocytes, and plasma cells. CD34 stain highlighted endothelial cells but no increase in blast population was detected.

The patient tolerated the surgery well. There were no subsequent complications and his fevers subsided with antimicrobial therapy. He was continued on voriconazole for a total of 4 weeks.

## Discussion

This is a rare case of proven invasive fungal appendicitis in an adult neutropenic patient after induction chemotherapy for accelerated phase myelofibrosis. As per the guidelines from the EORTC/MSG Consensus Group, the category “proven invasive fungal disease” (IFD) requires “demonstration of fungal elements in diseased tissue,” specifically, “histopathologic, cytopathologic, or direct microscopic examination of a specimen obtained by needle aspiration or biopsy from a normally sterile site (other than mucous membranes) showing yeast cells.”<sup>1</sup> Cultures, if available, are helpful in “identification at the genus or species level.”

Appendicitis is an extremely rare complication in neutropenic patients with hematological malignancies and most cases are bacterial in origin. In a retrospective analysis of 408 leukemia patients who received chemotherapy, 3 (0.74%) developed acute appendicitis during the phase of neutropenia.<sup>2</sup> Two of these patients had pseudomonas appendicitis, while the cultures were negative in the third. Fungal

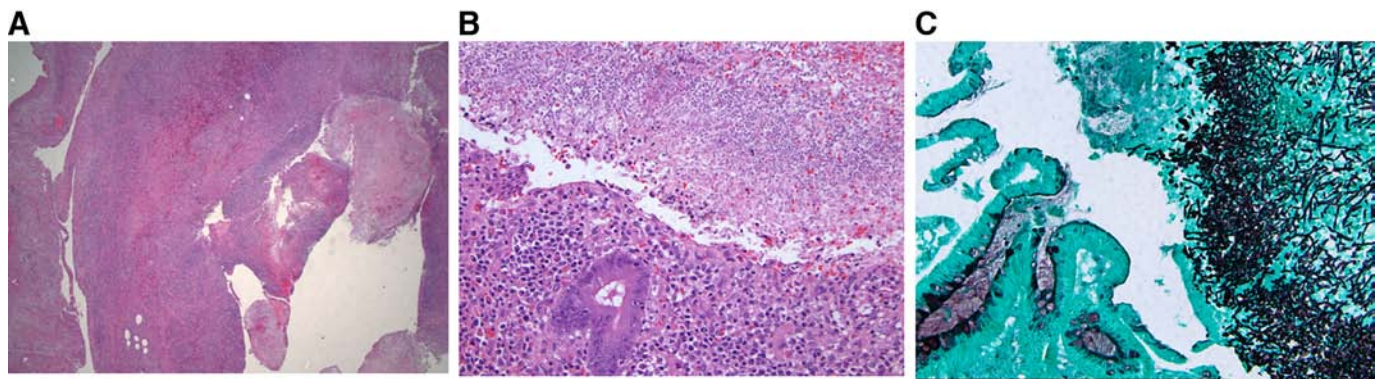


**FIGURE 1** A computed tomography scan of abdomen and pelvis with contrast showing a dilated appendix with surrounding fat stranding suggestive of acute appendicitis; no fluid collection or dilated bowel loops were noted.

appendicitis has only been reported in a handful of cases. In a study of 11 children (mean age, 11 years; range, 3-17 years) with neutropenic appendicitis after chemotherapy for various hematological malignancies, only a single case of fungal (*Aspergillus*) appendicitis was noted.<sup>3</sup> In another study of “acute abdomen” in 18 neutropenic patients with hematologic diseases, appendicitis was found in 3 and fungemia was demonstrated in 2.<sup>4</sup> Few isolated cases of fungal appendicitis due to *Aspergillus* in a patient with acute lymphoblastic leukemia (ALL);<sup>5</sup> *Candida sp.* in a patient with AML;<sup>6</sup> and invasive candidiasis in a patient with acute promyelocytic leukemia have been reported.<sup>7</sup>

Several risk factors for invasive *C. albicans* infections have been identified patients with hematological malignancies during the phase of neutropenia. In a study of acute leukemia patients, younger age, prolonged neutropenia (of 15 days or more) and the use of prophylactic quinolone therapy were found to be independent risk factors for chronic disseminated candidiasis predominant involving liver and spleen. Severe mucositis, *C. albicans* colonization and the use of high-dose cytarabine were significant predictors in univariate analysis only.<sup>8</sup>

Urgent surgical consultation should be sought in all cases because early appendectomy even in the setting of neutropenia is overall well tolerated and is associated with



**FIGURE 2** Panel A, Lower magnification (hematoxylin and eosin, 2x) showing diffuse mucosal ulceration with fibrinopurulent exudate in the lumen and dense inflammatory infiltrate within muscularis propria of the appendix. Panel B, Higher magnification (hematoxylin and eosin, 20x) showing the presence of fungal organisms within the exudate and mixed inflammatory infiltrate within the reactive mucosa. Panel C, Grocott's methenamine silver stain showing the presence of budding forms and pseudohyphae of fungal organisms at the ulcer bed.

improved survival.<sup>3,4</sup> Failure to promptly diagnose appendicitis in neutropenic patients with blunted abdominal signs and negative cultures can lead to life threatening complications of perforation and peritonitis. Antifungal drugs are the mainstay of treatment in conjunction with surgery. The major toxic effects of antifungal medications can be broadly divided into hepatic, renal and hematological. Amphotericin B and flucytosine are highly effective against *C. albicans*, but is associated with high risk of toxicities. Echinocandins (caspofungin, anidulafungin, micafungin) are less toxic, whereas azoles (fluconazole, itraconazole, voriconazole, and posaconazole) have the lowest toxicity profile and are generally very well tolerated.<sup>9</sup> In an in vitro study,<sup>10</sup> amphotericin B and flucytosine were found to be active against all strains of *C. albicans*; voriconazole and caspofungin were active against the majority of isolates; almost 7% of the strains were less sensitive to fluconazole, and about 12% were less sensitive to itraconazole.

### Conclusion

This is a rare case of proven invasive *C. albicans* appendicitis in a neutropenic patient after induction chemotherapy with cytarabine and idarubicin for accelerated phase myelofibrosis. High index of clinical suspicion is required as the typical clinical signs of appendicitis may be blunted in these patients. Neutropenia alone should not be regarded as a contraindication to surgery as early surgery and antifungal management are the keys to improved outcome.

### References

1. De Pauw B, Walsh TJ, Donnelly JP, et al. Revised definitions of invasive fungal disease from the European Organization for Research and Treatment of Cancer/Invasive Fungal Infections Cooperative Group and the National Institute of Allergy and Infectious Diseases Mycoses Study Group (EORTC/MSG) Consensus Group. *Clin Infect Dis*. 2008; 46(12):1813-1821.
2. Al-Anazi KA. Appendicitis in neutropenic patients with leukemia. *Clinical Medicine Insights: Trauma and Intensive Medicine*. 2010; 3:1-7.
3. Mortellaro VE, Juang D, Fike FB, et al. Treatment of appendicitis in neutropenic children. *J Surg Res*. 2011;170(1):14-16.
4. Chirletti P, Barillari P, Sammartino P, et al. The surgical choice in neutropenic patients with hematological disorders and acute abdominal complications. *Leuk Lymphoma*. 1993;9(3):237-241.
5. Weingrad DN, Knapper WH, Gold J, Mertelsmann R. Aspergillus Peritonitis complicating perforated appendicitis in adult acute leukemia. *J Surg Oncol*. 1982;19(1):5-8.
6. Medlicott SA, Cox H, Dupre M, et al. Systemic illnesses unexpectedly presenting as acute appendicitis: case studies. *Can J Surg*. 2008;51(1):73-74.
7. Moyana TN, Kulaga A, Xiang J. Granulomatous appendicitis in acute myeloblastic leukemia: expanding the clinicopathologic spectrum of invasive candidiasis. *Arch Pathol Lab Med*. 1996; 120(2):203-205.
8. Sallah S, Wan JY, Nguyen NP, Vos P, Sigounas G. Analysis of factors related to the occurrence of chronic disseminated candidiasis in patients with acute leukemia in a non-bone marrow transplant setting: a follow-up study. *Cancer*. 2001;92(6):1349-1353.
9. Ashley ESD, Lewis R, Lewis JS, Martin C, Andes D. Pharmacology of Systemic Antifungal Agents. *Clinical Infectious Diseases*. 2006;43(Suppl 1):S28-S39.
10. Cuenca-Estrella M, Rodriguez D, Almirante B, et al. In vitro susceptibilities of bloodstream isolates of Candida species to six antifungal agents: results from a population-based active surveillance programme, Barcelona, Spain, 2002-2003. *J Antimicrob Chemother*. 2005;55(2):194-199.