

# Rapid response to chemotherapy in a patient with thymoma with pericardial effusion

Gurprataap S. Sandhu, MD,<sup>1</sup> Indu Mathew, MD,<sup>1</sup> Liron Pantanowitz, MD,<sup>2</sup> and Rahul A. Parikh, MD, PhD<sup>3</sup>

<sup>1</sup>Department of Internal Medicine, <sup>2</sup>Department Pathology, and <sup>3</sup>Division of Hematology/Oncology, Department of Internal Medicine, University of Pittsburgh Medical Center, Pennsylvania

**T**hymomas are rare tumors involving the anterior mediastinum. Localized thymomas can be surgically resected and have an excellent prognosis, whereas advanced thymomas are treated with induction chemotherapy followed by surgery. We report here the successful use of chemotherapy in a woman with stage IV thymoma with pericardial infiltration and effusion. Our experience suggests that aggressive chemotherapy with a cisplatin- and adriamycin-based regimen can lead to rapid regression of thymoma and significant improvement in symptoms.

## Case presentation

A 59-year-old white woman initially presented with a 2-week history of dyspnea on exertion. Review of systems was significant for night sweats and a weight loss of 20 pounds over 2 months. She had a history of stage IIA, T2N0M0 uterine adenocarcinoma status after a total abdominal hysterectomy and salpingo-oophorectomy and was in remission when she presented. The physical examination was notable for reduced breath sounds in her left upper chest and muffled S1 and S2 heart sounds with no evidence of elevated jugular venous pressure or pulsus paradoxus.

Chest roentgenogram on admission showed a large left hilar mass measuring 8.7 cm (Figure 1A). Trans-thoracic echocardiogram showed diffuse infiltration of the pericardium and a moderate pericardial effusion with an ejection fraction of 55% with no tamponade physiology (Figure 2A). A computed tomography (CT) scan of the chest

showed an anterior mediastinal mass measuring 9.1 x 6.7 cm, encircling and compressing the pulmonary arteries and veins with extensive infiltration into the adjacent pleura and pericardium. A CT of the head, abdomen, and pelvis showed no evidence of metastatic disease.

An ultrasound-guided fine needle aspiration and concomitant core biopsy was performed, which confirmed a lymphocyte predominant thymoma in keeping with World Health Organization type B2 (Figure 3). The biopsy showed large epithelial cells present in a background of many small lymphocytes. Immunostains performed on the epithelial component were positive for pankeratin but negative for CD5 and C-Kit, and the lymphocytes were positive for CD3, CD1a, TdT and CD10 (subset) but were negative for CD20, CD15, CD30 and ALK1. In situ hybridization for Epstein Barr virus-encoded RNA was negative. Serum anti-acetylcholine receptor antibodies were undetectable.

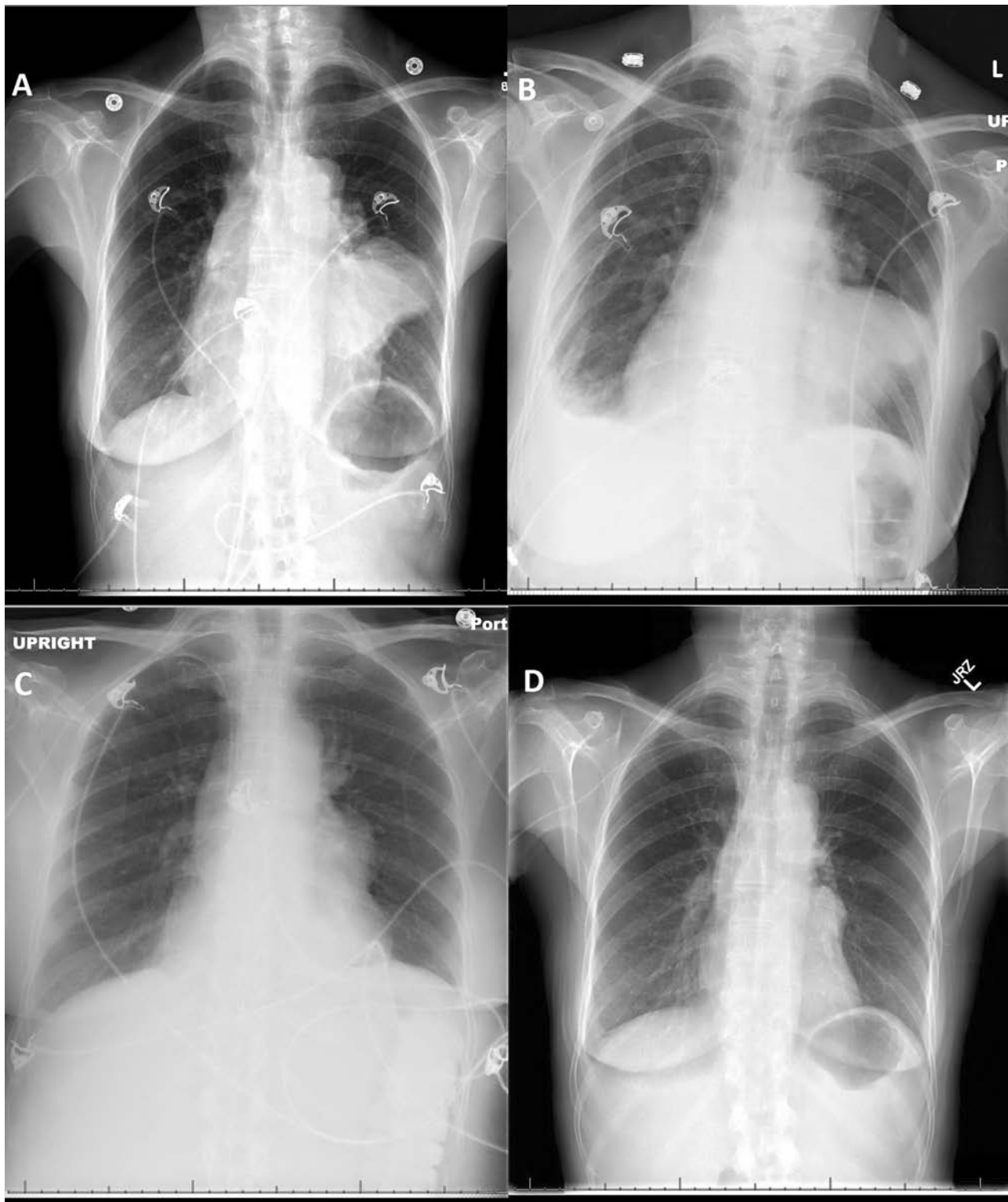The patient was evaluated by the cardiothoracic surgery team and deemed inoperable because of pericardial invasion. During the course of her hospitalization, she had significant worsening hypercapnic respiratory distress with an arterial blood CO<sub>2</sub> level of 85 mm Hg. The patient was transferred to the intensive care unit for noninvasive positive pressure ventilatory support. Given the rapid deterioration in her respiratory status, we decided to initiate in-house chemotherapy with a combination of cyclophosphamide 500 mg/m<sup>2</sup> on day 1, doxorubicin 20 mg/m<sup>2</sup> by continuous infusion on days 1-3, cisplatin 30 mg/m<sup>2</sup> days 1-3, and prednisone 100 mg daily days 1-5.

Manuscript received May 25, 2013; accepted August 21, 2013.

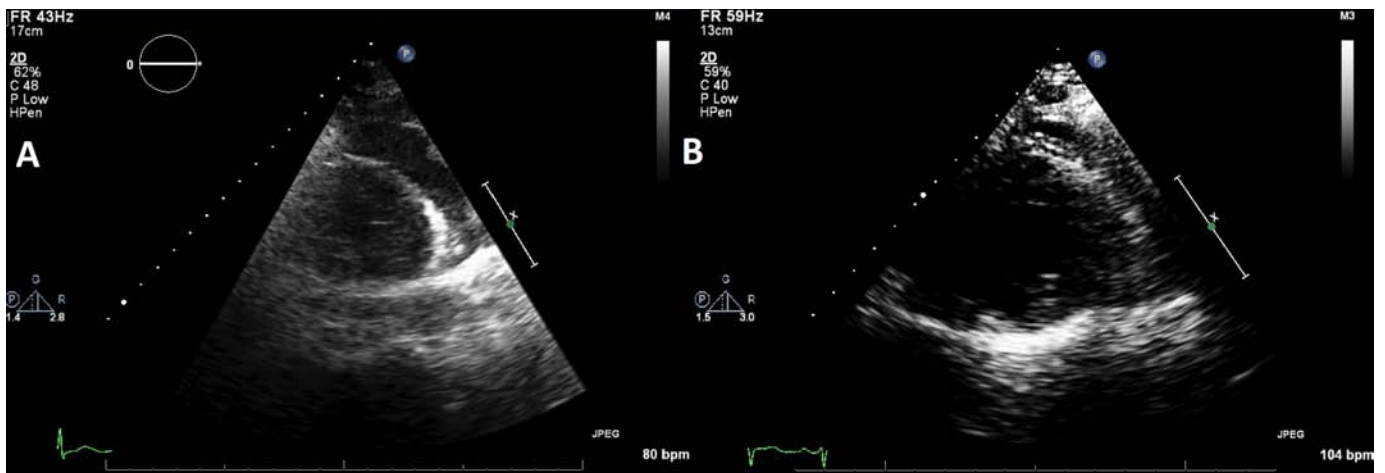**Correspondence** Gurprataap S. Sandhu, MD, University of Pittsburgh Medical Center Presbyterian, 200 Lothrop Street, Pittsburgh, PA 15213 (sandhugs@upmc.edu).

**Disclosures** The authors have no disclosures.

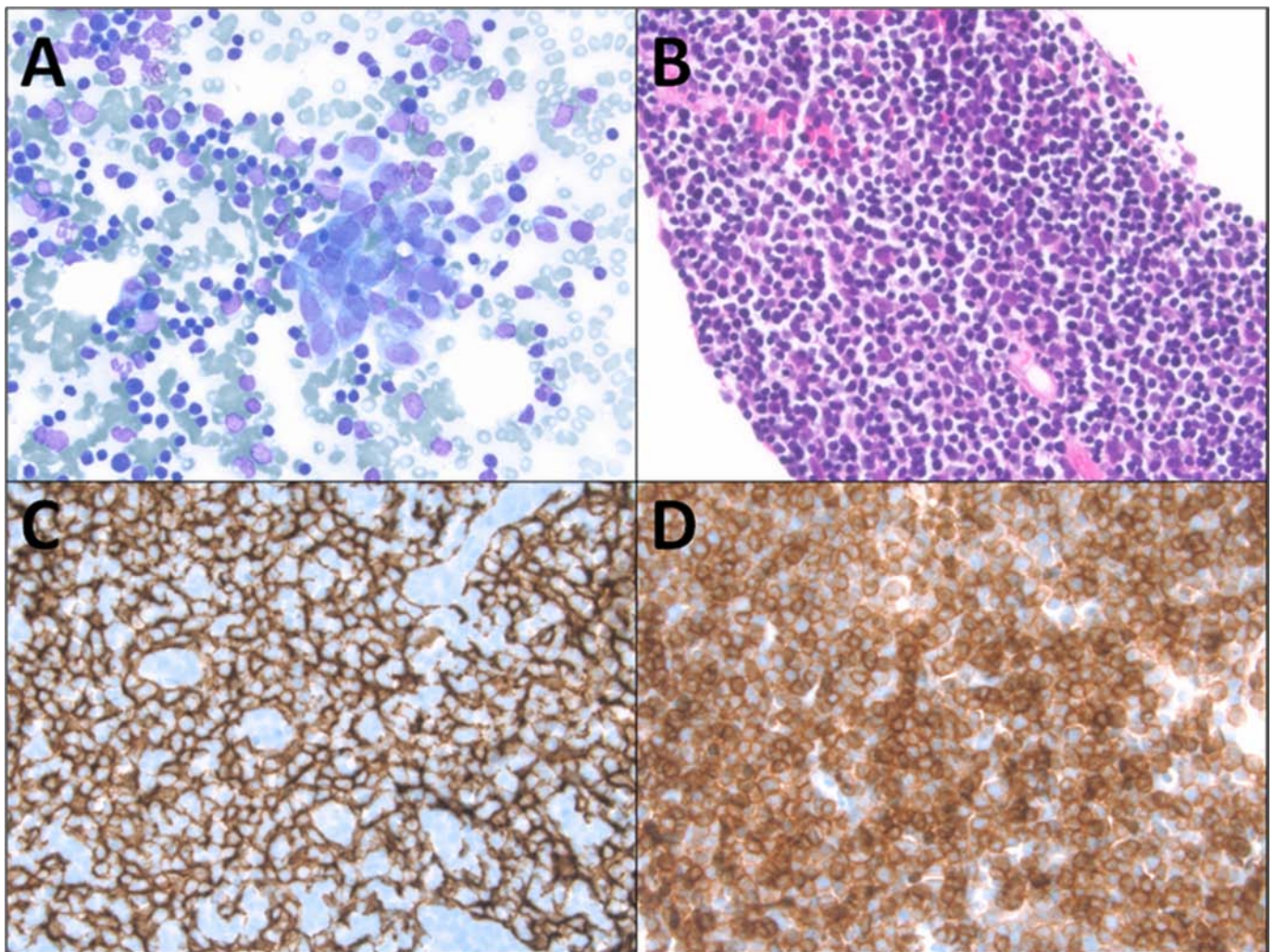
Commun Oncol 2013;10:301-305 © 2013 Frontline Medical Communications  
DOI: 10.12788/j.comonc.0065



**FIGURE 1** Chest roentgenogram: A, On admission; B, Day of initiation of chemotherapy; C, 7 days after first cycle of chemotherapy; and D, 2 months after first cycle of chemotherapy.



**FIGURE 2** Parasternal short-axis view showing pericardial effusion: A, On admission; B, 15 days after first cycle of chemotherapy.



**FIGURE 3** Thymoma histopathology: A, Fine needle aspiration showing biphasic epithelial and lymphoid components (DQ stain, x400); B, Core biopsy showing an abundance of small lymphocytes (H&E stain, x400); C, Pankeratin immunostain showing the underlying dendritic thymic epithelium (IHC stain, x400); D, CD1a demonstrates abundant immature lymphocytes (IHC stain, x400).

**TABLE 1** Summary of staging and therapeutic options for patients with thymoma

Stage	Description	5-year survival, %	Treatment
I	Completely encapsulated	95-100	Surgical resection
II	A Microscopic capsular invasion	86-95	Surgical resection, adjuvant radiation if positive margins
	B Macroscopic capsular invasion		
III	A Macroscopic pleural or pericardial invasion, no great vessel involvement	56-70	Neo-adjuvant chemotherapy followed by surgery or Surgery followed by adjuvant chemotherapy
	B Macroscopic pleural or pericardial invasion with great vessel involvement		
IV	A Pleural or pericardial dissemination	11-50	Neo-adjuvant chemotherapy followed by surgery
	B Distant metastatic disease		Chemotherapy

Over the next week, the patient reported a marked improvement in respiratory status, with complete resolution of her respiratory acidosis. A chest roentgenogram performed seven days after initiation of chemotherapy showed a complete response (Figure 1C), accompanied by a substantial reduction in the size of her pericardial effusion (Figure 2B). She was subsequently discharged home in a stable condition.

**Discussion**

Thymomas are rare epithelial tumors arising from the thymus, but represent 20% of all anterior mediastinal neoplasms in adults.<sup>1</sup> The incidence for thymoma is 1-1.5 per million patients. Patients usually present between the fourth and seventh decades of life. Thymomas can clinically present as an incidental finding in an asymptomatic patient or with dyspnea, chest pain, and cough. About 30%-40% of patients with thymomas present with myasthenia gravis, and pure red cell aplasia is seen in 5%-15% patients with thymoma. Thymomas are classified according to the World Health Organization as: type A (spindle cell or medullary), type AB (mixed), type B1 (lymphocyte-rich), type B2 (cortical), and type B3 (atypical or thymic carcinoma).<sup>2</sup> Thymomas that have a predominance of lymphocytes include type B1 and B2 thymomas. Type B1 thymomas have scant, small epithelial cells, whereas type B2 thymomas are characterized by larger more polygonal epithelial cells, as was seen in our patient's thymoma.

The Masaoka staging system is most commonly used to stage thymomas and correlates well with survival.<sup>3</sup> Epithelial type histology, poor Karnofsky performance status (< 70%) and advanced stage (stages III and IV) are associated with an overall poor prognosis in patients with thymoma.<sup>4</sup> In our case report, we describe a woman with stage IVA unresectable thymoma with contiguous pericardial and pleural involvement, eventually leading to hypercapnic respiratory failure. The conundrum we faced

was whether to drain her moderate to large pericardial effusion prior to initiating chemotherapy, create a pericardial window and consider radiation, or start her on chemotherapy under close observation.

Since thymomas are rare, there is a paucity of randomized clinical trial information to guide therapy. Based on extensive literature studies, the current recommendation for the treatment of thymomas is summarized in Table 1.<sup>5</sup> For our patient with stage IV thymoma, the recommended management is neoadjuvant chemotherapy followed by surgery with the goal of complete resection. If complete resection is not possible, maximum debulking surgery is recommended. If the tumor is inoperable after neoadjuvant chemotherapy, concurrent chemoradiation is recommended. Neoadjuvant chemotherapy in multimodality treatment has been studied in 3 prospective studies, and included a total of 61 patients ranging in sample size from 16 to 23 patients. Based on a phase 2 trial, we treated our patient with cyclophosphamide 500 mg/m<sup>2</sup> on day 1, doxorubicin 20 mg/m<sup>2</sup> by continuous infusion on days 1-3, cisplatin 30 mg/m<sup>2</sup> days 1-3 and prednisone 100 mg daily days 1-5.<sup>6</sup> An alternative regimen using cyclophosphamide 500 mg/m<sup>2</sup>, adriamycin 50 mg/m<sup>2</sup>, and cisplatin 50 mg/m<sup>2</sup> was associated with an overall response rate of 50%, with a median duration of response of 11.8 months and median overall survival of 37.7 months.<sup>7</sup>

In summary, we observed an excellent clinical and radiologic response in our patient with a stage IVA thymoma with significant cardio-pulmonary compromise due to her underlying disease. Rapid initiation of cisplatin and adriamycin based chemotherapy under such circumstances can result in improvement and should be strongly considered.

**References**

1. Gerein AN, Srivastava SP, Burgess J. Thymoma: a ten year review. *Am J Surg.* 1978;136:49-53.

2. Travis WD, Brambilla E, Müller-Hermelink HK, Harris CC. *Tumours of the lung, pleura, thymus and heart*. Lyon: IARC Press; 2004.
3. Masaoka A, Monden Y, Nakahara K, Tanioka T. Follow-up study of thymomas with special reference to their clinical stages. *Cancer*. 1981;48:2485-2492.
4. Gripp S, Hilgers K, Wurm R, Schmitt G. Thymoma: prognostic factors and treatment outcomes. *Cancer*. 1998;83:1495-1503.
5. Falkson CB, Bezjak A, Darling G, et al. The management of thymoma: a systematic review and practice guideline. *J Thorac Oncol*. 2009;4:911-919.
6. Kim ES, Putnam JB, Komaki R, et al. Phase II study of a multidisciplinary approach with induction chemotherapy, followed by surgical resection, radiation therapy, and consolidation chemotherapy for unresectable malignant thymomas: final report. *Lung Cancer*. 2004;44:369-379.
7. Loehrer PJ Sr., Kim K, Aisner SC, et al. Cisplatin plus doxorubicin plus cyclophosphamide in metastatic or recurrent thymoma: final results of an intergroup trial. The Eastern Cooperative Oncology Group, Southwest Oncology Group, and Southeastern Cancer Study Group. *J Clin Oncol*. 1994;12:1164-1168.