

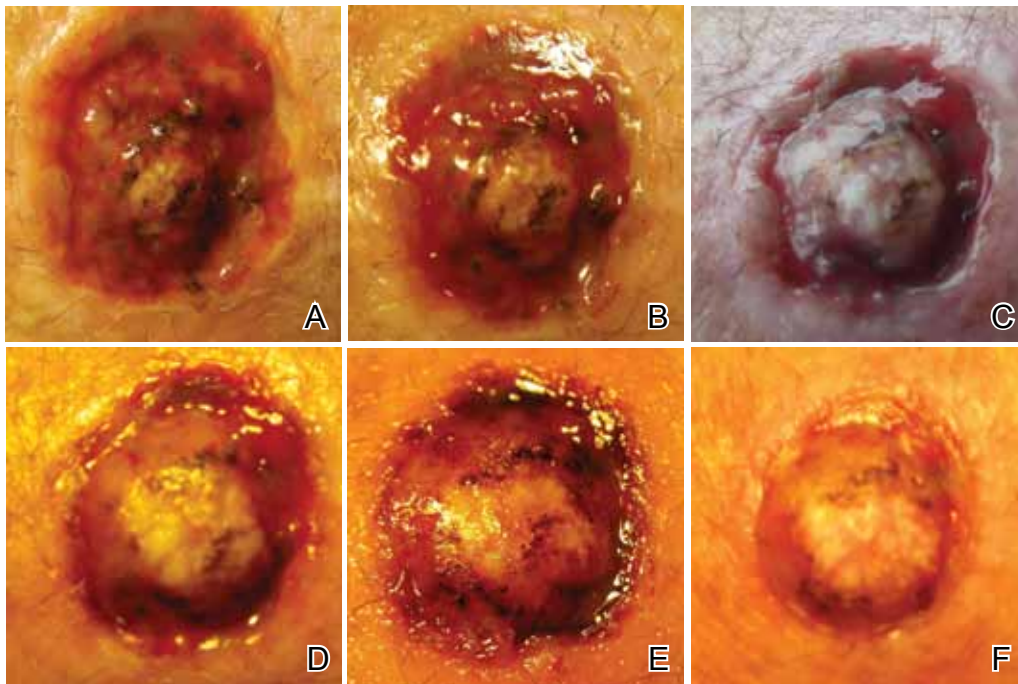
Case Letter

Rapidly Recurring Keratoacanthoma

To the Editor:

A 61-year-old man with a medical history of type 2 diabetes mellitus presented to us with a 2.5×3.0-cm erythematous, ulcerated, and exophytic tumor on the right dorsal forearm that had rapidly developed over 2 weeks. A tangential biopsy was performed followed by treatment with electrodesiccation and curettage (ED&C). Histology revealed a squamous cell carcinoma (SCC), keratoacanthoma (KA) type. Over the next 11 days the lesion rapidly recurred and the patient returned with his own daily photodocumentation of

the KA's progression (Figure). The lesion was re-excised with 5-mm margins; histology again revealed SCC, KA type, with deep margin involvement. Chest radiograph revealed findings suspicious for metastatic lesions in the right lung. He was referred to oncology for metastatic workup; positron emission tomography was negative and ultimately the lung lesion was found to be benign. The patient underwent adjuvant radiation to the KA resection bed and lymph nodes with minimal side effects. The patient has remained cancer free to date.



Keratoacanthoma recurrence at day 1 (A), day 3 (B), day 5 (C), day 6 (D), day 7 (E), and day 9 (F) following electrodesiccation and curettage.

Drs. Hunter-Ellul, Dacso, Robare-Stout, and Wilkerson are from the Department of Dermatology, The University of Texas Medical Branch at Galveston. Dr. Reddy is from Boston University, School of Medicine, Massachusetts.

The authors report no conflict of interest.

Correspondence: Michael Wilkerson, MD, The University of Texas Medical Branch, Department of Dermatology, 301 University Blvd, 4.112 McCullough Bldg, Galveston, TX 77555-0783 (mgwilker@utmb.edu).

Keratoacanthomas are rapidly growing, typically painless, cutaneous neoplasms that often develop on sun-exposed areas. They can occur spontaneously or following trauma and have the propensity to regress with time.¹⁻³ They are described as progressing through 3 clinical stages: rapid proliferation, mature/stable, and involution. However, KAs can be aggressive, becoming locally destructive; therefore, KAs are typically treated

to avoid further morbidity. Keratoacanthomas may be considered a subtype of SCC, as some have the potential to become locally destructive and metastasize.^{3,5} There are reports of spontaneous resolution of KAs over weeks to months, though surgical excision is the gold standard of treatment.^{3,5}

Reactive KA is a subtype that is thought to develop at the site of prior trauma, representing a sort of Köbner phenomenon.^{3,4} We demonstrated a case of a recurrent KA in the setting of recent ED&C. Several reports describe KAs developing after dermatologic surgery, including Mohs micrographic surgery, laser resurfacing, radiation therapy, and after skin grafting.^{3,4,6} Trauma-induced epidermal injury and dermal inflammation may play a role in postoperative KA formation or recurrence.⁶

Keratoacanthoma recurrence has been reported in 3% to 8% of cases within a few weeks after treatment, as seen in our current patient.^{3,5} In our case, the patient photodocumented the regrowth of his lesion (Figure). Treatment of reactive KAs may be therapeutically challenging, as they can form or worsen with repeated surgeries and may require several treatment modalities to eradicate them.⁴ Treatment options include observation, ED&C, excision, Mohs micrographic surgery, radiation, cryosurgery, laser, isotretinoin, acitretin, imiquimod, 5-fluorouracil, methotrexate, interferon alfa-2b, or bleomycin, to name a few.^{3,4,7}

Combination therapy should be considered in the presence of recurrent and/or aggressive KAs, such

as in our case. Our patient has remained disease free after a combination of surgical excision with radiation therapy.

Lindsey Hunter-Ellul, MD
Shalini Reddy, MD
Mara Dacso, MD
Samantha Robare-Stout, MD
Michael Wilkerson, MD

REFERENCES

1. Schwartz R. Keratoacanthoma. *J Am Acad Dermatol.* 1994;30:1-19.
2. Kingman J. Keratoacanthoma. *Arch Dermatol.* 1984;20:736-740.
3. Goldberg L, Silapunt S, Beyrau K, et al. Keratoacanthoma as a postoperative complication of skin cancer excision. *J Am Acad Dermatol.* 2004;50:753-758.
4. Hadley J, Tristani-Firouzi P, Florell S, et al. Case series of multiple recurrent reactive keratoacanthomas developing at surgical margins. *Dermatol Surg.* 2009;35:2019-2024.
5. Karaa A, Khachemoune A. Keratoacanthoma: a tumor in search of a classification. *Int J Dermatol.* 2007;46:671-678.
6. Chesnut GT, Maggio KL, Turiansky GW. Letter: re: case series of multiple recurrent reactive keratoacanthomas developing at surgical margins. *Dermatol Surg.* 2011;37:884-885.
7. Lerner V, Ricci C, Albertini G. Spontaneous regression of keratoacanthoma can be promoted by topical treatment with imiquimod cream. *J Eur Acad Dermatol Venereol.* 2004;18:626-629.