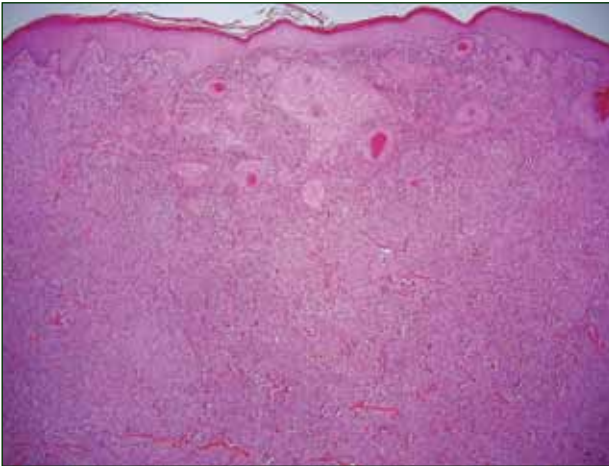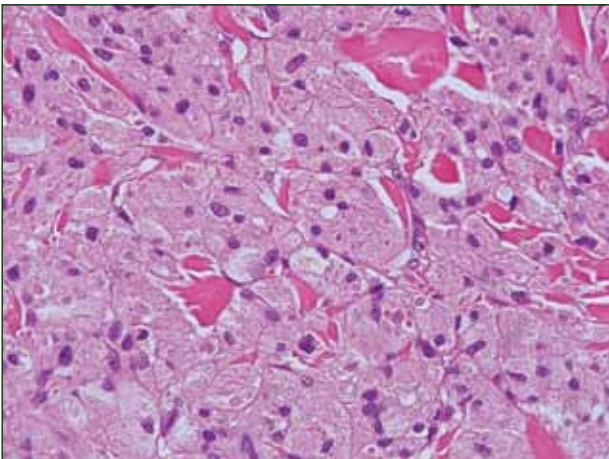


H&E, original magnification ×40.



H&E, original magnification ×600.

## The best diagnosis is:

- a. granular cell tumor
- b. lepromatous leprosy
- c. mastocytoma
- d. reticulohistiocytoma
- e. xanthelasma

PLEASE TURN TO PAGE 279 FOR DERMATOPATHOLOGY DIAGNOSIS DISCUSSION

Victoria Vaughan, BA; Tammie Ferringer, MD

Ms. Vaughan is from the Medical College of Georgia, Georgia Regents University, Augusta. Dr. Ferringer is from the Departments of Dermatology and Laboratory Medicine, Geisinger Medical Center, Danville, Pennsylvania.

The authors report no conflict of interest.

Correspondence: Victoria Vaughan, BA, Medical College of Georgia, Georgia Regents University, 1004 Chafee Ave, FH-100, Augusta, GA 30904 (viclava@gmail.com).

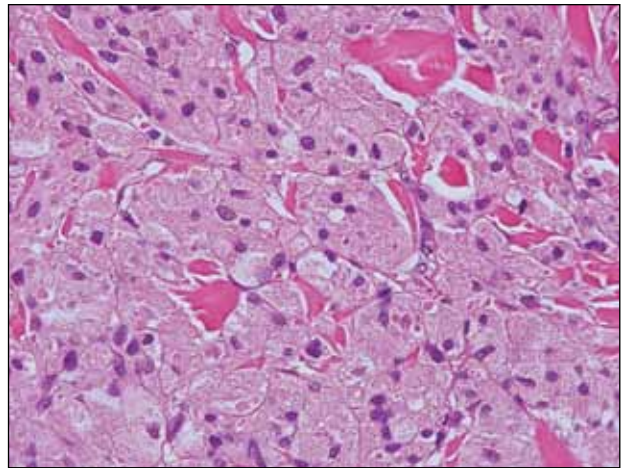
## Granular Cell Tumor

**G**ranular cell tumors (GCTs) tend to present as solitary nodules, not uncommonly affecting the dorsum of the tongue but also involving the skin, breasts, and internal organs.<sup>1</sup> Cutaneous GCTs typically present as 0.5- to 3-cm firm nodules with a verrucous or eroded surface.<sup>2</sup> They most commonly present in dark-skinned, middle-aged women but have been reported in all age groups and in both sexes.<sup>3</sup> Multiple GCTs are reported in up to 25% of cases, rarely in association with LEOPARD syndrome (consisting of lentigines, electrocardiographic abnormalities, ocular hypertelorism, pulmonary stenosis, abnormalities of genitalia, retardation of growth, and deafness).<sup>4</sup> Granular cell tumors generally are benign with a metastatic rate of approximately 3%.<sup>2</sup>

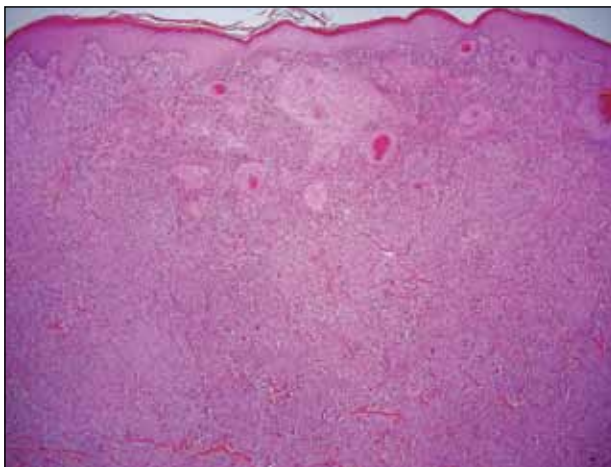
Granular cell tumors are histopathologically characterized by sheets of large polygonal cells with small, round, central nuclei; cytoplasm that is eosinophilic, coarse, and granular, as well as periodic acid–Schiff positive and diastase resistant; and distinct cytoplasmic membranes (Figure 1). Pustulo-ovoid bodies of Milian often generally appear as larger eosinophilic granules surrounded by a clear halo (Figure 2).<sup>5</sup> Increased mitotic activity, a high nuclear-cytoplasmic ratio, pleomorphism, and necrosis suggest malignancy.<sup>6</sup> Pseudoepitheliomatous hyperplasia may be found and may lead to a misdiagnosis of squamous cell carcinoma if the biopsy is taken too superficially. Granular cell tumors are thought to be Schwann

cell derived, which is supported by expression of the S-100 protein and neuron-specific enolase.

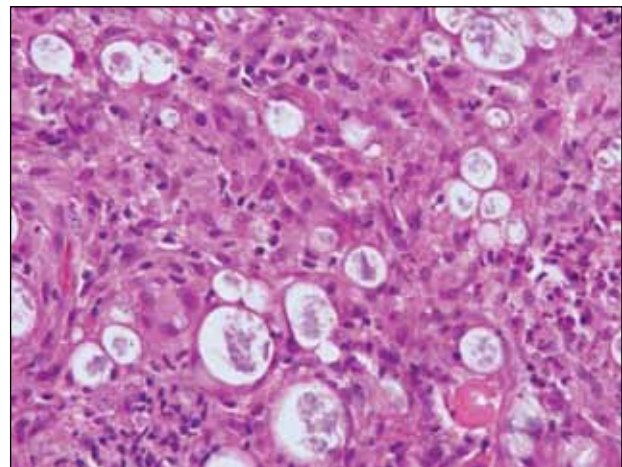
Lepromatous leprosy is characterized by sheets of histiocytes with vacuolated cytoplasm, some with clumped amphophilic bacilli known as globi (Figure 3). Mastocytoma can be distinguished from GCTs by the “fried egg” appearance of the mast cells (Figure 4). Although mast cells have a pale granular cytoplasm, they are smaller and lack pustulo-ovoid bodies and the polygonal shape of GCT cells. Reticulohistiocytoma,



**Figure 2.** Sheets of large polygonal cells with central nuclei; coarse, eosinophilic, granular cytoplasm; and large eosinophilic cytoplasmic pustulo-ovoid bodies of Milian characterize a granular cell tumor (H&E, original magnification  $\times 600$ ).

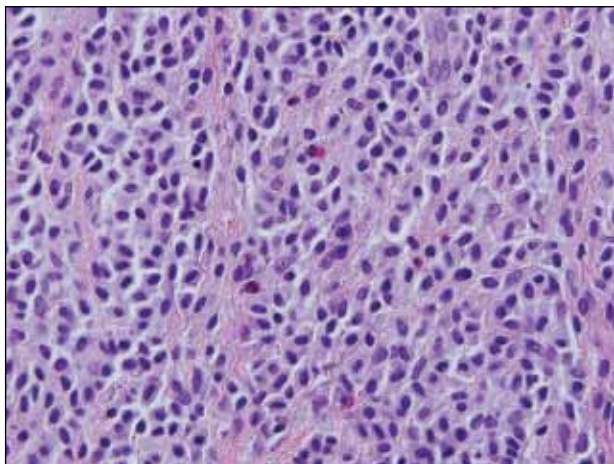


**Figure 1.** Pseudoepitheliomatous hyperplasia and sheets of polygonal cells with light pink cytoplasm of a granular cell tumor (H&E, original magnification  $\times 40$ ).

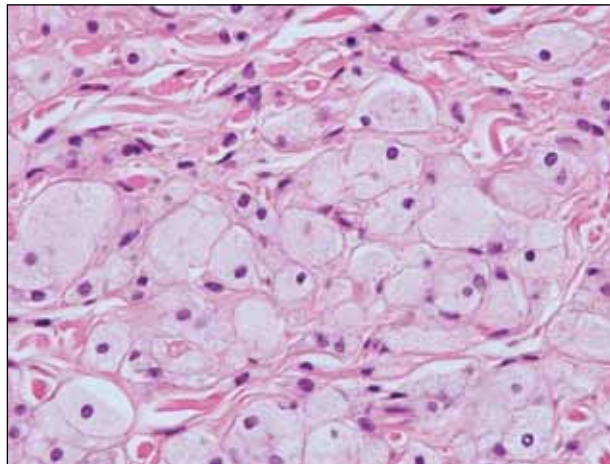


**Figure 3.** Lymphohistiocytic infiltrate with amphophilic collections of mycobacteria (globi) in lepromatous leprosy (H&E, original magnification  $\times 600$ ).

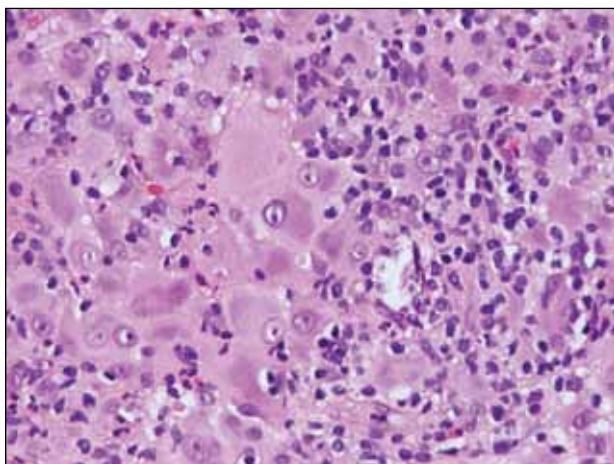




**Figure 4.** Small “fried egg” mast cells with pale granular cytoplasm and admixed eosinophils in a mastocytoma (H&E, original magnification  $\times 600$ ).



**Figure 6.** Aggregates of histiocytes with foamy cytoplasm in xanthelasma (H&E, original magnification  $\times 600$ ).



**Figure 5.** Sea of histiocytes containing dusty rose or ground glass cytoplasm with two-toned darker and lighter areas in a reticulohistiocytoma (H&E, original magnification  $\times 600$ ).

on the other hand, has two-toned dusty rose ground glass histiocytes (Figure 5), and xanthelasma can be distinguished histologically from GCT by the presence of a foamy rather than granular cytoplasm (Figure 6).

## REFERENCES

1. Elston DM, Ko C, Ferringer TC, et al, eds. *Dermatopathology: Requisites in Dermatology*. Philadelphia, PA: Saunders Elsevier; 2009.
2. Bologna JL, Jorizzo JL, Schaffer JV. *Dermatology*. 3rd ed. Philadelphia, PA: Elsevier; 2012.
3. van de Loo S, Thunnissen E, Postmus P, et al. Granular cell tumor of the oral cavity; a case series including a case of metachronous occurrence in the tongue and the lung [published online ahead of print June 1, 2014]. *Med Oral Patol Oral Cir Bucal*. doi:10.4317/medoral.19867.
4. Schrader KA, Nelson TN, De Luca A, et al. Multiple granular cell tumors are an associated feature of LEOPARD syndrome caused by mutation in PTPN11. *Clin Genet*. 2009;75:185-189.
5. Epstein DS, Pashaei S, Hunt E Jr, et al. Pustulo-ovoid bodies of Milian in granular cell tumors. *J Cutan Pathol*. 2007;34:405-409.
6. Fanburg-Smith JC, Meis-Kindblom JM, Fante R, et al. Malignant granular cell tumor of soft tissue: diagnostic criteria and clinicopathologic correlation. *Am J Surg Pathol*. 1998;22:779-794.