

Mycoplasma pneumoniae Infection in Adults With Acute and Chronic Urticaria

To the Editor:

Mycoplasma pneumoniae has been implicated as a cause of acute urticaria (AU) in children,¹ but its role in adults with AU is unknown. The aim of this retrospective study was to compare the incidence of acute *M pneumoniae* infection in adults with AU and chronic urticaria (CU).

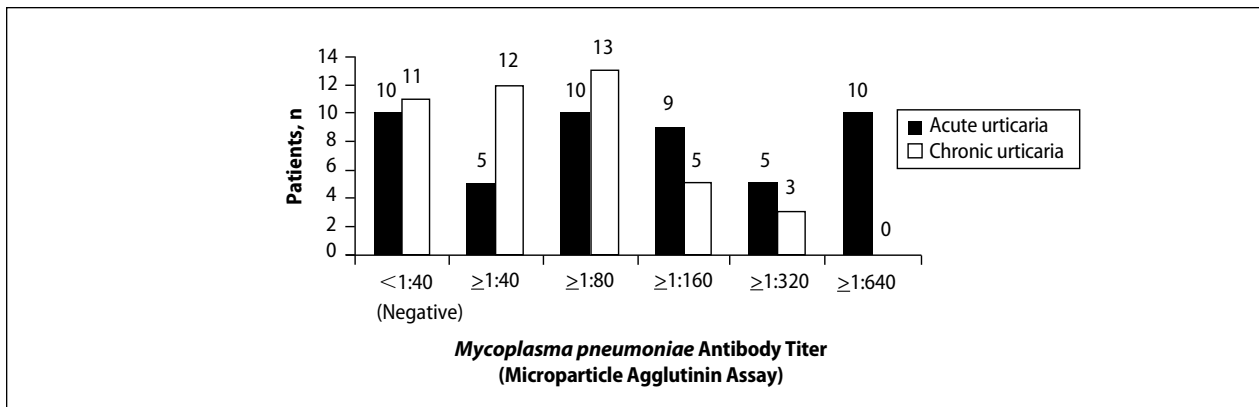
A chart review was performed on adult patients with AU and CU who presented at a private dermatology practice in Singapore. Acute *M pneumoniae* infection was diagnosed on the basis of a single indirect microparticle agglutinin assay (MAA) titer of 1:320 or higher. All statistical tests were performed using SPSS version 13.0. $P < .05$ was regarded as significant. Data from 49 adults with AU and 44 adults with CU were analyzed. The distribution of MAA titers in adults with AU and CU are shown in the Figure. Microparticle agglutinin assay was negative in 10 (20.4%) of 49 adults with AU. Fifteen (30.6%) of 49 adults with AU had evidence of acute *M pneumoniae* infection, as indicated by an MAA titer of 1:320 or higher. The remaining 24 (49.0%) had evidence of prior infection as indicated by titers above the manufacturer's cutoff of 1:40² and below our cutoff for acute infection of 1:320 or higher. Microparticle agglutinin assay was negative in 11 (25%) of 44 adults with CU. Three (6.8%) adults with CU were diagnosed with acute *M pneumoniae* infection and 30 (68.2%) were diagnosed with prior infection. The incidence of acute *M pneumoniae* infection was 30.6% in adults with AU compared to 6.8% in adults with CU, and the difference was statistically significant ($P = .004$).

Extrapulmonary complications of *M pneumoniae* involving practically every organ system have been described and 25% of patients develop cutaneous symptoms³ including AU. In 2007, Kano et al⁴ reported *M pneumoniae* infection-induced erythema nodosum, anaphylactoid purpura, and AU in a family of 3. This report was interesting because it showed that *M pneumoniae* had the ability to elicit different cutaneous reactions depending on the maturity of the adaptive immunity of a host, even among individuals of a common genetic background. A Taiwanese study found that 21 (32%) of 65 children with AU had *M pneumoniae* infection as determined by a positive *Mycoplasma* IgM test or an equivocal *Mycoplasma* IgM coupled with positive cold agglutinin test results.¹

In our study, we found serological evidence of acute *M pneumoniae* infection in 15 (30.6%) of 49 adults with AU compared to 3 (6.8%) of 44 adults with CU ($P = .004$), suggesting that *M pneumoniae* also may play a role in the etiology of adult AU. Diagnosis of acute *M pneumoniae* infection is challenging, as it is often impossible to obtain convalescent serum that will show the 4-fold rise in titer. Single MAA titers of 1:160 or higher have been recommended for diagnosis of acute infection,⁵ but because of higher background activity in Singapore, we used a higher titer ($\geq 1:320$). However, in doing so, we could be underestimating the true incidence of acute *M pneumoniae* infections.

The role of *M pneumoniae* in CU is uncertain. A Thai study reported that 55% of 38 children with CU had elevated *M pneumoniae* titers but did not provide details of actual titers or define what they meant by elevated titers.⁶ The incidence of acute and prior infection in our patients with CU was 6.8% and 68.2%, respectively. Unfortunately, we cannot determine the significance of the 68.2% incidence rate of prior infection in the absence of a normal control population of patients without urticaria. Another limitation of this study is that we compared *M pneumoniae* infection rate in AU with CU on the assumption that infection is not likely to play a significant role in CU, which may not necessarily be the case. Tests for other etiologic agents, including viruses, also were not performed. Notwithstanding

Dr. CSH Lim is from the Central Manpower Base, Ministry of Defence, Singapore. Drs. SL Lim and KB Lim are from K.B. Lim Skin Clinic Pte Ltd, Gleneagles Medical Centre, Singapore. The authors report no conflict of interest.
Correspondence: Christopher SH Lim, MBBS, Central Manpower Base, 3 Depot Rd, Singapore 109680 (fluppy888@yahoo.com).



Mycoplasma pneumoniae antibody titer in patients with acute urticaria (n=49) and chronic urticaria (n=44).

these limitations, this study suggests that acute *M pneumoniae* infection is significantly more common in adults with AU than in adults with CU.

This study showed that *M pneumoniae* might play a role in the etiology of AU in adults and our findings need to be confirmed by prospective studies. Several more questions must be answered before deciding whether the current practice of treating AU symptomatically without investigation needs to be changed. First, does treatment of *M pneumoniae* infection have any influence on the course of AU? The fact that AU usually is self-limiting suggests that treatment may not influence the disease course. Second, does treatment of underlying *M pneumoniae* infection shorten the course of AU? Third, do AU patients with untreated *M pneumoniae* infection face a higher risk for developing CU? This question is intriguing for the following reasons: (1) 30% to 50% of CU cases are autoimmune in etiology⁷; (2) antibodies to galactocerebroside that cross-react with glycolipids on *M pneumoniae* have been detected in patients with *M pneumoniae*-associated Guillain-Barré syndrome, suggesting a form of molecular mimicry⁸; and (3) antinuclear antibody also has occasionally been detected in sera of patients with *M pneumoniae*.⁹ It would be interesting to test patients with autoimmune and nonautoimmune CU for evidence of *M pneumoniae* serology infection.

We hope that prospective studies will be conducted in the future to confirm our findings and answer some of the questions raised.

Christopher SH Lim, MBBS
SiewLin Lim, MBBS
KahBeng Lim, MBBS, MRCP

REFERENCES

1. Wu CC, Kuo HC, Yu HR, et al. Association of acute urticaria with *Mycoplasma pneumoniae* infection in hospitalized children. *Ann Allergy Asthma Immunol*. 2009;103:134-139.
2. Serodia-Myco II [package insert]. Tokyo, Japan: Fujirebo; 2013.
3. Murray HW, Masur H, Senterfit LB, et al. The protean manifestations of *Mycoplasma pneumoniae* infection in adults. *Am J Med*. 1975;58:229-242.
4. Kano Y, Mitsuyama Y, Hirahara K, et al. *Mycoplasma pneumoniae* infection-induced erythema nodosum, anaphylactoid purpura, and acute urticaria in 3 people in a single family. *J Am Acad Dermatol*. 2007;57(suppl 2):S33-S35.
5. Daxboeck F, Krause R, Wenisch C. Laboratory diagnosis of *Mycoplasma pneumoniae* infection. *Clin Microbiol Infect*. 2003;9:263-273.
6. Pongpreuksa S, Boochoo S, Kulthanan K, et al. Chronic urticaria: what is worth doing in pediatric population? *J Allergy Clin Immunol*. 2004:S134.
7. Grattan CE. Autoimmune urticaria. *Immunol Allergy Clin North Am*. 2004;24:163-181.
8. Kusunoki S, Shiina M, Kanazawa I. Anti-Gal-C antibodies in GBS subsequent to mycoplasma infection: evidence of molecular mimicry. *Neurology*. 2001;57:736-738.
9. Arikan S, Ergüven S, Ustaçelebi S, et al. Detection of antinuclear antibody (ANA) in patients with Mycoplasma pneumoniae. *Turk J Med Sci*. 1998;28:97-98.