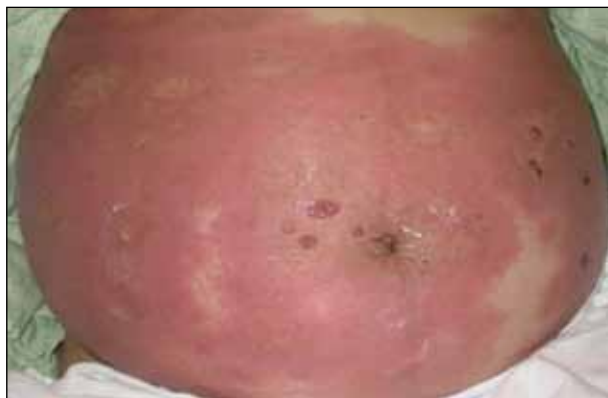
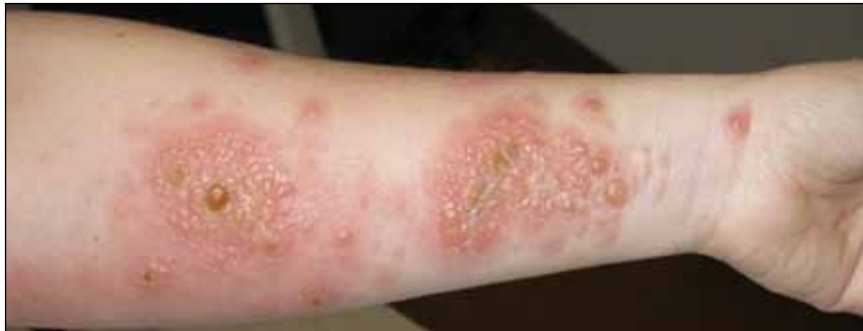
## What Is Your Diagnosis?



A 37-year-old pregnant woman at 25 weeks' gestation presented with a generalized pruritic rash of 3 weeks' duration. The rash had initiated around the umbilicus and continued to progress with subsequent involvement of the arms and legs. The patient reported no allergies or current medications, and her personal and family history was unremarkable. She had 2 prior uncomplicated pregnancies and deliveries. Physical examination revealed severe ecchymotic plaques, vesicles, and bullae on the arms (top), as well as confluent erythematous plaques on the abdomen (bottom), back, and legs. The mucosal surfaces, face, palms, and soles were spared. Laboratory values were within reference range.

PLEASE TURN TO PAGE 270 FOR DISCUSSION

Erwin E. Argueta, MD; Jaime A. Tschen, MD

Dr. Argueta is from Texas Tech University Health Sciences Center, Lubbock. Dr. Tschen is from St. Joseph Dermatopathology, Houston, Texas.

The authors report no conflict of interest.

Correspondence: Erwin E. Argueta, MD, 3601 4th St, MS 9410, Lubbock, TX 79401 (erwin.argueta@ttuhsc.edu).

## The Diagnosis: Pemphigoid Gestationis (Herpes Gestationis)

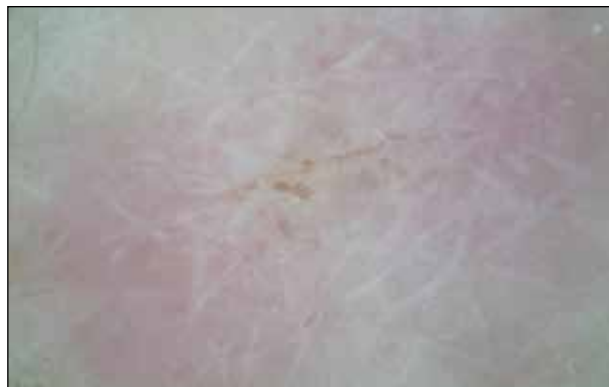**D**ermoscopy revealed a patch of erythema with early central vesiculation (Figure 1). Perilesional skin biopsies revealed subepidermal bullae, and direct immunofluorescence revealed linear C3 and IgG deposition at the dermoepidermal junction (Figure 2).

Dermatoses of pregnancy are uncommon and may demonstrate similar clinical manifestations. Pemphigoid gestationis (herpes gestationis) is a condition that may initially mimic other pregnancy-related skin diseases but is followed by the classic manifestations of a bullous disease. A biopsy specimen is needed to identify the epidermal lesions that are present. Once identified, it responds to treatment with steroids.

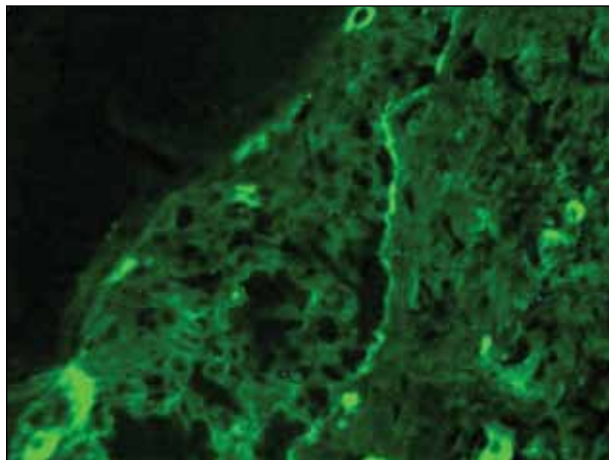
Pemphigoid gestationis is a skin disorder in which circulating IgG autoantibodies react against transmembrane proteins and hemidesmosomal components of the epidermal basal cells.<sup>1</sup> This process leads to complement protein activation through the classical pathway, which promotes leukocyte recruitment and degranulation. The initial clinical manifestation includes pruritus, which is followed by characteristic bullous lesions.

Pemphigoid gestationis is hypothesized to arise from pathologic maternal IgG induced by paternal HLA antigens found in the placenta.<sup>2</sup> The incidence of pemphigoid gestationis is thought to range from 1:10,000 to 1:50,000,<sup>3</sup> with typical presentation in the second or third trimesters. It may be exacerbated during delivery and generally resolves after delivery. The periumbilical region is the first site affected with subsequent spreading to the arms and legs.<sup>3</sup> The initial differential diagnosis based on patient history can include an adverse drug reaction or pruritic urticarial papules and pustules of pregnancy. Diagnosis is based on histologic examination of a perilesional skin biopsy. Light microscopy of the biopsy typically reveals subepidermal bullae with a predominance of infiltrated eosinophils. Direct immunofluorescence of the biopsy specimen usually confirms the diagnosis with the presence of linear C3 and IgG deposition at the dermoepidermal junction. Indirect immunofluorescence occasionally may reveal IgG deposition in the basal membrane.<sup>4</sup>

Treatment generally includes the use of topical and oral steroids.<sup>2,5</sup> Fetal risks associated with the disease include premature birth and low birth weight.<sup>2,3</sup> Our patient initially was started on a 1-mg/kg dose of oral prednisone and topical steroid (prednisone 60 mg in a tapering dose every 5 days); she showed a good response at 1-week follow-up. She was well controlled with a lower maintenance



**Figure 1.** A patch of erythema with early central vesiculation.



**Figure 2.** Direct immunofluorescence demonstrated the linear staining pattern of C3 deposition at the dermoepidermal junction (original magnification  $\times 40$ ).

dose through the rest of the pregnancy and did not show subsequent disease exacerbation.

### REFERENCES

1. Parker SR, MacKelfresh J. Autoimmune blistering disease in the elderly. *Clin Dermatol.* 2011;29:69-79.
2. Shornick JK. Dermatoses of pregnancy. *Semin Cutan Med Surg.* 1998;17:172-181.
3. Al-Fouzan AW, Galadari I, Oumeish I, et al. Herpes gestationis (pemphigoid gestationis). *Clin Dermatol.* 2006;24:109-112.
4. Imber MJ, Murphy GF, Jordon RE. The immunopathology of bullous pemphigoid. *Clin Dermatol.* 1987;5:81-92.
5. Kirtschig G, Middleton P, Bennett C, et al. Interventions for bullous pemphigoid. *Cochrane Database Syst Rev.* 2010:CD002292.