

# Pruritic Urticarial Papules and Plaques of Pregnancy Occurring Postpartum

Alma Leyla Dehdashti, DO; Schield M. Wikas, DO

## Practice Points

- Pruritic urticarial papules and plaques of pregnancy (PUPPP) is an intensely pruritic eruption that typically affects women during the third trimester of pregnancy.
- Because clinical manifestations can vary, PUPPP should be considered in the differential diagnosis when patients present in the postpartum period with a pruritic eruption.
- Histologic findings are not diagnostic but can help distinguish PUPPP from other pregnancy-associated dermatoses.

*Pruritic urticarial papules and plaques of pregnancy (PUPPP) (also known as polymorphic eruption of pregnancy in Europe) is an intensely pruritic eruption that affects women during the third trimester of pregnancy. Treatment usually is aimed at symptom relief until delivery, as the eruption usually resolves rapidly in the postpartum period. We report the case of a 30-year-old woman who presented 2 weeks postpartum with an intensely pruritic generalized eruption. The eruption started on the abdominal striae within 24 hours of delivery and gradually spread to the buttocks, legs, and arms. Punch biopsy confirmed a diagnosis of PUPPP. Pruritic urticarial papules and plaques of pregnancy presenting in the postpartum period is extremely rare. We present this case for clinical interest and to remind clinicians to keep PUPPP as a consideration in the differential diagnosis when evaluating pruritic eruptions in women who are in the postpartum period.*

*Cutis.* 2015;95:344-347.

---

Dr. Dehdashti is from Mid-Michigan Dermatology, PLLC, Lansing.  
Dr. Wikas is from Tri-County Dermatology, Inc, Cuyahoga Falls, Ohio.  
The authors report no conflict of interest.  
Correspondence: Alma Leyla Dehdashti, DO, Mid-Michigan Dermatology, PLLC, Office Park West, 416 S Creyts Rd, Lansing, MI 48917 (almaleyla@gmail.com).

The cutaneous effects of pregnancy are variable and numerous. We all have likely seen the pigmentary changes induced by pregnancy as well as both exacerbation and complete resolution of preexisting skin conditions. The dermatoses of pregnancy are classified as a group of inflammatory skin conditions exclusively seen in pregnant women, the most common being pruritic urticarial papules and plaques of pregnancy (PUPPP).<sup>1</sup> Also known as polymorphic eruption of pregnancy in Europe, PUPPP was first recognized in 1979 as a distinct entity that manifested as an intense pruritic eruption unique to women in the third trimester of pregnancy.<sup>2</sup> The condition usually is self-limited, with the majority of cases spontaneously resolving within 4 to 6 weeks after delivery.<sup>3,4</sup> Presentation of PUPPP in the postpartum period is rare.<sup>1-4</sup> We report a biopsy-proven case of PUPPP in a 30-year-old woman who presented 2 weeks postpartum with an intensely pruritic generalized eruption. A PubMed search of articles indexed for MEDLINE using the search terms *pruritic urticarial papules and plaques of pregnancy* or *polymorphic eruption of pregnancy* and *postpartum* revealed only 5 reports of PUPPP or polymorphic eruption of pregnancy occurring in the postpartum period, 2 occurring in the United States.<sup>5-9</sup>

## Case Report

A 30-year-old woman who was 2 weeks postpartum presented to our dermatology clinic with an

intensely pruritic generalized rash. Within 24 hours of delivery of her first child, the patient developed an itchy rash on the abdomen and was started on oral corticosteroids and antihistamines in the hospital. On discharge, she was instructed to follow up with the dermatology department if the rash did not resolve. After leaving the hospital, she reported that the eruption had progressively spread to the buttocks, legs, and arms, and the itching seemed to be worse despite finishing the course of oral corticosteroids and antihistamines.

The patient's prenatal course was uneventful. She gained 16 kg during pregnancy, with a prepregnancy weight of 50 kg. A healthy male neonate was delivered at 38 weeks' gestation without complication. The patient's medical history was unremarkable. Her current medications included prenatal vitamins, oral prednisone, and loratadine, and she reported no known drug allergies.

On physical examination, the patient was afebrile and her blood pressure was normal. Examination of the skin revealed erythematous papules and urticarial plaques involving the abdominal striae with periumbilical sparing (Figure 1A). Similar lesions were noted on the legs, buttocks, and arms (Figure 1B). The face, palms, and soles were uninvolved. No vesicles or pustules were noted. The oral mucosa was pink, moist, and unremarkable.

Based on the patient's clinical presentation, the differential diagnosis included pemphigoid gestationis, a hypersensitivity reaction, cutaneous lupus, cholestasis of pregnancy, and PUPPP. Pruritic urticarial papules and plaques of pregnancy was considered to be unlikely because of the uncharacteristic postpartum presentation of the eruption.

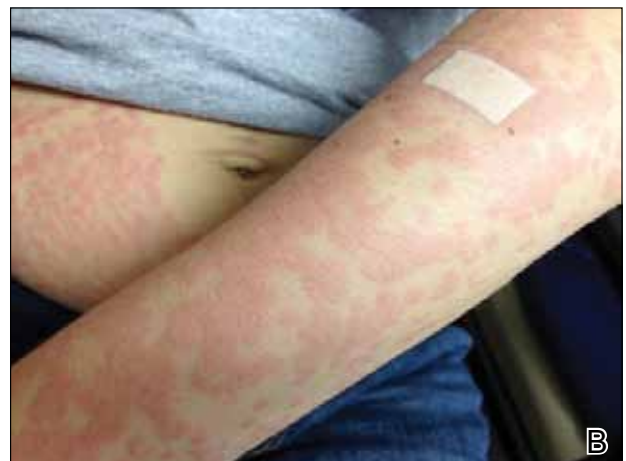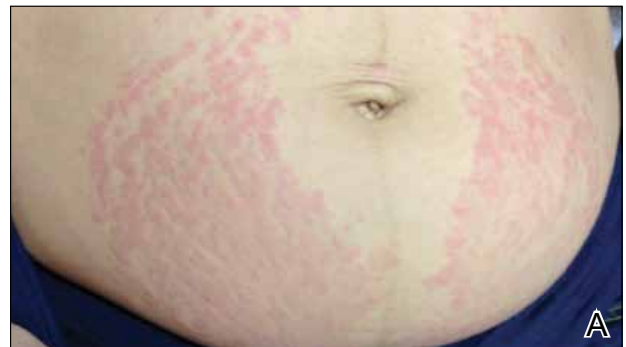Two 4-mm punch biopsies were performed on the left upper arm and were sent for histopathologic examination and direct immunofluorescence. Laboratory studies including complete blood cell count with differential, complete metabolic panel, antinuclear antibodies, and IgE levels were conducted. The patient was started on triamcinolone cream 0.1% twice daily and her antihistamine was switched from loratadine to cetirizine.

Histopathologic examination revealed a mixed perivascular infiltrate in the superficial dermis consisting of lymphocytes, mast cells, and eosinophils (Figures 2 and 3), which was consistent with a diagnosis of PUPPP. Direct immunofluorescence was negative. Laboratory studies were within reference range and antinuclear antibodies and IgE levels were negative. A diagnosis of postpartum PUPPP was made. Complete resolution of the eruption was experienced by 2-week follow-up (Figures 4A and 4B). The patient noted that her symptoms improved within 2 days of starting topical therapy.

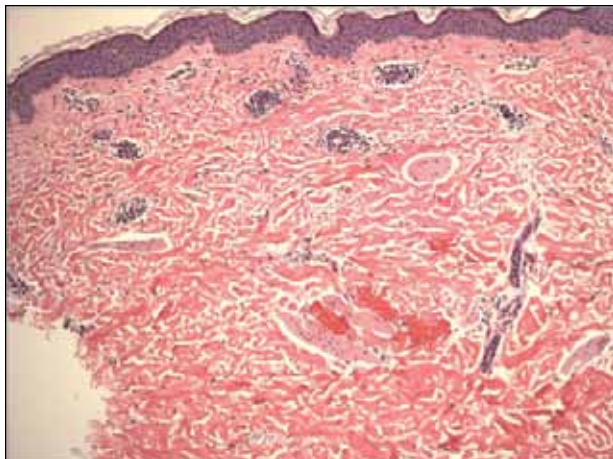
## Comment

Pruritic urticarial papules and plaques of pregnancy complicates 1 of 160 to 1 of 300 pregnancies.<sup>1</sup> As seen in our case, the majority of cases of PUPPP are diagnosed in women who are nulliparous or primigravida.<sup>10</sup> A study by Aronson et al<sup>10</sup> reported that of 57 cases of PUPPP, 24 (42%) patients were primigravida, 16 (28%) were gravida 2, 9 (16%) were gravida 3, 4 (7%) were gravida 4, 3 (5%) were gravida 6, and 1 (2%) was gravida 7. Thirty-nine (68%) patients were nulliparous.<sup>10</sup> The average onset of symptoms is approximately 35 weeks' gestation.<sup>9</sup>

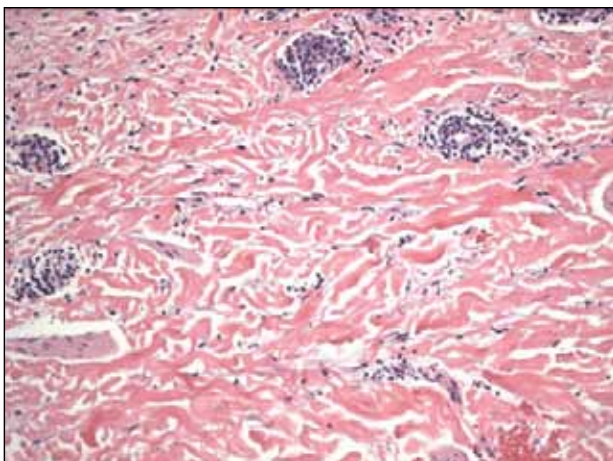
Classical presentation of PUPPP starts with erythematous papules within the abdominal striae, sparing the periumbilical skin.<sup>1</sup> The abdominal striae are most commonly affected, and in some women, it may be the only site affected.<sup>10</sup> The lesions then may progress to urticarial plaques involving the extremities, while the face, palms, and soles usually are spared.<sup>11</sup> However, clinical manifestations of PUPPP can vary, with reports of targetlike lesions with a surrounding



**Figure 1.** Initial presentation of urticarial plaques involving the abdominal striae with periumbilical sparing (A) and the left arm (B).



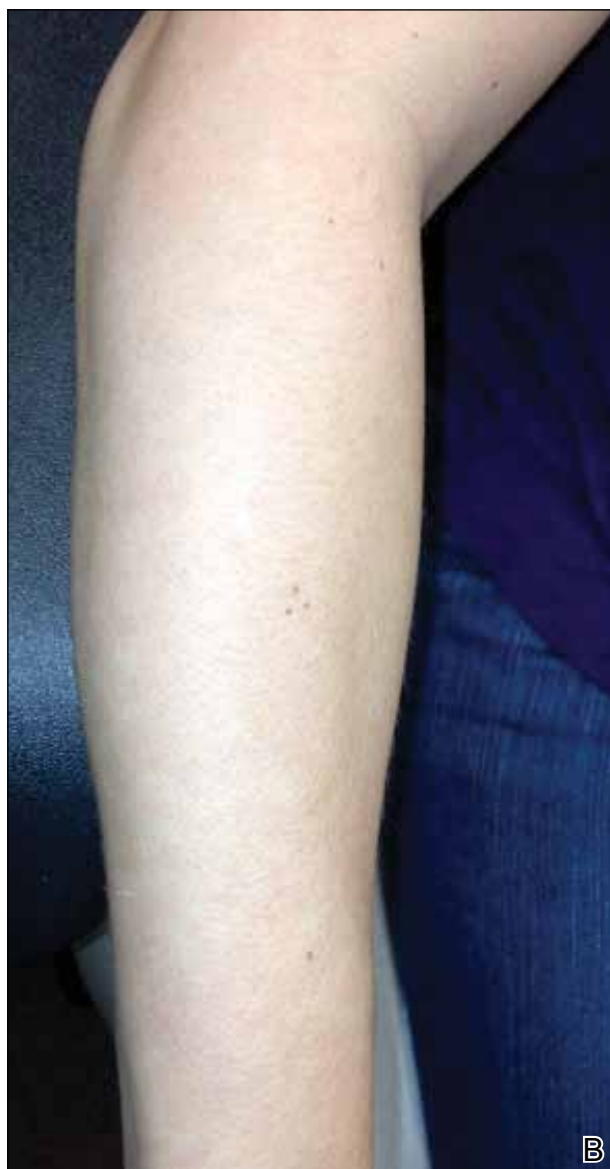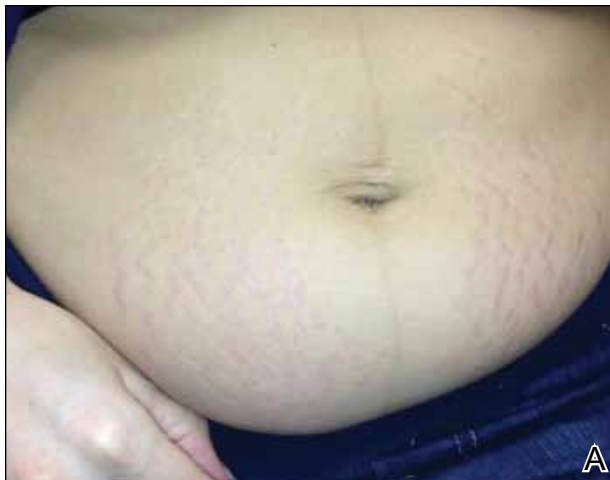**Figure 2.** Perivascular infiltrate in the superficial dermis (H&E, original magnification  $\times 20$ ).



**Figure 3.** Mixed perivascular infiltrate (H&E, original magnification  $\times 40$ ).

halo resembling erythema multiforme as well as involvement of the face and palmoplantar skin.<sup>10-13</sup> Histologic findings are not diagnostic but can help distinguish PUPPP from other pregnancy-associated dermatoses.<sup>14</sup> Histologically, PUPPP demonstrates variable epidermal spongiosis and a nonspecific superficial perivascular infiltrate in the dermis composed of lymphocytes with eosinophils or neutrophils, and there may be dermal edema.<sup>10,15</sup> Direct immunofluorescence usually is negative in PUPPP; however, 31% of cases have demonstrated deposition of C3 and IgM or IgA, either perivascularly or at the dermoepidermal junction.<sup>1,10,15</sup>

There are no systemic alterations seen in PUPPP; however, all patients report severe pruritus.<sup>12</sup> Pruritic urticarial papules and plaques of pregnancy typically affects women in the third trimester, and delivery is



**Figure 4.** Complete resolution of the eruption on the abdomen (A) and the left arm (B) at 2-week follow-up.

curative in most patients.<sup>13</sup> Recurrence of PUPPP usually is not seen with subsequent pregnancies, and the long-term prognosis is excellent.<sup>15</sup>

The pathogenesis of PUPPP is not well understood and likely is multifactorial. Ohel et al<sup>12</sup> found PUPPP to be strongly associated with hypertensive disorders, multiple gestation pregnancies, excessive maternal weight gain, excessive stretching of the abdominal skin, and nulliparity.<sup>13</sup> One theory suggests that abdominal skin stretching, if drastic, can damage underlying connective tissue, resulting in the release of antigens that can trigger a reactive inflammatory response.<sup>16</sup> The majority of maternal weight gain occurs during the third trimester, which may explain why most cases of PUPPP present in the third trimester.<sup>17</sup> Alternative theories have suggested that PUPPP may represent an immunologic response to circulating fetal antigens.<sup>18</sup> It is possible, as in our case, that certain nulliparous women who have a healthy weight prior to pregnancy (as determined by a body mass index of 18.5 to 24.9) in combination with excessive weight gain during the third trimester and drastic hormone fluctuations associated with labor and delivery may be at greater risk for developing PUPPP. Another theory may be related to the degree of skin stretching during the third trimester and the abrupt decrease in the stretching of the skin that occurs with delivery.<sup>16</sup>

## Conclusion

Pruritic urticarial papules and plaques of pregnancy can present in a variety of ways, most commonly in the third trimester but also in the postpartum period. When a patient presents in the postpartum period with a pruritic eruption, PUPPP should be included in the differential diagnosis. The pathogenesis of PUPPP is multifactorial and not well understood, and additional research in the field may lead to improved prediction of who may be at risk and what we can do to prevent it.

## REFERENCES

1. Pomeranz MK. Dermatoses of pregnancy. UpToDate Web site. <http://www.uptodate.com/contents/dermatoses-of-pregnancy>. Updated December 22, 2014. Accessed May 5, 2015.
2. Lawley TJ, Hertz KC, Wade TR, et al. Pruritic urticarial papules and plaques of pregnancy. *JAMA*. 1979;241:1696-1699.
3. Kroumpouzou G, Cohen LM. Specific dermatoses of pregnancy: an evidence-based systematic review. *Am J Obstet Gynecol*. 2003;188:1083-1092.
4. Callen JP, Hanno R. Pruritic urticarial papules and plaques of pregnancy (PUPPP): a clinicopathologic study. *J Am Acad Dermatol*. 1981;5:401-405.
5. Ozcan D, Ozcakmak B, Aydogan FC. *J Obstet Gynaecol Res*. 2011;37:1158-1161.
6. Journet-Tollhupp J, Tchen T, Remy-Leroux V, et al. Polymorphic eruption of pregnancy and acquired hemophilia A [in French]. *Ann Dermatol Venerol*. 2010;137:713-717.
7. Buccolo LS, Viera AJ. Pruritic urticarial papules and plaques of pregnancy presenting in the postpartum period: a case report. *J Reprod Med*. 2005;50:61-63.
8. Kirkup ME, Dunnill MG. Polymorphic eruption of pregnancy developing in the puerperium. *Clin Exp Dermatol*. 2002;27:657-660.
9. Yancy KB, Hall RP, Lawley TJ. Pruritic urticarial papules and plaques of pregnancy: clinical experience in twenty-five patients. *J Am Acad Dermatol*. 1984;10:473-480.
10. Aronson IK, Bond S, Fiedler VC, et al. Pruritic urticarial papules and plaques of pregnancy: clinical and immunopathologic observations in 57 patients. *J Am Acad Dermatol*. 1998;39:933-939.
11. Roger D, Vaillant L, Fignon A, et al. Specific pruritic dermatoses of pregnancy: a prospective study of 3129 women. *Arch Dermatol*. 1994;130:734-739.
12. Ohel I, Levy A, Silberstein T, et al. Pregnancy outcome of patients with pruritic urticarial papules and plaques of pregnancy. *J Matern Fetal Neonatal Med*. 2006;19:305-308.
13. Elling SV, McKenna P, Pawell FC. Pruritic urticarial papules and plaques of pregnancy in twin and triplet pregnancies. *J Eur Acad Dermatol Venereol*. 2000;14:378-381.
14. Scheinfeld N. Pruritic urticarial papules and plaques of pregnancy wholly abated with one week twice daily application of fluticasone propionate lotion: a case report and review of the literature. *Dermatol Online J*. 2008;14:4.
15. Shornick JK. Dermatoses of pregnancy. *Semin Cutan Med Surg*. 1998;17:172-181.
16. Cohen LM, Capeless EL, Krusinski PA, et al. Pruritic urticarial papules and plaques of pregnancy and its relationship to maternal-fetal weight gain and twin pregnancy. *Arch Dermatol*. 1989;125:1534-1536.
17. Drehmer M, Duncan BB, Kac G, et al. Association of second and third trimester weight gain in pregnancy with maternal and fetal outcomes. *PLoS One*. 2013;8:e54704.
18. Aractingi S, Berkane N, Bertheau P, et al. Fetal DNA in skin of polymorphic eruptions of pregnancy. *Lancet*. 1998;352:1898-1901.