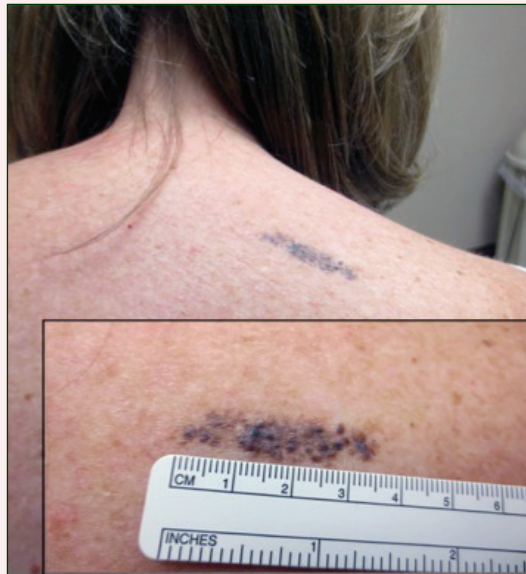

Linear Bluish-Black Papules on the Shoulder



A 57-year-old woman presented with an asymptomatic, unchanging, 3.5×0.7-cm linear plaque on the right shoulder composed of dozens of clustered, bluish-black papules that had been present for several decades. The skin between the papules was unaffected. The patient's medical and family histories were unremarkable. A deep shave biopsy from the center of the plaque was performed.

What's the diagnosis?

- agminated blue nevus
- agminated Spitz nevus
- dermal melanocytosis
- melanoma
- pilar neurocristic hamartoma

Katalin Ferenczi, MD; Arni Kristjansson, MD; Jane M. Grant-Kels, MD

From the Department of Dermatology and Dermatopathology, University of Connecticut Health Center, Farmington.

The authors report no conflict of interest.

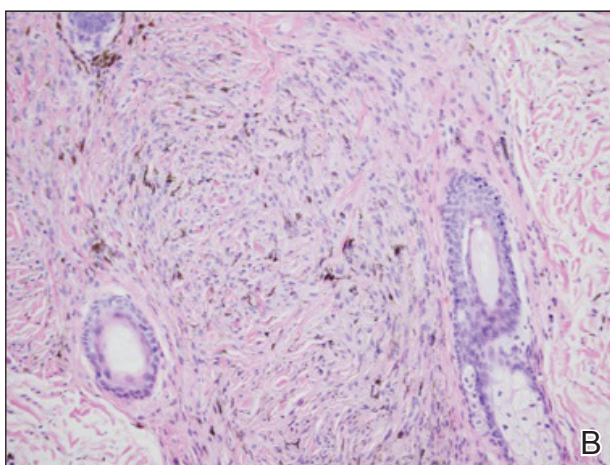
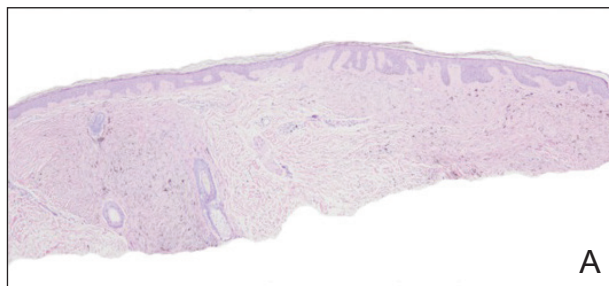
Correspondence: Katalin Ferenczi, MD, University of Connecticut Health Center, Department of Dermatology and Dermatopathology, 21 South Rd, Farmington, CT 06030 (ferenczi@uchc.edu).

The Diagnosis: Agminated Blue Nevus

Agminated blue nevus is a rare melanocytic nevus that characteristically presents as a group of multiple small, bluish papules occurring in a well-circumscribed area.¹ It also has been referred to as a plaque-type nevus^{2,3} and an eruptive blue nevus.⁴ Originally described by Upshaw et al² in 1947, agminated blue nevi may be congenital or arise in early childhood and almost always occur on the trunk. The skin between the papules often is unaffected or sometimes may show bluish or brown pigmentation.⁴ Agminated blue nevi usually are smaller than 10 cm in diameter; however, rare cases have measured up to 24 cm.^{1,4-6} The incidence of agminated blue nevi is 2 times higher in males than in females.¹

Histopathologically, agminated blue nevi typically demonstrate the features of common and/or cellular blue nevi. Cytologic atypia and mitoses are rare.¹ The degree of cellularity and pigmentation of the lesions is variable, and the presence of subcutaneous cellular nodules also has been described.⁵

In our patient, histologic evaluation revealed foci of diffuse dermal spindle cell proliferation composed of heavily pigmented dendritic melanocytes admixed with melanophages in a fibrotic stroma (Figure, A). The dermis was uninvolved in some areas and the melanocytes were epithelioid and formed fascicles and bundles that extended down adnexal structures in other areas (Figure, B). Junctional involvement of melanocytes, cellular atypia, and mitoses were not identified. Our case demonstrated a combination of histologic findings of a cellular blue nevus as well as features reminiscent of a deep penetrating nevus. The differential diagnosis of agminated blue nevus includes agminated Spitz nevus arising in a speckled lentiginous nevus,⁷ dermal melanocytosis, melanoma, and pilar neurocristic hamartoma. Pilar neurocristic hamartomas may resemble plaque-type blue nevi; however, the former show a predilection for the scalp, histologically demonstrate features that overlap with blue nevi and congenital nevi, and are associated with neural structures that show Schwannian differentiation.⁸ Agminated blue nevi usually are characterized by a benign clinical course, but few cases describing malignant changes with development of malignant melanoma have been reported.^{9,10} Therefore, recognition of the clinical and histopathologic spectrum of agminated



A biopsy of the lesion revealed pigmented dendritic melanocytes admixed with melanophages, forming fascicles and bundles (A)(H&E, original magnification $\times 10$). In some areas the dermis was uninvolved. Higher magnification showed dendritic and epithelioid melanocytes extending down along the adnexal structures (B)(H&E, original magnification $\times 40$).

blue nevus is critical in order to avoid diagnostic pitfalls and confusion with melanoma.

REFERENCES

1. Vélez A, del-Río E, Martín-de-Hijas C, et al. Agminated blue nevi: case report and review of the literature. *Dermatology*. 1993;186:144-148.
2. Upshaw BY, Ghormley RK, Montgomery H. Extensive blue nevus of Jadassohn-Tièche; report of a case. *Surgery*. 1947;22:761-765.
3. Pittman JL, Fisher BK. Plaque-type blue nevus. *Arch Dermatol*. 1976;112:1127-1128.

Photo Challenge Discussion

4. Hendricks WM. Eruptive blue nevi. *J Am Acad Dermatol.*1981;4:50-53.
5. Busam KJ, Woodruff JM, Erlandson RA, et al. Large plaque-type blue nevus with subcutaneous cellular nodules. *Am J Surg Pathol.* 2000;24:92-99.
6. Shenfield HT, Maize JC. Multiple and agminated blue nevi. *J Dermatol Surg Oncol.* 1980;6:725-728.
7. Misago N, Narisawa Y, Kohda H. A combination of speckled lentiginous nevus with patch-type blue nevus. *J Dermatol.* 1993;20:643-647.
8. Bevona C, Tannous Z, Tsao H. Dermal melanocytic proliferation with features of a plaque-type blue nevus and neurocristic hamartoma. *J Am Acad Dermatol.* 2003;49:924-929.
9. Yeh I, Fang Y, Busam KJ. Melanoma arising in a large plaque-type blue nevus with subcutaneous cellular nodules. *Am J Surg Pathol.* 2012;36:1258-1263.
10. Zattra E, Salmaso R, Montesco MC, et al. Large plaque type blue nevus with subcutaneous cellular nodules. *Eur J Dermatol.* 2009;19:287-288.