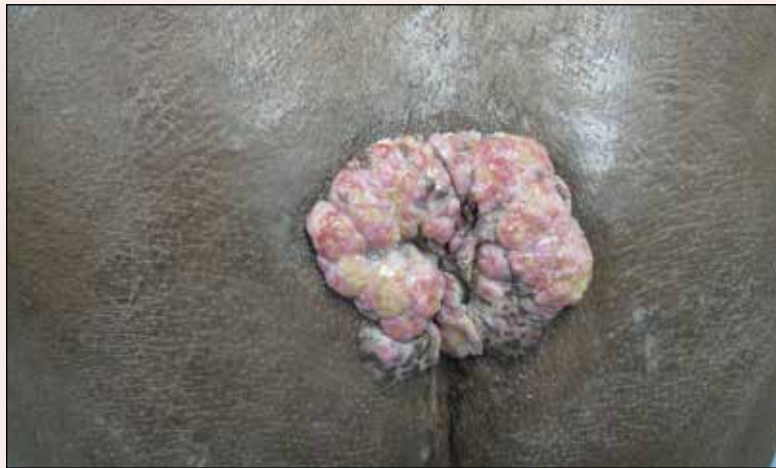

Vegetative Sacral Plaque in a Patient With Human Immunodeficiency Virus

What's the diagnosis?



A 53-year-old man presented to our clinic with a sacral mass that had progressively enlarged over 2 years. The patient reported occasional oozing from the mass as well as pain when laying flat but denied fever or other symptoms. His medical history was remarkable for human immunodeficiency virus infection with variable adherence to a highly active antiretroviral therapy regimen. At the time of presentation, the patient had a CD4 lymphocyte count of 78 cells/mm³ (reference range, 500–1400 cells/mm³) and a viral load of 290 copies/mL (reference range, 0 copies/mL). Physical examination revealed a 10-cm discrete, moist and pink, exophytic plaque on the sacrum with superficial erosions. The plaque was nontender and without associated lymphadenopathy. The skin and mucous membranes were otherwise clear. A cutaneous biopsy specimen was obtained from the tumor and sent for histopathologic analysis.

Raven I. Elosiebo, MD; Virginia A. Koubek, MD; Tejesh S. Patel, MD; M. Barry Randall, MD; Robert B. Skinner, MD

Dr. Elosiebo is from the Department of Dermatology, Indiana University, Indianapolis. Drs. Koubek, Patel, Randall, and Skinner are from the Department of Dermatology, University of Tennessee Health Sciences Center, Memphis.

The authors report no conflict of interest.

Correspondence: Virginia A. Koubek, MD, 930 Madison Ave, Ste 840, Memphis, TN 38163 (vkoubek@gmail.com).

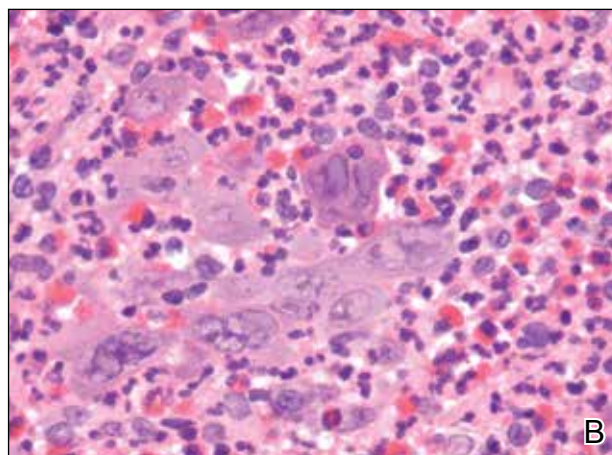
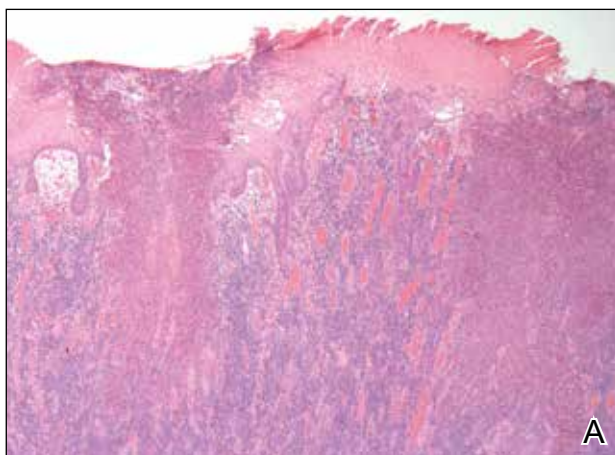
The Diagnosis: Herpes Simplex Vegetans

Histopathologic examination using hematoxylin and eosin stain demonstrated marked pseudoepitheliomatous hyperplasia with granulation tissue, ulceration, and abundant exudate joined by a dense mixed inflammatory cell infiltrate that included a myriad of eosinophils (Figure, A). At higher power (Figure, B), many single and multinucleate acantholytic keratinocytes showed ground-glass nuclei and peripheral margination of chromatin within zones of ulceration and crust. Viral culture and direct fluorescent antibody assay identified herpes simplex virus (HSV) type 2. Based on the clinical and histopathologic findings, the patient was diagnosed with herpes simplex vegetans. He was initially treated with oral acyclovir and then oral famciclovir but showed minimal improvement. Eventually, he was referred to surgery and the mass was totally excised with clear margins and no evidence of underlying malignancy.

Herpes simplex virus is one of the most common sexually transmitted infections, with a notably increased incidence and prevalence among individuals with human immunodeficiency virus (HIV) infection.¹ Although typical HSV manifestation in immunocompetent patients includes clustered vesicles and/or ulcerations, immunocompromised patients may have unusual presentations, such as

persistent and extensive ulcerations or nodular hyperkeratotic lesions.^{2,3} Herpes vegetans, a term used to describe these atypical exophytic lesions, rarely has been reported in literature, but its presence should raise suspicion for possible underlying immunocompromise. The pathogenesis behind the hypertrophic nature of these lesions is not well understood, but it is postulated that the immune dysregulation from concomitant HIV and HSV infection plays a role.² Overproduction of tumor necrosis factor and IL-6 by HIV-infected dermal dendritic cells causes an increase in antiapoptotic factors within the epidermis, resulting in enhanced keratinocyte proliferation and clinical hyperkeratosis.^{2,4}

The differential diagnosis for herpes vegetans is somewhat broad, owing to the verrucous and often eroded appearance of the lesions. Biopsy and cultures can be obtained to differentiate from condyloma acuminatum, condyloma latum (secondary syphilis), pyoderma vegetans, pemphigus vegetans, granuloma inguinale, extraintestinal Crohn disease, deep fungal infections, cutaneous tuberculosis, and malignancy.^{2,4} Histopathology shows epithelial hyperplasia and ulceration with scattered multinucleate keratinocytes, usually at the periphery of the ulcer, and intranuclear inclusions typical of HSV. In addition, a dense dermal infiltrate of lymphocytes,



Histopathology revealed marked pseudoepitheliomatous hyperplasia, ulceration, and a dense mixed inflammatory cell infiltrate (A)(H&E, original magnification $\times 20$). Many multinucleate acantholytic keratinocytes with ground-glass nuclei and peripheral margination of chromatin were shown (B)(H&E, original magnification $\times 400$).

histiocytes, plasma cells, and eosinophils is usually present beneath the base of the ulcer.^{2,4}

Treatment options for herpes vegetans are limited due to the high prevalence of acyclovir-resistant (ACV-R) HSV-2 strains in HIV patients. Valacyclovir and penciclovir have been largely ineffective against ACV-R HSV due to their dependence on the same enzyme—thymidine kinase—involved in the mechanism of acyclovir resistance. Intravenous foscarnet and cidofovir have shown efficacy against ACV-R virus, but concerns of nephrotoxicity have limited their use over prolonged intervals.⁵ Castelo-Soccio et al⁶ reported promising results with intralesional cidofovir. This route of administration provides the advantage of increased bioavailability with reduced risk for nephrotoxicity.⁶ Finally, surgical resection may be considered for refractory lesions to circumvent the toxicity from systemically administered drugs.³

REFERENCES

1. Severson JL, Tyring SK. Relation between herpes simplex viruses and human immunodeficiency virus infections. *Arch Dermatol.* 1999;135:1393-1397.
2. Patel AB, Rosen T. Herpes vegetans as a sign of HIV infection. *Dermatol Online J.* 2008;14:6.
3. Chung VQ, Parker DC, Parker SR. Surgical excision for vegetative herpes simplex virus infection. *Dermatol Surg.* 2007;33:1374-1379.
4. Beasley KL, Cooley GE, Kao GF, et al. Herpes simplex vegetans: atypical genital herpes infection in a patient with common variable immunodeficiency. *J Am Acad Dermatol.* 1997;37(5, pt 2):860-863.
5. Chilukuri S, Rosen T. Management of acyclovir-resistant herpes simplex virus. *Dermatol Clin.* 2003;21:311-320.
6. Castelo-Soccio L, Bernardin R, Stern J, et al. Successful treatment of acyclovir-resistant herpes simplex virus with intralesional cidofovir. *Arch Dermatol.* 2010;146:124-126.