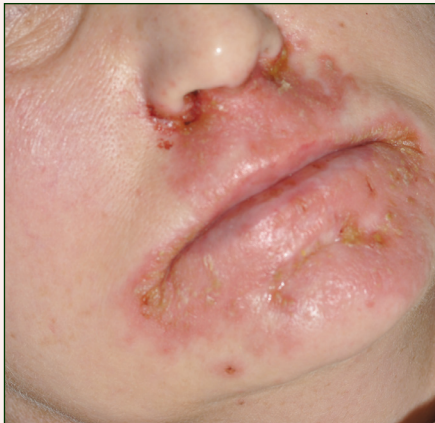

An Eruption While on Total Parenteral Nutrition

Lilly Y. Zhu, MD; Karen C. Broussard, MD; Alan S. Boyd, MD; Jennifer G. Powers, MD



A 47-year-old woman with a history of bulimia and gastroparesis who had been on total parenteral nutrition for 8 weeks presented with a painful, perioral, perineal, and acral eruption of 7 weeks' duration. Additionally, she had experienced diarrhea, vomiting, and a 13.5-kg weight loss in the last 4 months. Physical examination revealed perioral and perineal, well-demarcated, erythematous, scaly plaques with yellow crusting. She had edematous crusted erosions on the bilateral palms and soles and psoriasiform plaques along the right arm and flank. Punch biopsies (4 mm) from the right inguinal fold and right elbow were obtained.

What's the diagnosis?

- a. acquired acrodermatitis enteropathica
- b. atopic dermatitis
- c. biotin deficiency
- d. essential fatty acid deficiency
- e. hyperimmunoglobulin E syndrome

Dr. Zhu is from Vanderbilt University School of Medicine, Nashville, Tennessee. Drs. Broussard, Boyd, and Powers are from the Department of Medicine, Division of Dermatology, Vanderbilt University Medical Center. Dr. Boyd also is from the Department of Pathology.

The authors report no conflict of interest.

Correspondence: Lilly Y. Zhu, MD, 2137 Fairfax Ave #13, Nashville, TN 37212 (lilly.y.zhu@vanderbilt.edu).

The Diagnosis: Acquired Acrodermatitis Enteropathica

Acquired acrodermatitis enteropathica (AAE) is a rare disorder caused by severe zinc deficiency. Although acrodermatitis enteropathica is an autosomal-recessive disorder that typically manifests in infancy, AAE also can result from poor zinc intake, impaired absorption, or accelerated losses. There are reports of AAE in patients with zinc-deficient diets,¹ eating disorders,² bariatric and other gastrointestinal surgeries,³ malabsorptive diseases,⁴ and nephrotic syndrome.⁵

Zinc plays an important role in DNA and RNA synthesis, reactive oxygen species attenuation, and energy metabolism, allowing for proper wound healing, skin differentiation, and proliferation.⁶ Zinc is found in most foods, but animal protein contains higher concentrations (Table).⁷ Approximately 85% of zinc is stored in muscles and bones, with only a small amount of accessible zinc available in the liver. Liver stores can be depleted as quickly as 1 week.⁸ Total parenteral nutrition without trace element supplementation can quickly predispose patients to AAE.

Diagnosis of this condition requires triangulation of clinical presentation, histopathology examination, and laboratory findings. Acrodermatitis enteropathica typically is characterized by dermatitis, diarrhea, and epidermal appendage findings. In its early stages, the dermatitis often manifests with angular cheilitis and paronychia.⁹ Patients then develop erythema, erosions, and occasionally vesicles or psoriasiform plaques in periorificial, perineal, and acral sites (Figure 1). Epidermal appendage effects include generalized alopecia and thinning nails with white transverse ridges. Although dermatologic and gastrointestinal manifestations are the most obvious, severe AAE may cause other symptoms, including mental slowing, hypogonadism, and impaired immune function.⁹

Histopathology of AAE skin lesions is similar to other nutritional deficiencies. Early changes are more specific to deficiency dermatitis and include cytoplasmic pallor and ballooning degeneration of keratinocytes in the stratum spinosum and granulosum.⁹ Necrosis results in confluent keratinocyte necrosis developing into subcorneal bulla. Later in the disease course, the presentation becomes psoriasiform with keratinocyte dyskeratosis and confluent parakeratosis¹⁰ (Figure 2). Dermal edema with dilated tortuous vessels and a neutrophilic infiltrate may be present throughout disease progression.

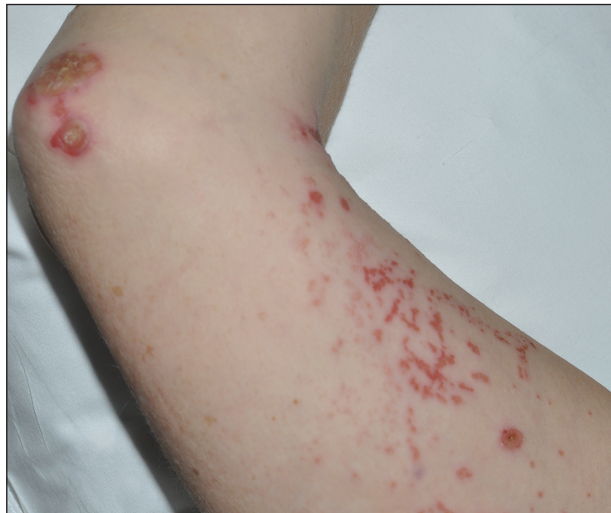

Figure 1. Psoriasiform plaques on the right arm.

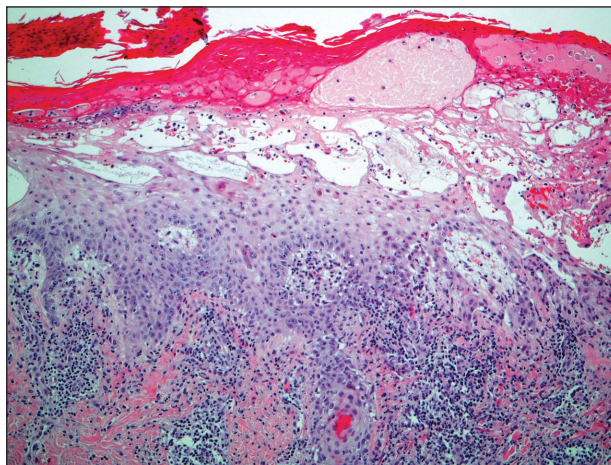


Figure 2. Parakeratosis, dyskeratotic keratinocytes, and areas of keratinocyte pallor and necrosis are noted along with infiltrating neutrophils (H&E, original magnification $\times 200$).

Common laboratory abnormalities used to confirm zinc deficiency are decreased plasma zinc and alkaline phosphatase levels. Plasma zinc levels should be drawn after fasting because zinc levels decrease after food intake.⁹ Concurrent albumin levels should be drawn to correct for low levels caused by hypoalbuminemia. Acquired acrodermatitis enteropathica has been seen in patients with only mildly decreased plasma zinc levels or even zinc levels within reference range.¹¹ Alkaline phosphatase metalloenzyme synthesis requires zinc and a decreased level suggests

Select Zinc-Rich Foods⁷

Food Item	Serving Size	Zinc Content
Oysters, farmed, raw	3 oz	32 mg
Beef chuck, braised	140 g	15 mg
Turkey breast	863 g	13 mg
Crab	1 leg	10 mg
Roasted peanuts	1 cup	9.5 mg
Roasted cashews	1 cup	7.5 mg
Swiss cheese	1 cup	6 mg
Cooked chili bean	1 cup	5 mg

zinc deficiency even with a plasma zinc level within reference range. Alkaline phosphatase levels usually can be ascertained in a matter of hours, while the zinc levels take much longer to result.

Acquired acrodermatitis enteropathica is treated with oral elemental zinc supplementation at 1 to 2 mg/kg daily.¹² Diarrhea typically resolves within 24 hours, but skin lesions heal in 1 to 2 weeks or longer. Although there is no consensus on when to discontinue zinc replacement therapy, therapy generally is not lifelong. Once the patient is zinc replete and the inciting factor has resolved, patients can discontinue supplementation without risk for recurrence.

Trace elements had not been added to our patient's total parenteral nutrition prior to admission. Basic nutrition laboratory results and zinc levels returned markedly low: 14 µg/dL (reference range, 60–120 µg/dL). Alkaline phosphatase, a zinc-dependent protein, also was low at 12 U/L (reference range, 40–150 U/L). We added trace elements and vitamins and began empiric zinc replacement with 440 mg oral zinc sulfate daily (100 mg elemental zinc). Cephalexin was prescribed for impetiginized

skin lesions. The patient noted skin improvement after 3 days on zinc replacement therapy.

REFERENCES

1. Saritha M, Gupta D, Chandrashekar L, et al. Acquired zinc deficiency in an adult female. *Indian J Dermatol.* 2012;57:492-494.
2. Kim ST, Kang JS, Baek JW, et al. Acrodermatitis enteropathica with anorexia nervosa. *J Dermatol.* 2010;37:726-729.
3. Bae-Harboe YS, Solky A, Masterpol KS. A case of acquired zinc deficiency. *Dermatol Online J.* 2012;18:1.
4. Krasovec M, Frenk E. Acrodermatitis enteropathica secondary to Crohn's disease. *Dermatol Basel Switz.* 1996;193:361-363.
5. Reichel M, Mauro TM, Ziboh VA, et al. Acrodermatitis enteropathica in a patient with the acquired immunodeficiency syndrome. *Arch Dermatol.* 1992;128:415-417.
6. Perafan-Riveros C, Franca LFS, Alves ACF, et al. Acrodermatitis enteropathica: case report and review of the literature. *Pediatr Dermatol.* 2002;19:426-431.
7. National Nutrient Database for Standard Reference, Release 28. United States Department of Agriculture, Agricultural Research Service website. <http://ndb.nal.usda.gov/ndb/nutrients/report/nutrientsfrm?max=25&offset=0&totalCount=0&nutrient1=309&nutrient2=&nutrient3=&subset=0&fg=&sort=f&measureby=m>. Accessed December 14, 2015.
8. McPherson RA, Pincus MR. *Henry's Clinical Diagnosis and Management by Laboratory Methods.* 22nd ed. Philadelphia, PA: Saunders Elsevier; 2011.
9. Mavarakis E, Fung MA, Lynch PJ, et al. Acrodermatitis enteropathica and an overview of zinc metabolism. *J Am Acad Dermatol.* 2007;56:116-124.
10. Gonzalez JR, Botet MV, Sanchez JL. The histopathology of acrodermatitis enteropathica. *Am J Dermatopathol.* 1982;4:303-311.
11. Macdonald JB, Connolly SM, DiCaudo DJ. Think zinc deficiency: acquired acrodermatitis enteropathica due to poor diet and common medications. *Arch Dermatol.* 2012;148:961-963.
12. Kumar P, Lal NR, Mondal A, et al. Zinc and skin: a brief summary. *Dermatol Online J.* 2012;18:1.