

## > THE PATIENT

76-year-old man

## > SIGNS & SYMPTOMS

- Fever
- Eschars on right leg and groin
- Inguinal lymphadenopathy

**Poonam Mathur, DO;**  
**Shenil Shah, MD;**  
**Michael Beck, MD**  
University of Maryland  
Medical Center,  
Baltimore (Dr. Mathur);  
Department of Internal  
Medicine (Drs. Shah and  
Beck) and Department  
of Pediatrics (Dr. Beck),  
The Pennsylvania State  
University College of  
Medicine, Hershey

poonammathur@  
umm.edu

The authors reported no  
potential conflict of interest  
relevant to this article.

## > THE CASE

A 76-year-old man with a history of coronary artery disease presented with a fever, headache, and malaise one week after returning from a big game hunting trip in South Africa. Five days after his return, he noticed lesions on his right leg that eventually scabbed over. He sought care at his local emergency department and with his primary care physician, and completed an empiric trial of azithromycin. His symptoms, however, persisted and he was referred to our institution for evaluation and treatment.

On exam, he had a temperature of 100.5° F, inguinal lymphadenopathy, and 2 eschars: a 1.5 cm one on his right groin and an identical one on the medial aspect of the right popliteal fossa (FIGURE 1).

## THE DIAGNOSIS

Laboratory studies showed a white blood cell count of 3000/mcL, hemoglobin of 14.1 g/dL, and platelet count of 142,000/mcL; peripheral blood smear was normal. Blood and urine cultures showed no growth. A malaria smear and antibodies for Lyme disease, dengue fever, Chikungunya virus, and Q fever were also negative. A biopsy of the eschar demonstrated epidermal and dermal necrosis consistent with infectious vasculitis caused by rickettsial disease (FIGURE 2). A polymerase chain reaction (PCR) for the spotted fever group (*R rickettsii*, *R akari*, and *R conorii*) and typhus fever group of rickettsial agents (*R typhi* and *R prowazekii*) were negative. However, a PCR was positive for *R africae*, confirming the diagnosis of African tick-bite fever (ATBF).

FIGURE 1

A characteristic inoculation eschar  
in the patient's popliteal fossa

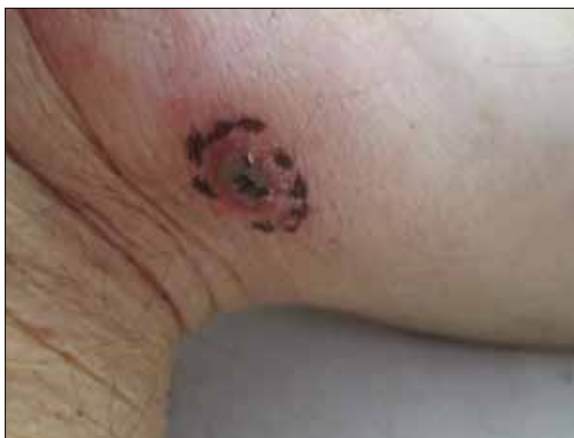

PHOTO COURTESY OF: MICHAEL BECK, MD

## DISCUSSION

Two common reasons patients returning from international travel seek medical attention are fever and rash.<sup>1</sup> Initial assessment should include a detailed travel history of urban and rural exposures and any possible exposure to ticks or fleas. The time course of symptoms is important because some tropical infections can have long incubation periods.<sup>2</sup>

Rickettsial diseases are the most common febrile illness in patients returning from international travel.<sup>1</sup> ATBF caused by *R africae* is the most common rickettsiosis among returning travelers<sup>1</sup> and may be the most widespread of all spotted fever group rickettsiae that are known to be

pathogenic to humans.<sup>3</sup> *R africae* is endemic to South Africa. The risk of contracting *R africae* is 4 to 5 times higher than the risk of contracting malaria in South Africa.<sup>1</sup>

*R africae* is transmitted through cattle and game ticks (*Amblyomma* species),<sup>1-7</sup> and tends to cause mild illness with rare progression to complicated disease.<sup>3</sup> The risk of infection is particularly high from November to April,<sup>7</sup> and our patient had traveled during April.

Most patients with ATBF present with fever, headache, and malaise, and 50% develop a variable rash.<sup>1,2</sup> Local lymphadenopathy often develops, and marked neck stiffness can occur.<sup>2</sup> An eschar is present in 95% of cases.<sup>2</sup> The finding of an eschar is often indicative of rickettsial infection; however, not all rickettsioses show eschars, and the absence of an eschar does not exclude rickettsial infection.<sup>1</sup>

ATBF is usually benign and self-limiting, and no fatalities have been reported.<sup>2,4,8</sup> Complications such as peripheral nerve involvement, encephalitis, and myocarditis are rare.<sup>5,8</sup> Since rickettsial diseases may be more severe in elderly patients with underlying diseases, empiric treatment with inpatient monitoring is justifiable.<sup>5</sup>

**Don't wait for lab confirmation to begin antibiotics**

Laboratory findings in a patient with ATBF include pancytopenia, elevated serum C-reactive protein, and abnormal liver function tests.<sup>2,4</sup> A blood PCR detects *R africae*,<sup>1,3</sup> and if a rash or eschar is present, a biopsy can confirm the diagnosis.<sup>1</sup> However, confirming the diagnosis is difficult if seroconversion has not occurred and PCR is not readily available.<sup>1</sup> Also, antibodies may not be detected in patients who have a mild case of ATBF or those who are immunocompromised.<sup>5</sup>

If you suspect your patient has ATBF, don't wait for laboratory confirmation; instead, initiate empiric treatment with doxycycline 100 mg bid twice daily for 5 to 7 days.<sup>1,2,4</sup>

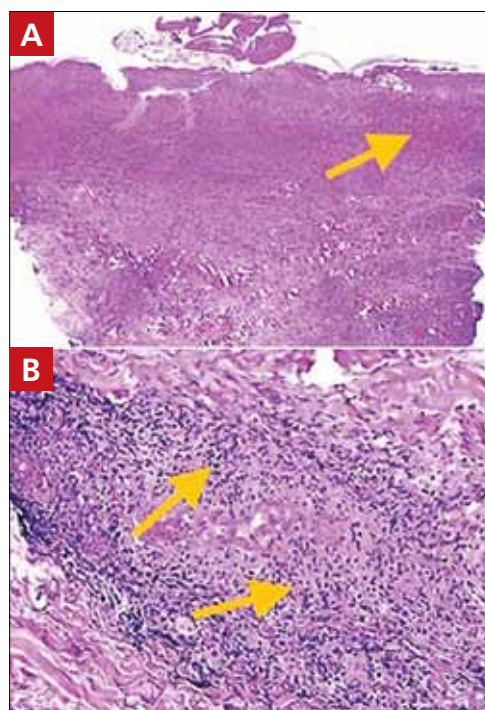
**Preventive measures include repellent lotions, clothing, and gear**

Since there are no vaccines or prophylactic treatments for ATBF, counsel travelers on

preventive measures.<sup>9</sup> Instruct patients who plan to visit an endemic area such as sub-Saharan Africa or the West Indies to wear long-sleeved shirts, long pants, and hats. Individuals should also tuck their shirts into their pants and their pants into socks, as well as wear closed-toe shoes. When possible, it's advisable to avoid woody and brushy areas.

Over-the-counter repellent lotions that contain ≥20% DEET are effective at preventing tick bites for several hours after an application, but should be reapplied as directed.<sup>9</sup> These lotions should be applied after sunscreen. Advise patients that they can purchase clothing and gear that have been treated with the pesticide permethrin, or they can treat clothing and gear themselves. Explain, however, that permethrin should not be applied directly to skin.

**FIGURE 2**  
H&E stain shows necrosis and vascular destruction



The hematoxylin and eosin (H&E) stain of the upper one-third of the dermis at 40x magnification (A) revealed necrosis. 200x magnification showed vascular destruction with perivascular infiltrate of lymphocytes and numerous histiocytes (B).

PHOTOS COURTESY OF HERSHEY MEDICAL CENTER, DEPARTMENT OF PATHOLOGY

➤ The risk of contracting *R africae* is 4 to 5 times higher than the risk of contracting malaria in South Africa.

CONTINUED

Finally, instruct travelers to perform daily tick inspections and shower or bathe as soon as possible after returning from the outdoors.<sup>9</sup> Educate patients on the proper technique for tick removal, which is described on the Centers for Disease Control and Prevention's Web site at [http://www.cdc.gov/ticks/removing\\_a\\_tick.html](http://www.cdc.gov/ticks/removing_a_tick.html).

■ **Our patient** completed a 2-week course of doxycycline 100 mg bid. His symptoms and laboratory abnormalities completely resolved.

## THE TAKEAWAY

ATBF is the most common rickettsiosis

among patients returning from international travel. Because patients may present with several nonspecific symptoms, maintain a high index of suspicion for rickettsial infection among patients returning from sub-Saharan Africa or the West Indies. Though the disease usually can be successfully managed in the outpatient setting with doxycycline, elderly patients or those with comorbid conditions may require inpatient care. Educate patients who plan to travel to an endemic area about measures they can take to prevent exposure to ticks and subsequent infection. **JFP**

## References

1. Neumayr A, Hatz C, Blum J. Not to be missed! Differential diagnoses of common dermatological problems in returning travellers. *Travel Med Infect Dis.* 2013;11:337-349.
2. Yates J, Smith P. Fever and rash. *Medicine.* 2014;42:96-99.
3. Jensenius M, Fournier PE, Kelly P, et al. African tick bite fever. *Lancet Infect Dis.* 2003;3:557-564.
4. Frean J, Blumberg L, Ogunbanjo GA. Tick bite fever in South Africa. *S Afr Fam Pract.* 2008;50:33-35.
5. Roch N, Epaulard O, Pelloux I, et al. African tick bite fever in elderly patients: 8 cases in French tourists returning from South Africa. *Clin Infect Dis.* 2008;47:e28-e35.
6. Caruso G, Zasio C, Guzzo F, et al. Outbreak of African tick-bite fever in six Italian tourists returning from South Africa. *Eur J Clin Microbiol Infect Dis.* 2002;21:133-136.
7. Tsai YS, Wu YH, Kao PT, et al. African tick bite fever. *J Formos Med Assoc.* 2008;107:73-76.
8. Jensenius M, Fournier PE, Fladby T, et al. Sub-acute neuropathy in patients with African tick bite fever. *Scand J Infect Dis.* 2006;38:114-118.
9. Centers for Disease Control and Prevention. African tick-bite fever. Centers for Disease Control and Prevention Web site. Available at: <http://wwwnc.cdc.gov/travel/diseases/african-tick-bite-fever>. Accessed September 24, 2015.

NOW ONLINE AT [WWW.JFPONLINE.COM](http://WWW.JFPONLINE.COM)

A supplement to The Journal of Family Practice

# Major Depressive Disorder in the Primary Care Setting

## STRATEGIES TO ACHIEVE REMISSION AND RECOVERY

### Faculty

**BRADLEY N. GAYNES, MD, MPH**  
**W. CLAY JACKSON, MD, DipTb**  
**KASHEMI D. RORIE, PhD**

1.25 CME CREDITS AVAILABLE

### Discussion includes:

- Diagnosis of depression in the primary care setting
- Treatment of depression
- Measurement-based care for major depressive disorder

