

# Aleukemic acute lymphoblastic leukemia with unusual clinical features

Ashutossh Naaraayan, MD;<sup>a</sup> Prakriti Bista, MD;<sup>a</sup> Abhishek Nimkar, MBBS;<sup>b</sup> Ian Hantman, MD;<sup>a</sup> Gordana L Katava, DO, MS;<sup>c</sup> Prasanta Basak, MD, FACP;<sup>a</sup> and Stephen Jesmajian, MD, FACP<sup>a</sup>

<sup>a</sup>Department of Medicine, Montefiore New Rochelle Hospital, Albert Einstein College of Medicine, New Rochelle, New York; <sup>b</sup>Charak Palika Hospital, New Delhi, India; and <sup>c</sup>Department of Pathology, Montefiore Medical Center, Albert Einstein College of Medicine, Bronx, New York

**A**cute lymphoblastic leukemia (ALL) is a neoplastic proliferation of lymphoblasts in the bone marrow. Normal hematopoiesis is affected, and symptoms from anemia (fatigue, breathlessness), leukopenia (recurrent infections) or thrombocytopenia (easy bruising, mucosal bleeding) are typically described in ALL. Hepatosplenomegaly and B-symptoms (fever, weight loss, and night sweats) are frequently seen.

Presence of lymphoblasts in the peripheral smear is indicative of ALL, and a bone marrow biopsy finding of >25% lymphoblasts is confirmatory. Absence of peripheral lymphoblasts in a patient with acute leukemia is known as aleukemic leukemia. Aleukemic leukemia is uncommon, and most cases have described skin lesions from lymphoblast infiltration (leukemia cutis) in addition to bone marrow involvement.<sup>1</sup>

We report a case of aleukemic ALL in an adult presenting with unusual clinical features including bone pain, osteolytic lesions, hypercalcemia, and normal blood counts. To our knowledge, this is fifth such case ever reported in an adult patient.

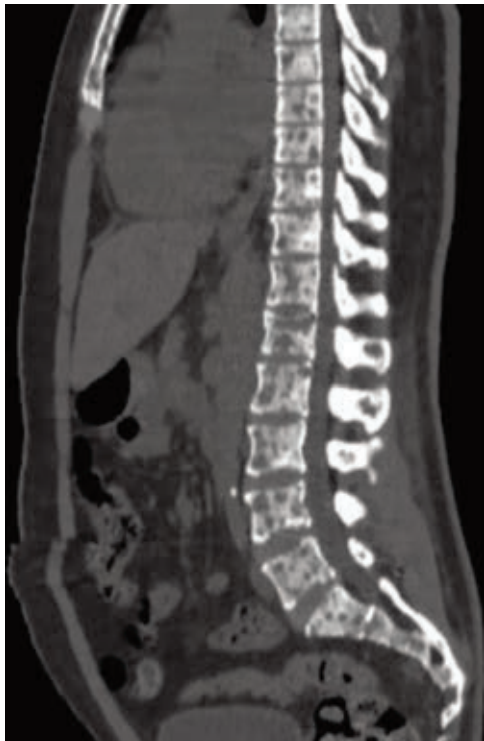## Case presentation and summary

A 29-year-old man presented to the emergency department with progressive nausea, vomiting, fatigue, and pain in the right upper back and right hip. He had been experiencing the symptoms for about 2 weeks. There was no history of recent trauma. A week before the current presentation, he had been admitted with similar complaints to a different hospital, but had left against medical advice. A review of his symptoms revealed the presence of night sweats and subjective weight

loss in the preceding months. The patient's medical history included paraplegia secondary to a spinal gun-shot wound, hypertension, hyperlipidemia, and diabetes. His home medications were aspirin 81 mg daily, baclofen 5 mg daily, insulin isophane/regular (70/30) 33 units in the morning and 15 units in the evening, oxycodone-acetaminophen 5-325 mg 3 times daily as needed, simvastatin 20 mg daily, and lactulose 20 grams daily. There was no family history of cancer.

Vital signs recorded in the emergency department were: temperature, 97.6°F; blood pressure, 123/75 mmHg (120/80 – 140/90 mmHg); heart rate, 77 beats/min (60-100 beats/min); and respiratory rate, 16 breaths/minute (12-16 breaths/min). Physical examination revealed tenderness over the right posterior thorax, no hepatosplenomegaly or lymphadenopathy. The genital examination was normal. Laboratory data revealed hemoglobin, 11.9 g/dL (13.5-17.5 g/dL); white blood cell count, 6,100 cells/dL with 67% neutrophils, 25 % lymphocytes (4,000-11,000 cells/dL); platelets, 128,000 cells/dL (150,000-400,000 cells/dL); blood urea nitrogen, 17 mg/dL (9-21 mg/dL); serum creatinine, 2.09 mg/dL (0.50-1.20 mg/dL); serum calcium, 13.8 mg/dL (8.4-10.2 mg/dL); and uric acid, 11 mg/dL (2.3-7.5 mg/dL). A bone scan from the previous hospitalization showed an increased uptake of radiotracer material throughout the axial and appendicular skeleton. A computed-tomographic scan of the chest, abdomen, and pelvis revealed innumerable, punched-out, osteolytic lesions in the axial skeleton and the extremities (Figure 1). Pathologic fractures of multiple ribs as well as an impending fracture of the right femoral neck were reported. Prostate-specific

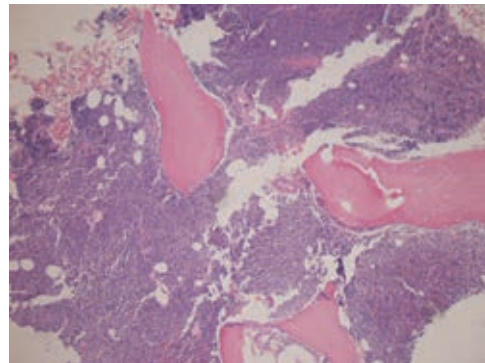
Accepted for publication September 8, 2015. Correspondence: Ashutossh Naaraayan, MD; ashu.newroc@gmail.com. Disclosures: The authors have no conflicts of interest or financial disclosures to report. JCSO 2016;14:323-325. ©2016 Frontline Medical Communications. doi 10.12788/jcso.0217.



**FIGURE 1** Computed-tomographic scan of the sagittal section view of the chest, abdomen, and pelvis showing innumerable osteolytic lesions in the vertebral bodies.

antigen, beta-human chorionic gonadotropin, alpha-feto-protein, lactate dehydrogenase, and thyroid function tests were nonrevealing.

The patient's 25-hydroxy and parathyroid hormone levels (12 ng/ml [30-100 ng/ml] and 2 pg/ml [12-88 pg/ml], respectively) were low, consistent with hypercalcemia of malignancy. Serum protein electrophoresis revealed a total protein of 6.0 gm/dL (6.1-8.1 gm/dL) with albumin of 3.11 gm/dL (3.50-4.70 gm/dL) and normal levels of globulins as follow: alpha 1 globulin 0.25 gm/dL (0.10-0.30 gm/dL), alpha 2 globulin 0.74 gm/dL (0.50-1 gm/dL), beta globulin 1.03 gm/dL (0.8-1.40 gm/dL), gamma globulin 0.85 gm/dL (0.60-1.60 gm/dL). M-spike was not detected. Urine protein electrophoresis revealed total urine protein of 131 mg/g and creatinine 22-128 mg/g, with albumin 48.2% and an albumin-to-globulin ratio of 0.93 (0.8-2.0). Monoclonal proteins were not detected on immunofixation of urine and serum. Hypercalcemia was treated with intravenous fluids. A subsequent bone marrow biopsy revealed a hypercellular marrow diffusely infiltrated by CD19-positive lymphoblasts consistent with B-cell ALL (Figure 2). The patient received chemotherapy for ALL and eventually succumbed to progressive leukemia a year later.



**FIGURE 2** Bone marrow biopsy at 40x showing a hypercellular marrow (90%-100% cellularity) diffusely infiltrated by blasts consistent with B-cell acute lymphoblastic leukemia.

## Discussion

Osteolytic lesions can be seen in various hematological malignancies. Osteolysis with hypercalcemia is commonly seen in multiple myeloma and T-cell lymphoma/leukemia.<sup>2</sup> Non-Hodgkin lymphoma, Hodgkin lymphoma, hairy-cell leukemia, and Waldenstrom macroglobulinemia can present with osteolysis as well.<sup>3</sup> Among myeloid malignancies, osteolytic lesions have been reported in the chronic phase, during blast transformation in chronic myelogenous leukemia, and in rare cases, in acute myelogenous leukemia.<sup>4,5</sup> In children presenting with ALL, bone and joint pains are common.<sup>6,7</sup> Skeletal findings in these children include osteopenia, metaphysiscal radiolucencies, and periosteal elevation, whereas osteolysis is rare.<sup>6,8</sup> In contrast, bone and joint pains are seldom reported by adults with ALL. Although osteolytic lesions can be found in ALL patients during the course of their illness, it is rarely reported as the initial presentation in either adults or children.<sup>7</sup>

Hypercalcemia is seen in about 2%-3% of ALL patients. Hypercalcemia is more common in adult solid malignancies. It is either caused by local bone involvement (eg, breast or lung cancer) or mediated by humoral factors (eg, parathyroid hormone-related peptide [PTHrP], parathyroid hormone, interleukin-6 and vitamin D).<sup>9</sup> The receptor activators of nuclear factor kappa-B ligand and macrophage inflammatory protein-1 alpha have been linked to PTHrP secretion and hypercalcemia in acute T-cell leukemia.<sup>9</sup> PTHrP and the E2A-HLF fusion protein from genetic translocation t(17;19) in the lymphoblastic cells have been associated with hypercalcemia in children with ALL.<sup>10</sup>

The classic presenting manifestation of aleukemic leukemia is leukemia cutis, which was not present in our patient.

Our case presented with a number of unique clinical manifestations. As already described herein, osteolytic lesions, hypercalcemia, normal blood counts, and aleuke-

mic picture at presentation are rarely seen by themselves in ALL, let alone all at the same time. As far as we know, this symptom complex described occasionally in adolescents is even rarer in adult ALL patients, with only 4 cases identified as of September 2015 through a Medline-Pubmed search.<sup>11-14</sup>

Notably, children or adolescents with ALL presenting with osteolytic lesions and hypercalcemia have a lower leukemic cell burden, hence the aleukemic picture.<sup>9,15</sup> Association of this clinical picture with t(17;19) is intriguing and warrants further evaluation.<sup>10</sup> Of note is that t(17;19) and not hypercalcemia alone has been linked to poor outcomes in ALL patients.

## References

- Zengin N, Kars A, Ozişik Y, Canpınar H, Türker A, Ruacan S. Aleukemic leukemia cutis in a patient with acute lymphoblastic leukemia. *J Am Acad Dermatol*. 1998;38:620-621.
- Roodman GD. Mechanisms of bone lesions in multiple myeloma and lymphoma. *Cancer*. 1997;80:1557-1563.
- Rossi JF, Bataille R, Chappard D, Alexandre C, Janbon C. B cell malignancies presenting with unusual bone involvement and mimicking multiple myeloma. Study of nine cases. *Am J Med*. 1987;83:10-16.
- Kubota K, Yanagisawa T, Kurabayashi H, et al. Hypercalcemia associated with osteolytic lesions in the extramedullary blast crisis of chronic myelogenous leukemia: report of a case. *Blut*. 1989;59:458-459.
- Johnson JL, Moscinski L, Zuckerman K. Value of positron emission tomography scan in staging cancers, and an unusual presentation of acute myeloid leukemia. Case 3. Acute myeloid leukemia presenting with lytic bone lesions. *J Clin Oncol*. 2004;22:2968-2970.
- Case records of the Massachusetts General Hospital. Weekly clinicopathological exercises. Case 32-2000. A boy with vertebral compression fractures. *N Engl J Med*. 2000;343:1168-1176.
- Mohanty PK, Patel DK, Majhi CD, Nanda R, Rout BK, Guhathakurta S. Aleukemic acute lymphoblastic leukemia in adult presenting with rheumatic manifestations and osteolytic vertebral lesions. *J Indian Rheumatol Assoc* 2004;12:150-152.
- Bhat GM. A child with acute lymphoblastic leukemia (ALL) presenting with symptomatic hypercalcemia and multiple osteolytic lesions. *Indian J Med Pediatr Oncol*. 2007;28:46-47.
- Shimonodan H, Nagayama J, Nagatoshi Y, et al. Acute lymphocytic leukemia in adolescence with multiple osteolytic lesions and hypercalcemia mediated by lymphoblast-producing parathyroid hormone-related peptide: a case report and review of the literature. *Pediatr Blood Cancer* 2005;45:333-339.
- Inukai T, Hirose K, Inaba T, et al. Hypercalcemia in childhood acute lymphoblastic leukemia: frequent implication of parathyroid hormone-related peptide and E2A-HLF from translocation 17;19. *Leukemia* 2007;21:288-296.
- Stein A, Boughton BJ. Common acute lymphoblastic leukaemia in an adult with hypercalcaemia and lytic bone lesions. *Br J Haematol* 1988;70:503.
- Mori A, Toyoshima N, Saito M, Oka T, Irie T, Morioka M. Hypercalcemia and multiple osteolytic lesions associated with proinflammatory cytokines in a patient with acute lymphoblastic leukemia [in Japanese]. *Rinsho Ketsueki* 2007;48:559-564.
- Chung SW, Kim S, Choi JR, Yoo TH, Cha IH. Osteolytic mandible presenting as an initial manifestation of an adult acute lymphoblastic leukaemia. *Int J Oral Maxillofac Surg*. 2011;40(12):1438-1440.
- Verma SP, Dubashi B, Basu D, Dutta TK, Kar R. A rare case of adult acute lymphoblastic leukemia presenting with paraparesis and multiple osteolytic lesions. *Indian J Hematol Blood Transfusion*. 2014;30:24-26.
- Lee YH, Lim YJ, Bae JJ, Kim JY, Shin JH. Hypercalcemia and extensive osteolytic lesion with increased plasma prostaglandin E<sub>2</sub> level in a child with acute lymphoblastic leukemia. *Korean J Hematol*. 2007;42:433-438.

## Conclusion

To our knowledge, the combination of osteolysis, hypercalcemia, and aleukemic leukemia is very rare, and we believe it may represent an undiscovered unique genetic abnormality. Leukemia is primarily a disease of the hematopoietic system, and there may or may not be an outpouring of excess lymphoblasts into the peripheral blood. This case alerts physicians to be highly suspicious when encountering multiple myeloma and metastatic solid tumors, and to keep the rare possibility of ALL in mind when unexplained osteolytic lesions with hypercalcemia are encountered. Early bone marrow evaluation in aleukemic ALL can confirm the diagnosis and guide treatment.