



# Pessaries for vaginal prolapse: Critical factors to successful fit and continued use

↘ *A successfully inserted vaginal pessary can improve voiding, urgency, and incontinence for women with urinary incontinence and pelvic organ prolapse, no matter the stage. We encourage you to offer and use this low-cost, minimally invasive approach. More than half of women with prolapse may use a pessary for up to 2 years.*

**Teresa Tam, MD, and Matthew Davies, MD**

## IN THIS ARTICLE

**Pessary indications  
and options**  
page 43

**Essential  
components of  
successful fit**  
page 50

**Outcomes**  
page 59

### **CASE 1** Early-stage pelvic organ prolapse

AC is a 64-year-old white woman with early stage III anterior and apical pelvic organ prolapse (POP). The prolapse is now affecting her ability to do some of the things that she enjoys, such as gardening and golfing.

She has hypertension controlled with medication and no other significant medical issues except mild arthritic changes in her hands and hips. She reports being sexually

active with her husband on roughly a weekly basis.

On examination, the leading edge of her prolapse is the anterior vaginal wall, protruding 1 cm beyond the introitus, and the cervix is at the hymenal ring. There is no significant posterior wall prolapse.

After she is counseled about all possible treatment approaches for her early-stage POP, the patient elects to try the vaginal pessary. Now, it is your job to determine the optimal pessary based on the extent of her condition and to educate her about the potential side effects and best practices for its ongoing use.

Dr. Tam is a graduated Fellow in the Division of Urogynecology and Minimally Invasive Gynecologic Surgery, Department of Obstetrics and Gynecology, Penn State Milton S. Hershey Medical Center. She is currently in private practice at All for Women's Healthcare in Chicago, Illinois.


Dr. Davies is Division Chief, Urogynecology and Minimally Invasive Gynecologic Surgery, Department of Obstetrics and Gynecology, at Penn State Milton S. Hershey Medical Center, Penn State College of Medicine, Hershey, Pennsylvania.

*Dr. Tam reports that she has received a grant or research support from Ethicon BioSurgery and is a speaker for Merck Pharmaceuticals.*

*Dr. Davies reports that he is a consultant to Boston Scientific and a speaker for Ethicon Endosurgical and Boston Scientific.*

The vaginal pessary is an important component of a gynecologist's armamentarium. It is a low-risk, cost-effective, nonsurgical treatment option for the management of POP and genuine stress urinary incontinence (SUI).<sup>1,2</sup> It is unfortunate that training in North America typically provides clinicians with only a cursory experience with pessary selection and care, minimizing the device's importance as a viable

## ON THE WEB

 **Dr. Tam demonstrates proper insertion and removal techniques, at [obgmanagement.com](http://obgmanagement.com)**

tool in a practitioner's ongoing practice. In fact, most clinicians tend to view the pessary with a mixture of reluctance and disregard.

This is regrettable, as a majority (89%) of patients can be successfully fitted with a pessary,<sup>3</sup> regardless of their stage or site of prolapse.<sup>4</sup> Although high-stage prolapse does not predict failure, ring pessaries are used most successfully with stage II (100%) and stage III (71%) prolapse, while Gellhorn pessaries are most successful with stage IV (64%) prolapse.<sup>5</sup>

In this article we review the several pessary options available to clinicians, as well as how to insert them and the best scenarios for their use. We also discuss the key requirements for patient assessment and in-office fitting (meant to optimize the fit and, thereby, the success of use), the possible side effects of pessary use that patients need to be aware of, and appropriate follow-up.

## When is a pessary your best management approach?

There are several **indications** for pessary use,<sup>6</sup> namely when:

- the patient has significant comorbid risk factors for surgery
- the patient prefers a nonsurgical alternative
- a goal is to avoid reoperation
- POP or cervical insufficiency is present during pregnancy
- the patient desires future fertility
- surgery must be delayed due to treatment of vaginal ulcerations
- the pessary will be used as a postoperative adjunct to mesh-based repair.

Pessaries have very few contraindications (**TABLE**). However, factors that do negatively affect successful fitting include:

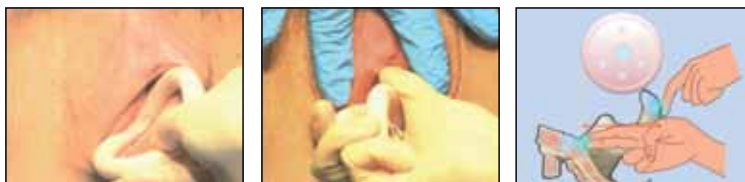- prior pelvic surgery
- multiparity
- obesity
- SUI
- short vaginal length (<7 cm)
- wide vaginal introitus (>4 fingerbreadths)
- significant posterior vaginal wall defect.<sup>5,7-9</sup>

There are two main categories of vaginal pessaries: support and space-filling. All

## Vaginal pessaries: An instructional video

Written and narrated by Teresa Tam, MD

In this 15-minute video Dr. Tam demonstrates insertion and removal of the ring and Gellhorn pessaries and illustrates proper technique for estimating pessary size.



Use this QR code to download the video to your Smartphone, or go to [obgmanagement.com](http://obgmanagement.com). Free QR readers are available at iPhone App Store, Android Market, and Blackberry App World.

© Dr. Teresa Tam

pessaries come in different sizes and shapes. Most are made of medical-grade silicone, rendering them durable and autoclavable as well as resistant to absorption of vaginal discharge and odors. The ring pessary with support is the most commonly used support pessary. The Gellhorn pessary is the most commonly used space-filling pessary. It is used as a second-line treatment for patients unable to retain the ring-with-support pessary.

## Support pessary options


The support pessaries are used to treat SUI and POP. These pessaries typically are the

## Contraindications to pessary use

- **Active infection of the pelvis or vagina.** Treatment and resolution of the infection are advisable prior to pessary fitting and use.
- **Latex allergy.** Although most pessaries are made of silicone, the Inflatoball is made of latex, so insertion of this pessary is contraindicated in patients allergic to latex.
- **Medical or social factors** predisposing the patient to nonadherence and pessary neglect.
- **Vaginal mesh erosion.** The foreign body should be removed prior to pessary placement.



**FIGURE 1**



Ring pessary (A), and ring pessary with support (B)

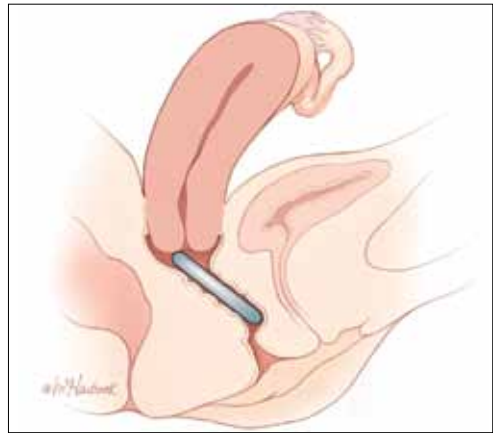
easiest types for patients to use because they are more comfortable and simpler to remove and insert than space-filling pessaries. For example, a ring pessary is two-dimensional and lies perpendicular to the long axis of the vagina, allowing patients to have intercourse with it in place. Support-type pessaries include the ring, Gehrung, Shaatz, and lever.

### Ring

This is the most commonly used pessary because it fits most women. There are four types of ring pessaries: the ring (FIGURE 1A), ring with support (FIGURE 1B), incontinence ring, and incontinence ring with support. The ring pessary is appropriate for all stages of POP. The ring with support has a diaphragm that is useful in women who have uterine prolapse with or without cystocele. The incontinence ring has a knob that is placed beneath the urethra to increase urethral pressure and is useful in cases of SUI.

**Insertion.** Fold the pessary by bringing the two small holes together, and lubricate the leading edge. Insert it past the introitus with the folded edge facing down. Allow the

**FIGURE 2**



With the patient in a horizontal position, the ring pessary is placed behind the cervix, into the posterior fornix


pessary to reopen, and direct it behind the cervix into the posterior fornix (FIGURE 2). Give it a slight twist with your index finger to prevent expulsion (see **Vaginal pessaries: An instructional video**, on page 43).

### Gehrung

This pessary is designed with an arch-shaped malleable rim with wires incorporated into the arms (FIGURE 3). Use of the Gehrung pessary is rare; it is most often used in women with cystocele or rectocele.

**Insertion.** Fold the pessary to insert it into the vagina. Upon insertion, keep both heels of the pessary parallel to the posterior vagina with the back arch pushed over the cervix in the anterior fornix and the front arch resting behind the symphysis pubis. The concave

**FIGURE 3**



Gehrung pessary (A) with knob (B)

**FIGURE 4**



Shaatz pessary

### FAST TRACK

The ring pessary, the moset commonly used pessary, is appropriate for all stages of pelvic organ prolapse

ILLUSTRATION: MARCIA HARTSOCK FOR OBG MANAGEMENT. PHOTOS: COURTESY OF ©COOPERSURGICAL, EXCEPT WHERE NOTED.



**Human immunodeficiency virus (HIV)/Hepatitis C virus (HCV) protease inhibitors and non-nucleoside reverse transcriptase inhibitors:** Significant changes (increase or decrease) in the plasma concentrations of estrogen and progesterone have been noted in some cases of co-administration with HIV/HCV protease inhibitors or with non-nucleoside reverse transcriptase inhibitors.

**Antibiotics:** There have been reports of pregnancy while taking hormonal contraceptives and antibiotics, but clinical pharmacokinetic studies have not shown consistent effects of antibiotics on plasma concentrations of synthetic steroids.

#### 7.2 Effects of Combined Oral Contraceptives on Other Drugs

COCs containing EE may inhibit the metabolism of other compounds. COCs have been shown to significantly decrease plasma concentrations of lamotrigine, likely due to induction of lamotrigine glucuronidation. This may reduce seizure control; therefore, dosage adjustments of lamotrigine may be necessary.

Women on thyroid hormone replacement therapy may need increased doses of thyroid hormone because serum concentration of thyroid-binding globulin increases with use of COCs.

#### 7.3 Interference with Laboratory Tests

The use of contraceptive steroids may influence the results of certain laboratory tests, such as coagulation factors, lipids, glucose tolerance, and binding proteins.

### 8 USE IN SPECIFIC POPULATIONS

#### 8.1 Pregnancy

There is little or no increased risk of birth defects in women who inadvertently use COCs during early pregnancy. Epidemiologic studies and meta-analyses have not found an increased risk of genital or non-genital birth defects (including cardiac anomalies and limb-reduction defects) following exposure to low dose COCs prior to conception or during early pregnancy.

The administration of COCs to induce withdrawal bleeding should not be used as a test for pregnancy. COCs should not be used during pregnancy to treat threatened or habitual abortion.

#### 8.3 Nursing Mothers

When possible, advise the nursing mother to use other forms of contraception until she has weaned her child. COCs can reduce milk production in breastfeeding mothers. This is less likely to occur once breastfeeding is well established; however, it can occur at any time in some women. Small amounts of oral contraceptive steroids and/or metabolites are present in breast milk.

#### 8.4 Pediatric Use

Safety and efficacy of Quartette have been established in women of reproductive age. Efficacy is expected to be the same for postpubertal adolescents under the age of 18 as for users 18 years and older. Use of Quartette before menarche is not indicated.

#### 8.5 Geriatric Use

Quartette has not been studied in women who have reached menopause and is not indicated in this population.

#### 8.6 Hepatic Impairment

No studies have been conducted to evaluate the effect of hepatic impairment on the disposition of Quartette. However, steroid hormones may be poorly metabolized in patients with hepatic impairment. Acute or chronic disturbances of liver function may necessitate the discontinuation of COC use until markers of liver function return to normal and COC causation has been excluded. [See *Contraindications (4)* and *Warnings and Precautions (5.2)*]

#### 8.7 Renal Impairment

No studies have been conducted to evaluate the effect of renal impairment on the disposition of Quartette.

### 10 OVERDOSAGE

There have been no reports of serious ill effects from overdose of oral contraceptives, including ingestion by children. Overdosage may cause withdrawal bleeding in females and nausea.



Manufactured by:

Teva Women's Health, Inc.

Subsidiary of TEVA PHARMACEUTICALS USA, Inc.

Sellersville, PA 18960

Quartette™ is a trademark of Teva Women's Health, Inc.

©2013 Teva Women's Health, Inc.

This brief summary is based on Quartette™ full Prescribing Information, Iss. 3/2013.

QUA-40103

surface and diaphragm support the anterior vagina. Place the convex portion of the curve beneath the bulge. The two bases rest on the posterior vagina against the lateral levator muscles.

#### Shatz

This support pessary has a circular base similar to the Gellhorn pessary but without the rigid stem (FIGURE 4, page 44).

**Insertion.** Because it is stiff, insert this pessary vertically and then turn it to a horizontal position once it is inside the vagina.

#### Lever

The Hodge, Smith, and Risser pessaries are collectively called the lever pessaries. They are used to manage uterine retroversion and POP. They are rarely used.

The Hodge pessary is beneficial to patients with a narrow vaginal introitus, mild cystocele, and cervical insufficiency. The anterior portion of a Hodge pessary is rectangular (FIGURE 5A).

The Smith pessary is useful for patients with well-defined pubic notches because the anterior portion is rounded (FIGURE 5B).

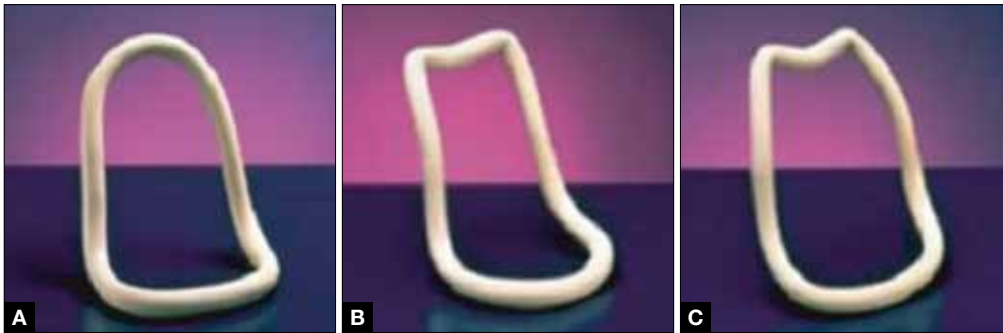
For patients with a very shallow pubic notch, the Risser pessary is useful. The Risser's anterior portion is rectangular with indentation but wider than the Hodge pessary (FIGURE 5C).

**Insertion.** Fold the pessary and insert it into the vagina with the index finger on the posterior curved bar until the pessary rests behind the cervix and the anterior horizontal bar rests behind the symphysis pubis.

### Space-occupying pessaries

The second pessary category is the space-filling pessary. These pessaries are used primarily to support severe POP, especially posthysterectomy vaginal vault prolapse. They have larger bases to support the vaginal apex or cervix; therefore, they are more difficult to insert and remove. When this pessary type is in place, sexual intercourse is not possible. Examples include the Gellhorn, donut, cube, and inflatable pessaries.

**FIGURE 5**



Hodge pessary (A), Smith pessary (B), and Risser pessary (C)

### Gellhorn

The Gellhorn pessary is the most commonly used space-filling pessary. It has a broad base with a stem (FIGURE 6). The broad base supports the vaginal apex while the stem keeps the circular base from rotating and prevents pessary expulsion. The stem comes in long or short lengths. The concave base provides vaginal suction and keeps the pessary in place. The holes in the stem and base provide vaginal drainage. The Gellhorn pessary is useful for women with more advanced prolapse and less perineal support.

**Insertion.** Folding one side of the base to the stem, insert the Gellhorn pessary vertically inside the vagina. To facilitate insertion, separate the labia with the nondominant

hand or depress the perineum with the index finger. Once the circular base is inside the vagina, push the pessary upward until the tip of the stem is just inside the vaginal introitus (FIGURE 7). Many medical illustrations inaccurately depict the Gellhorn pessary in a final placement that appears too high in the pelvis. This figure, which has the patient in a standing position, shows how low in the pelvis this space-filling pessary can sit in a patient with advanced prolapse.

Remove this pessary by gently pulling the stem while inserting the opposite hand beneath an edge of the pessary base to break the vaginal suction (see **Vaginal pessaries: An instructional video**, on page 43).

### FAST TRACK

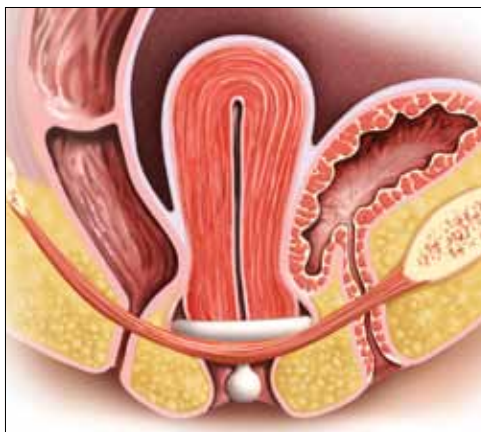
The space-filling pessaries support advanced-stage prolapse, with some, such as the donut and cube designs, more difficult to remove

**FIGURE 6**



Gellhorn pessary

**FIGURE 7**



When the patient is standing, the Gellhorn pessary sits just inside the tip of the vaginal introitus.

ILLUSTRATION: CRAIG ZUCKERMAN FOR OBG MANAGEMENT.

PHOTOS: COURTESY OF @COOPERSURGICAL, EXCEPT WHERE NOTED.



### Essential components of a successfully fitted pessary

#### Patient assessment

Accurate selection and placement of a pessary requires appropriate examination and fitting, beginning with determination of the patient's stage of prolapse and introitus. Key steps include:

- Examine the patient with an empty bladder in the lithotomy position
- Perform bimanual pelvic and speculum examination using a Sims speculum (or bivalve speculum broken in half) with the patient in a supine position
- Administer the Pelvic Organ Prolapse Quantification (POP-Q) exam
- Perform digital examination
- Assess vaginal atrophy, vaginal introitus, and vaginal width and length
- Evaluate pelvic floor muscle strength (Kegel squeeze).

Next, gauge the correct pessary size by approximating the number of fingerbreadths accommodated across the vaginal width.

Another method of estimating pessary size is to insert two fingers inside the vagina and estimate the distance between the posterior fornix and the posterior pubic symphysis (see *Vaginal pessaries: An instructional video*, on page 43). An easy reference is to start with a size 3 or 4 ring pessary if the vaginal introitus is 1 to 2 fingerbreadths in width and the prolapse is stage II to III. If the vagina accommodates 3 to 4 fingerbreadths, or there is stage IV prolapse, use a Gellhorn pessary.

Here are the different types of pessaries and the most common sizes available. (Pessary sizes change in quarter-inch increments.)

Ring:	Size 3 to 5 or 2.5 to 3 inches
Gehrung:	Size 3 to 5 or 2.5 to 3 inches
Lever:	2 to 4 inches
Gellhorn:	2.5 to 3 inches
Cube:	2 to 4 inches
Donut:	2.5 to 3 inches
Inflatable:	Sizes are medium or large

#### In-office trial

Insert the pessary into the vagina using the dominant hand. Using the nondominant hand, separate the introitus and depress the perineal body. Apply a small amount of lubricant to the leading edge of the pessary.

After insertion, ask the patient to strain and cough, ambulate in the office, and void. Reexamine the patient to ensure that the pessary is still in the correct position and that placement has not shifted. Perform the cough leak test with the patient in a standing position and the pessary in place. Re-examine the patient while she is in a standing position. Use the largest pessary that is comfortable for her. Advise her to bring the pessary back to the office if it gets expelled.

This is a trial-and-error process; advise the patient of this. It may require a trial of several styles and sizes to find the right pessary fit. Once you find the correct size, document the final pessary size.

#### Follow-up

Schedule a follow-up appointment 1 to 2 weeks after insertion. Ask the patient whether she has experienced any discomfort, malodorous discharge, or vaginal bleeding. Also inquire about any changes in urinary habits or bowel movements and related complaints.

Remove the pessary and clean it with mild soap and water. Examine the vagina for pressure points, abrasions, ulcerations, and erosions.

Teach the patient how to remove, clean, and reinsert the pessary, and advise her to perform these tasks on a weekly basis.

Schedule a follow-up visit in 1 to 2 months, and another visit 6 to 12 months after that.

If the patient cannot or will not remove her pessary, ask her to return in less time, usually 1 to 2 months, to observe her progress, with subsequent visits every 3 to 4 months for pessary cleaning and assessment, again depending on the condition of her progress.

#### Donut

The donut pessary is used for advanced prolapse because it fills a larger space. It is difficult to insert and remove because it is large, thick, and hollow (**FIGURE 8**, page 51).

**Insertion.** Insert it vertically and, once it is placed inside the vagina, rotate it to a horizontal position. A Kelly clamp can be used

to grasp the pessary and facilitate removal.

#### Cube

The cube pessary supports third-degree uterine prolapse by holding the vaginal wall with suction (**FIGURE 9**). Because of the risk of vaginal erosion and lack of drainage in some designs, the cube pessary requires

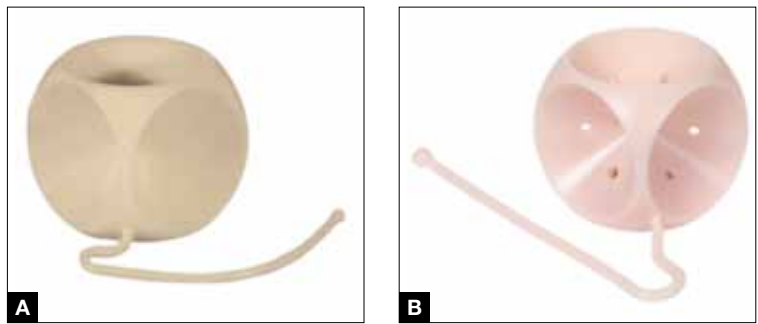


**FIGURE 8**



Donut pessary

**FIGURE 9**



Cube pessary (A) with drainage holes (B)

nightly removal and cleaning.

**Insertion.** Squeezing the pessary with the thumb, index, and middle fingers, insert the cube pessary at the vaginal apex.

Removal requires breaking the suction by placing a fingertip between the vaginal mucosa and the pessary and compressing the cube between the thumb and forefinger to remove. Gently tugging on the string also helps with removal.

### Inflatable

This space-filling pessary is an air-filled ball that is inflated via an attached stem that also enables insertion and removal. The older *Inflatoball* pessary is made of latex, so its use is contraindicated in patients with latex allergy. Newer inflatable pessaries are silicone-based and consist of an air-filled donut, a stem with a valve, and an air pump (FIGURE 10). Some models also include a deflation key. The inflatable pessary comes in small, medium, large, and extra-large sizes. This pessary type must be removed and cleaned daily.

**Insertion.** Place the deflated pessary into the vagina. Move the ball-bearing valve within the stem (which controls the air flow) to a lateral projection on the side of the stem. To inflate, attach the inflation bulb. (Inflation typically requires 3 to 5 pumps of the bulb.) Move the ball bearing back into position to maintain the inflation, then detach the bulb. You can leave the stem outside the body or tuck it gently into the introitus (FIGURE 11, page 52).

### Incontinence pessaries

These devices are used specifically for SUI. The incontinence ring (FIGURE 12, page 52) and incontinence dish pessaries compress the urethra against the pubic symphysis. The knob is placed beneath the urethra, increasing the urethral closure pressure and thereby preventing urinary incontinence.

#### CASE 1 Concluded

Given that AC has early-stage POP and is sexually active, a space-occupying pessary is not the optimal choice. Instead, a ring pessary with support is fitted for her trial.

#### What side effects might a patient anticipate with pessary use?

Vaginal discharge and slight odor are common. Pessary removal and cleaning are usually adequate to eliminate them. Temporary discontinuation of pessary use may be warranted until symptoms subside. If these maneuvers do not resolve the issue, then the

#### FAST TRACK

Side effects could deter some women from using a pessary. Appropriate counseling about what to expect and report is warranted.

**FIGURE 10**



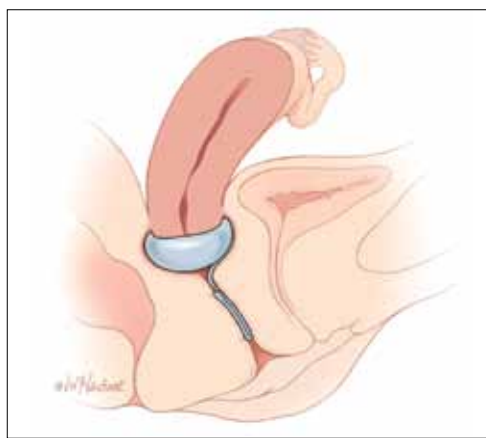
Inflatable pessaries

PHOTOS: COURTESY OF @COOPERSURGICAL, EXCEPT WHERE NOTED.

PHOTOS: COURTESY OF BIOTIQUE AMERICA.



**FIGURE 11**



With the patient lying down, the inflatable pessary is inflated within the vagina. The inflation bulb is detached and the stem is tucked into the introitus.

patient should be examined to rule out other sources of infection.

**Vaginal bleeding.** Bleeding from vaginal abrasion and ulceration could be caused by trauma from pessary removal or vaginal impingement. Evaluation is warranted for any vaginal bleeding.

**Changes in urinary function.** Less commonly, women using a pessary may notice changes in their urinary function. Many women with anterior or apical prolapse will have altered urine streams with slow or

**FIGURE 12**



Ring pessary with knob

trickling flow and possible hesitation upon initiation of voiding.

Alternatively, pessary placement may instigate stress-type incontinence akin to that seen after prolapse surgery. Changing pessary size may alleviate this condition. Otherwise, these side effects may reduce a patient's willingness to continue pessary use.

### How can a patient optimize her use of a pessary?

A patient can remove the pessary on a periodic basis or try to use it continuously. If she cannot or will not remove the pessary, then she will need to come back for scheduled visits, as described in the sidebar, "Essential components of a successfully fitted pessary." If she is able to remove the pessary on her own, then she can use the device as needed or remove it for intercourse (though it is not necessary). She must remove it weekly, at a minimum, however, to both clean the pessary and give the vaginal walls a "rest," which can minimize the potential for abrasions or erosions.

### CASE 2 Advanced-stage POP

**BD is an 82-year-old widow (G5P4014) with stage IV vaginal prolapse. She has noticed some scant blood staining on her clothing. She frequently voids small amounts of urine but never feels complete relief. She defecates normally.**

Her medical history is significant for coronary artery disease with prior myocardial infarction, with multiple stent placements over the years. She has hypertension, reduced ejection fraction, and diabetes. She is morbidly obese and suffers from degenerative joint disease. She had a vaginal hysterectomy several years ago for benign indications.

Upon examination, BD's prolapse is large, with excoriations and hyperkeratosis of the skin over the prolapse. It is easily reduced in the office.

**What is the best pessary for this patient, and how should she be followed and counseled regarding ongoing care?**

Since the failure rate for pessary usage increases with advancing prolapse stage, a

### FAST TRACK

The typical follow-up interval for a patient with a space-occupying pessary is 3 to 4 months

CONTINUED ON PAGE 59

ILLUSTRATION: MARCIA HARTSOCK FOR OBG MANAGEMENT  
PHOTOS: COURTESY OF ©COOPERSURGICAL, EXCEPT WHERE NOTED.





CONTINUED FROM PAGE 52

space-occupying pessary is most appropriate to try initially. A trial with a support pessary could be useful to allow the excoriations to heal and provide a healthier vaginal environment. A Gellhorn pessary is commonly used. An inflatable pessary could be an alternative if the Gellhorn fails to stay in place. The cube pessary, known to cause more abrasions and erosions than other pessaries, is a poor choice given the state of the patient's vaginal tissues at baseline.

Space-occupying pessaries are more difficult to insert and remove and have a higher risk of pain or trauma. Start with shorter time intervals between visits, eventually spacing them out for the patient's convenience. The usual interval for follow-up is 3 to 4 months; longer intervals could be offered if the patient is reliable, adherent, and reports no complaints with pessary use.

## Outcomes

Only short- and medium-term outcomes for pessary use have been described in the literature. Short-term (2 months) satisfaction and continued use, along with resolution of prolapse, occurred in 92% of patients.<sup>7</sup> Previous hysterectomy or prolapse surgery may influence the short-term success of pessary use.<sup>10</sup> **More than half of sexually active women achieved long-term use (up to 2 years), regardless of prolapse severity.** Brincat and colleagues found that long-term pessary use (1 to 2 years) approached 60% in 132 women with both urinary incontinence and prolapse. Women being treated for POP were more likely to continue pessary use than women being treated for SUI.<sup>11</sup> Age, parity, estrogen use, and sexual activity were characteristics also studied in pessary fitting. Neither sexual activity nor stage of prolapse was a contraindication to use of a pessary; long-term use was found to be acceptable in sexually active women.<sup>11</sup>

Successful fitting of a vaginal pessary has been associated with improvement in voiding, urinary and fecal urgency, and incontinence. A vaginal pessary is a viable nonsurgical option for the management of POP and urinary incontinence and remains an optimal minimally invasive approach to such disorders.

### CASE 2 Concluded

**The patient returns to the clinic 1 month after the original insertion. The pessary is removed, and the vagina is inspected, with no abrasions or ulcerations found. The vaginal cavity and pessary are cleaned with a mild soap-and-water mixture. The pessary is lubricated and reinserted. This process is repeated 2 months later, with subsequent follow-up intervals doubled (up to 6 months between visits) when the patient has no complaints of discharge or odor.** 📌

### References

- Colmer, WM Jr. Use of the pessary. *Am J Obstet Gynecol.* 1953;65(1):170-174.
- Culligan PJ. Nonsurgical management to pelvic organ prolapse. *Obstet Gynecol.* 2012;119(4):852-860.
- Nygaard IE, Heit M. Stress urinary incontinence. *Obstet Gynecol.* 2004;104(3):607-620.
- ACOG Committee on Practice Bulletins—Gynecology. ACOG Practice Bulletin No. 85: Pelvic organ prolapse. *Obstet Gynecol.* 2007;110(3):717-729.
- Clemons JL, Aguilar VC, Tillinghast TA, Jackson ND, Myers DL. Risk factors associated with an unsuccessful pessary fitting trial in women with pelvic organ prolapse. *Am J Obstet Gynecol.* 2004;190(2):345-350.
- Clemons JL, Brubaker L, Falk SJ. Vaginal pessary treatment of prolapse and incontinence. UpToDate. <http://www.uptodate.com/contents/vaginal-pessary-treatment-of-prolapse-and-incontinence>. Updated February 8, 2013. Accessed November 7, 2013.
- Mutone MF, Terry C, Hale DS, Benson JT. Factors which influence the short-term success of pessary management of pelvic organ prolapse. *Am J Obstet Gynecol.* 2005;193(1):89-94.
- Fernando RJ, Thakar R, Sultan AH, Shah SM, Jones PW. Effect of vaginal pessaries on symptoms associated with pelvic organ prolapse. *Obstet Gynecol.* 2006;108(1):93-99.
- Weber AM, Richter HE. Pelvic organ prolapse. *Obstet Gynecol.* 2005;106(3):615-634.
- Donnelly MJ, Powell-Morgan S, Olsen AL, et al. Vaginal pessaries for the management of stress and mixed incontinence. *Int Urogynecol J Pelvic Floor Dysfunct.* 2004;15(5):302-307.
- Brincat C, Kenton K, Fitzgerald MP, et al. Sexual activity predicts continued pessary use. *Am J Obstet Gynecol.* 2004;191(1):198-200.



**Neither sexual activity nor stage of prolapse has been found to preclude long-term use of a pessary**