



Differences in Perceptions of Beauty and Cosmetic Procedures Performed in Ethnic Patients

Lily Talakoub, MD,* and Naissan O. Wesley, MD[†]

The United States has become progressively more multicultural, with the ethnic population growing at record rates. The US Census Bureau projects that, by the year 2056, greater than 50% of the US population will be of non-Caucasian descent. Ethnic patients have different cosmetic concerns and natural features that are unique. The cosmetic concerns of ethnic patients also differ as the result of differences in skin pathophysiology, mechanisms of aging, and unique anatomic structure. There is no longer a single standard of beauty. We must now adapt to the more diverse population and understand how to accommodate the diversity of beauty in the United States. Ethnic patients do not necessarily want a Westernized look because what constitutes beauty is determined by racial, cultural, and environmental influences. We as leaders in skin care must understand these differences and adapt our practices accordingly. This article will focus on the differences in aging in different ethnic populations and highlight procedures unique to skin of color.
Semin Cutan Med Surg 28:115-129 © 2009 Elsevier Inc. All rights reserved.

The United States has become progressively more multicultural in with the non-Caucasian ethnic population growing at record rates. The US Census Bureau projects by the year 2056, greater than 50% of the US population will be of non-Caucasian descent.¹ For centuries, the esthetic ideal was based on artist and anatomist drawings. We now have defined mathematical anthropometric measurements of the ideal facial structure; however, most of these measurements have been based on the Caucasian face. In recent years, ethnocentric variability in these ideals has been described and is constantly changing with the increasing presence of ethnic persons in the media, changing the standards of beauty.²

The term ethnic skin has been used in the medical literature to describe skin of color, traditionally of Fitzpatrick skin types III-VI. Similar terms used include dark skin, brown skin, and pigmented skin. These terms do not define any particular race, ethnicity, or culture, nor do they adequately describe all skin types and pigmentations. Among African Americans there is wide range of skin pigmentation. There are also differences in skin pigmentation among Asians in Japan and China as compared with slightly darker skin types in Koreans and people of South-East Asia, such as Thailand, Singapore, and Cambodia. Skin-type definition initially pro-

posed by Fitzpatrick does not adequately define the multicultural variations we see every day. Until a more inclusive term is defined, we will use the term "ethnic skin" in this article to refer to patients with pigmentation darker than that of Caucasian race (Table 1).

Up until the late 1990s, most of the literature published on cosmetic procedures focused on Caucasian patients. In addition, cosmetic industries developed most of their products for the Caucasian consumer. In recent years, more ethnic patients are requesting cosmetic procedures and there is an increasing demand for anti-aging products and services. According to the American Society of Plastic Surgery, there has been a 457% increase in nonsurgical cosmetic procedures between the years 1997 and 2007; ethnic minorities comprised 22% of all cosmetic procedures, which is an increase from 17% in 2001.³

Ethnic patients have natural features that are unique and thus have different cosmetic concerns. The cosmetic concerns of ethnic patients differ as the result of differences in skin pathophysiology,⁴ mechanisms of aging, and unique facial structure. For example, photoaging in the African-American population is not as pronounced as that seen in Caucasian patients, yet dyschromia is a significant problem in this subset of patients. The cosmetic industry is beginning to understand these distinctive features and is developing a large market of products for the ethnic patient.

There is no longer a single standard of beauty. We must now adapt to the more diverse population and understand how to accommodate the diversity of beauty of persons of

*Department of Dermatology, University of California, San Francisco.

[†]SkinCare Physicians, Chestnut Hill, MA.

Address correspondence to Lily Talakoub, MD, University of California, San Francisco, 1701 Divisadero Street, 3rd Floor, San Francisco, CA 94105.
E-mail: lilytalakoub@gmail.com.

Table 1 Ethnic Groups That Comprise Persons Defined as Having “Ethnic Skin”

“Black”	African, black persons of African descent, including African-American, Caribbean-American, and Latin-American persons
Latino or Hispanic	Persons of Spanish and indigenous Central/South American descent, including Central Americans, South Americans, and Caribbean-American persons of Spanish descent, including Cuban, Puerto Rican, and Dominican
East Asian	Chinese, Japanese, Korean
Southeast Asian and Pacific islander	Filipino, Vietnamese, Cambodian, Thai, Malaysian, Laotian, Burmese, Hmong descent, Polynesian, Micronesian
Australoid	Australian aborigine, Melanesian descent (new the Republic of Guinea, Papua, Solomon Islands)
Native Americans	More than 560 recognized tribes, including Inuit.
East Indian	Indian, Pakistani, Bangladesh, Sri Lanka
Middle Eastern	Iranian, Iraqi, persons from Saudi Arabia and the Arabian Peninsula (including Kuwait, Bahrain, Oman, Qatar, the United Arab Emirates, Yemen), Lebanese, Afghani, Jordanian, Syrian, <i>Israeli</i> , Turkish, North African (Egypt, Morocco, Algeria, Libya)

Traditionally, there are 9 geographic races, each with particular genetic similarities. These geographic races include Europeans (which include Middle Eastern and Mediterranean persons), Eastern Indians, Asians, American Indians, Africans, Melanesians, Micronesians, Polynesians, and Australian Aborigines. We modify these schema into categories in which, ethnic persons share similar anatomic characteristics.

different ethnicities in the United States. Ethnic patients do not necessarily want a Westernized look because what constitutes beauty is determined by racial, cultural, environmental influences.^{5,6} As leaders in skin care, we must understand these differences and adapt our practices accordingly. This article will focus on the differences in aging in different ethnic populations and highlight procedures unique to skin of color.

Skin Differences Among Ethnic Groups

There has been expanding research on the fundamental differences in skin structure and function of different ethnic groups.⁷ However, categorization of these differences into a classification system has been difficult with growing variations in pigmentation because of racial mixture.^{8,9} The classification of skin of color was originally developed by Fitzpatrick as the Fitzpatrick Skin Phototype System (Table 2).¹⁰ This system defines skin type based on reaction to ultraviolet (UV) radiation. Other skin classifications have been proposed, such as the Lancer Ethnicity Scale, which calculates healing efficacy and time in patients undergoing cosmetic

laser or chemical peel procedures (Table 3).¹¹ Other systems have been designed to define skin color but have limited clinical usage.

There have been several studies in which the authors examined intrinsic differences in skin structure in different ethnic groups.¹²⁻¹⁵ The most significant difference between people of color and Caucasians is the amount of melanin in the skin. The major determinant of skin color is the activity of melanocytes, ie, the quantity and quality of pigment production, not the density of melanocytes. Melanosomes, located in the cytoplasm of the melanocyte, are the site of melanin

Table 2 Fitzpatrick Skin Phototype System

Skin Phototype	Reaction to Moderate Sun Exposure*	
	Burn and no tan	Skin Color
I	Burn and no tan	White
II	Burn and minimal tan	White
III	Burn then tan well	White to light olive
IV	Tan, minimal to no burn	Light brown
V	Tan, no burn	Brown
VI	Tan, no burn	Dark brown

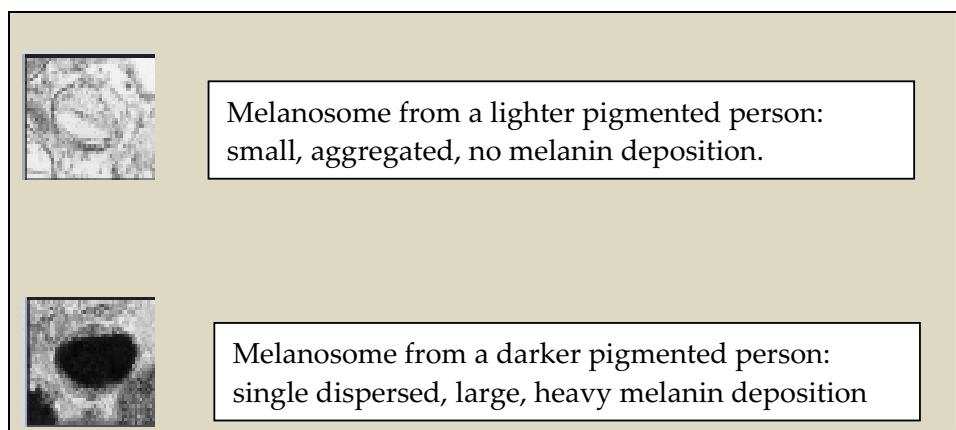
Modified from Fitzpatrick TB: Skin phototypes 2002, 20th World Congress of Dermatology, Paris, July 1-5 2002.

*Thirty minutes unprotected sun exposure in peak season (spring or summer) depending on the latitude.

Table 3 Lancer Ethnicity Scale (LES)

Geography	Fitzpatrick Skin Phototype	LES Skin Type
Persons of African background		
Central, East, West African	V	5
Eritrean and Ethiopian	V	5
North African, Middle East Arabic	V	5
Sephardic Jewish	III	4
Persons of Asian background		
Chinese, Korean, Japanese, Thai, Vietnamese	IV	4
Filipino, Polynesian	IV	4
Persons of European background	II	3
Celtic	I	1
Central, E. European	III	2
Nordic	I-II	1
N. European (general)	I	1-2
S. European, Mediterranean	III	3-4
Persons of Latin/Central/South American background		
Central/South American Indian	IV	4
Persons of North American background		
Native American (including Inuit)	II	3

Modified from Wolbarsht ML, Urbach F: The Lancer Ethnicity Scale. *Lasers Surg Med* 25:105-106, 1999



Modified from Bologna J, Jorizzo JL, Rapini RP: *Dermatology*. New York, Mosby, 2003.

Figure 1 Electron micrographs of melanosomes in darker vs. lighter pigmented persons.

biosynthesis. Melanosomes are transferred from the dendrites of the melanocyte into neighboring keratinocytes of the epidermis. Variation in skin color is dependent on the number, size and aggregation of the melanosomes within the keratinocyte.¹² Dark-skinned black patients have singly dispersed, large melanosomes that contain more melanin compared with smaller aggregated melanosomes containing less melanin in lighter-skinned persons.¹³⁻¹⁵ Once transferred to keratinocytes, melanosomes are also degraded more slowly in darker skin (Fig. 1).

On a molecular level, there are defined pigmentation genes, such as tyrosinase-related protein family members, melanocyte-stimulating hormone, melanocyte-stimulating hormone receptor, and the melanocortin-1-receptor that also contribute to the difference in pigmentation among ethnicities. Tyrosinase-related protein 1 has been shown to increase tyrosinase activity, melanin synthesis, and melanosome size. Increase in tyrosinase activity and melanin production can explain why the same number of melanocytes in different skin types results in differential responses to UV light. Similarly, melanocyte-stimulating hormone increases DNA repair

proteins, which protects against sun-induced DNA damage in darker-skinned patients.¹⁶

Early studies have suggested that the thickness of the skin is the same in light and dark skin; however, darker skin types have may have more cornified cell layers and greater lipid¹⁷ content compared to white stratum corneum¹⁸. Black skin has been found to have more and larger fibroblasts, smaller collagen fiber bundles, and more macrophages than white skin.¹⁹ A review of differences in skin structure and function has been conducted by one of the authors and has been summarized in Table 4.^{20,21}

Aging in Different Ethnic Groups

Aging has many etiologic contributions. Genetics, gravity, behavior, and environment all play an important role in the aging process; however, a majority of the visible cutaneous signs of aging are the result of UV exposure. Dyschromia, crow's feet, and perioral and other facial rhytides can occur decades earlier in fair-skinned individuals as compared with age-matched persons with darker skin.

Table 4 Objective Differences in Skin Structure and Physiology Based on Race

Evidence Supports	Insufficient Evidence* for	Inconclusive:
<ul style="list-style-type: none"> ● Increased melanin content and melanosomal dispersion in persons of color ● Multinucleated and larger fibroblasts in black persons compared with white persons ● pH black < white skin ● Larger mast cell granules, increased PLS, and increased tryptase localized to PLS in black compared with white skin ● Variable racial blood vessel reactivity 	Racial differences in: <ul style="list-style-type: none"> ● Skin elastic recovery/extensibility ● Skin microflora ● Facial pore size† 	Racial differences in: <ul style="list-style-type: none"> ● TEWL ● Water content ● Corneocyte desquamation ● Lipid content

PLS = parallel-linear striations; TEWL = trans-epidermal water loss.

Adapted from Wesley NO, Maibach HI: Racial (ethnic) differences in skin properties: The objective data. *Am J Clin Dermatol* 4:843-860, 2003.

*Skin elastic recovery/extensibility, skin microflora, and pore size were labeled as "insufficient evidence for" racial differences rather than "inconclusive" because only 2 studies or fewer examined these variables.

†Sugiyama-Nakagiri Y, Sugata K, Hachiya A, et al: Ethnic differences in the structural properties of facial skin. *J Dermatol Sci* 53:135-139, 2009.

Table 5 Glogau Classification of Facial Photoaging

Type	Age (years)	Clinical Findings
I, no rhytides	20-30s	Minimal pigmentary change or rhytides, no keratoses
II, dynamic rhytides	Late 30-40s	Early senile lentigines, keratoses palpable but not visible, parallel smile lines begin to appear, dynamic rhytides
III, static rhytides	50 or older	Obvious dyschromia, telangiectasia, visible keratoses, static rhytides
IV, all rhytides	60-70s	Yellow/grey color of skin, previous skin malignancies, rhytides throughout

Modified from Glogau RG: Aesthetic and anatomic analysis of the aging skin. *Semin Cutan Med Surg* 15:134-138, 1996.

The way in which aging is defined in the medical literature is also quite varied. The Glogau classification of facial photoaging is a commonly used parameter among dermatologists (Table 5).²² There is heavy emphasis on rhytidosis in this classification scheme; however, there are significant structural changes that play a significant role in the aging face that are not accounted for with this classification system. The development of a tear-trough depression, loss of cheek fat, prominence of the jowls, and deepening of the various facial folds, such as the nasolabial fold and marionette lines are some of the common structural changes in the aging face. Aging of the neck is associated with loose skin, platysmal bands, and transverse folds. This section will highlight differences in photoaging and structural aging in ethnic populations.

Photoaging

Photodamage is defined as prematurely aged skin resulting from the effects of UV radiation. It is characterized by coarse and fine wrinkling, mottled pigmentation, sallowness, textural roughness, and telangiectasias. Histologic features include epidermal and dermal thinning, loss of polarity of epidermal cells, and keratinocyte atypia. Dermal features include elastosis, degeneration of collagen and anchoring fibrils.²³

Photoaging is arguably the most significant concern of cosmetic patients. However, it is not as prominent in skin of color, particularly in those populations with darker skin. Photodamage in Caucasian patients results in rhytides, skin laxity, sallowness, solar lentigines, seborrheic keratoses, and dyschromia. Ethnic patients have increased epidermal melanin and a thicker dermis, thereby revealing less photodamage than their age-matched lighter-skinned counterparts. Darker skin types have fewer rhytides but with photoaging develop mottled pigmentation, texturally rough skin, dermatosis papulosa nigra and seborrheic keratosis, and solar lentigines.

There are well-defined racial differences in melanosome size, distribution, and melanization of the skin.²⁴ Skin of

color has the benefit of additional melanin and different packaging and distribution of melanosomes that reduces transmission of UV light. Kaidbey et al and others showed that increased melanin acts as a UV filter, with 5 times as much UV light reaching the upper dermis of white patients as compared with black patients.^{25,26} African Americans develop less solar elastosis, and the increased melanin content in dark skin protects against actinic damage and nonmelanoma skin cancers.²⁷ The timing of photoaging also differs among fair-skinned and dark-skinned individuals. Signs of photoaging are evident in the fourth decade in Caucasians; however, they may not be visible until the fifth or sixth decade in darker ethnic persons.

Nouveau-Richard et al²⁸ evaluated 160 Chinese and 160 Caucasian French age-matched women (average age 20-60 years of age) for signs of aging, including facial wrinkles (crow's-feet, glabella, and perioral wrinkles) and pigmented spots. The groups did not differ in the assessment of lifelong exposure to the sun. This study revealed that wrinkle onset is delayed by 10 years in Chinese women as compared to French Caucasian women. However, pigmented spot intensity was much more prevalent in Chinese women.

Morizot et al²⁹ evaluated the differences in the appearance of aging, in more than 500 age-matched women from Japan (Sendai) and France (Paris). The groups displayed no difference with respect to age, smoking habits, of self-reported lifetime sun exposure. The results of this study showed that solar damage and rhytidosis occurred at an earlier age and were more severe in French women than Japanese women; however, pigmented spots occurred more and earlier in life in Japanese women than in French women. This study elucidated that intrinsic pigmentation alters signs of aging and of dyschromia.

Hillebrand et al³⁰ also looked at differences in aging in 2 Japanese cities (Akita, 39 degrees N, and Kagoshima, 31 degrees N) to evaluate geographic location and photoaging. This study confirmed that photoaging occurred several years earlier in women from Kagoshima, a city closer to the equator and with more UV exposure. This study elucidates variability in aging manifestations within ethnicities as well as among different ethnicities.

Acceptable social norms among patients differ with regards to UV exposure. In the United States, many persons of all racial groups prefer the appearance of tanned skin (Although this perception may be beginning to change as more people are educated about the effects of UV exposure). However, around the world these perceptions differ. For example, in Asia and South-East Asia, many women much prefer extremely fair skin to tanned skin, and the cosmetic procedures performed reflect this attitude.

Treatments for photodamage in Caucasian patients may differ from those in darker skin types. The best evidence of topical treatment for signs of aging comes from literature on the use of topical tretinoin (all-trans-retinoic acid) in Caucasian patients.^{31,32} Tretinoin has been shown in well-controlled studies to reduce fine wrinkles, hyperpigmentation, and histologically provides a reduction in epidermal atypia and dysplasia, a reduction in melanin granules throughout

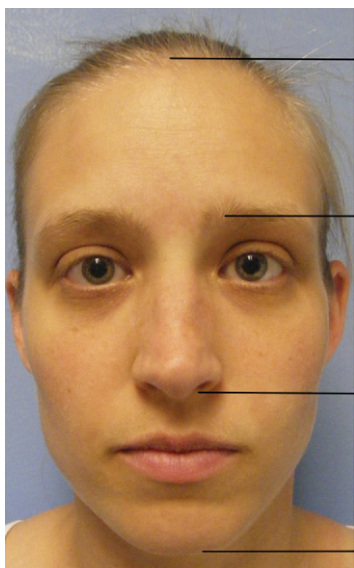


Figure 2 Caucasian woman, age 28. The face is divided into equal horizontal thirds: distance from the frontal hairline to the top of the brow, from the brow to the base of the nose, and from the base of the nose to the distal portion of the chin. (used with permission.)

the epidermis, increased vascularity of the papillary dermis, and formation of new collagen.³³ However, data also have confirmed its benefit in the treatment of dyschromia and fine wrinkling in Asian skin.³⁴

Structural Aging

Structural facial aging is caused by the volumetric loss of fat, skeletal resorption, and redistribution of skin and soft tissue. In the younger face, the superficial and deep fat is distributed evenly. As the face begins to age, fat atrophy and hypertrophy cause an irregular topographic contour to the face. Atrophy develops on the temples, cheek, and lateral chin; bone resorption of the mandible and loss of lip volume occurs; as well as increased shadowing under the eyes and sometimes increased protrusion of the infraorbital fat pads. All of these contribute to sagging of the overlying skin.³⁵ The aging process also has ethnocentric variability. Traditional esthetic procedures should be modified to adapt to the patient’s ethnic background and unique facial structure.

Careful evaluation of facial proportions is necessary before any esthetic procedure is undertaken. This analysis should consider not only ethnocentric variations in facial structure and aging but also ethnically diverse perceptions of beauty. Anthropometry is the quantitative measurement and ratio of facial features; a quantitative standard of attractiveness. It is based on proportional relationships of the face known as the neoclassical canons that have been studied and revised for hundreds of years.

Originally, proposed by Leonardo da Vinci, the face is divided into equal horizontal thirds: distance from the frontal hairline to the top of the brow, from the brow to the base of the nose, and from the base of the nose to the distal portion of the chin (Fig. 2). The facial proportions of the Caucasian patient as outlined in Table 6 adapted from the original article by Powell and Humphreys³⁶ is defined by an oval face, prominent cheekbones, tapered jaw line, narrow nasal base, and thin lips (Table 6).³⁷

Another method used to calculate beauty with mathematical proportions is the concept of “phi,” the golden ratio. The ratio of 1:1.618 was described by ancient Greeks as a mathematical method to calculate optimal proportions for all structures in nature; some believe that the neoclassical canons are modifications of phi. Dr Stephen Marquardt, a plastic surgeon, trademarked the “phi mask,” a facial mask of proportions that incorporates the 1:1.618 ratio to describe the most attractive face (Fig. 3). The phi mask has been applied to persons of all races and ethnicities.

Matory, Holland, and Grimes have suggested that these defined proportions are not applicable to all ethnic groups.³⁸⁻⁴⁰ In recent years, esthetic surgeons are beginning to understand and modify these proportions to fit the widely diverse and structurally unique ethnic patient (Table 6). Marquardt himself has also modified the “phi mask” to apply to 3 different ethnic groups—Caucasian, Asian, and African—with the statement that more variations may be developed.⁴¹ Although discussion of all anthropometric measurements and facial structure is beyond the scope of this article, we attempt to highlight differences among ethnic groups.

African-American Facial Analysis

Although African-Americans do not develop as much UV-induced photoaging as Caucasian patients, given their in-

Table 6 Facial Analysis of Women of Different Ethnic Groups

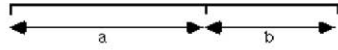	Caucasian	African-American	Caribbean American	Central American	South American	Southern Chinese
Horizontal proportions*	1:1:1	1:1.2:1.3 or 1:1.2:1.2				
Nasofrontal angle	125°-135°	127.6° or 136.8°-137.4°	110°	137°	136°	137.9° (119-166)
Nasofacial angle	36-40°	33.4° or 38.9°	41°	44°	46°	36.4° (20-46)
Alar width: Intercanthal distance	1:1	1.2:1	1.2:1	1:1	1.1:1	> 1:1
Columella:lobule	2:1	1.3:1 or 1:1.2 or 1:1.3	1.5:1	1.1:1	1.5:1	1.2:1
Nasolabial angle	90°-120°	73.9° or 85.6°-90.3°	110°	99°	100°	87.8° (55-108)

Adapted from Powell N, Humphreys B: Proportions of the aesthetic face. Thieme-Stratton: New York, 1984.

*Horizontal proportions derived from relationship of trichion to glabella, glabella to subnasale, subnasale to gnathion ratio.

A

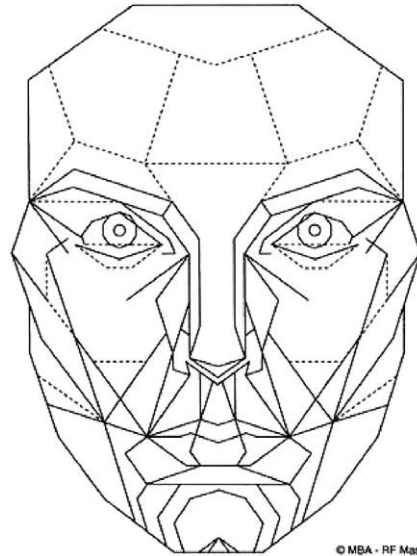
This is a line which has been divided into two segments, the larger of which has a (magnitude) ratio to the smaller of 1.618:1



Where $a=1.618$ and $b=1$

Phi ($\Phi = 1.618$), also known as the Golden Ratio or Golden Section, has been used by architects and artists throughout history to produce objects of great beauty, such as sculptures and temples. The ratio can also be applied to patterns seen in nature, such as flowers. The Golden Ratio is based on Fibonacci Numbers, where every number in the sequence (after the second) is the sum of the previous 2 numbers: 1, 1, 2, 3, 5, 8, 13, 21, ... The ratio of each number in the Fibonacci sequence to the one before it (after the number 5) equals approximately 1.618 033 988 7.. (e.g. $5/3 = 1.666$, $8/5 = 1.6$, $13/8 = 1.625$, $21/13 = 1.615...$, $34/21 = 1.619$, etc.).

Adapted from: Dunlap RA. The Golden Ratio and Fibonacci Numbers. River Edge, NJ: World Scientific Publishing Co; 1997.

B

© MBA - RF Mask

The “Phi mask” applies the concept of phi to demonstrate symmetric and aesthetically appealing facial proportions. Adapted from Marquardt Beauty Analysis, http://www.beautyanalysis.com/index2_mba.htm.

Figure 3 (A) Phi. (B) Phi mask. The Phi mask applies the concept of phi to demonstrate symmetric and esthetically appealing facial proportions. Adapted from Marquardt Beauty Analysis (http://www.beautyanalysis.com/index2_mba.htm).

creased skin melanin, there is pronounced sagging of the malar fat pads, soft-tissue laxity, and jowl formation of the mid face. Studies of facial analysis by Farkas et al⁴² highlight the difference in facial structure in African Americans as compared with Caucasians (Table 6). African Americans have a broad nasal base, decreased nasal projection, bimaxillary protrusion, orbital proptosis, increased soft tissue of the mid-face, prominent lips, and increased facial convexity(Fig. 4).⁴³ Further studies also revealed 2 types of African-American nasal structure, one with a high dorsum and one with a low dorsum, reflecting variability in interethnic facial structure.⁴⁴

Latino Facial Analysis

There is a wide variety of ethnicities comprising the term “Latinos” as previously mentioned. This diversity also plays a huge role in facial structure differences among ethnicities. Similar to African Americans, increased melanization provides enhanced protection against photoaging; however, Latinos do develop skin mottling, jowl formation, infraorbital hollowness, and shadowing.⁴⁵ In persons of Mexican descent, the face is broad with prominent malar eminence, broad nose, widened alar base, short columella, horizontally oriented nostrils, and thick nasal skin.^{46,47} In Caribbean women, the anthropometric measurements are more similar




Figure 4 African-American woman, age 38. (used with permission.)

to African-American women, whereas central and South American women often have similar anthropometric measurements to Caucasian women.^{48,49} Overall Hispanics have increased bizygomatic distance, bimaxillary protrusion, greater convexity angle, broader nose, broad rounded face, and a receding chin (Fig. 5).⁵⁰

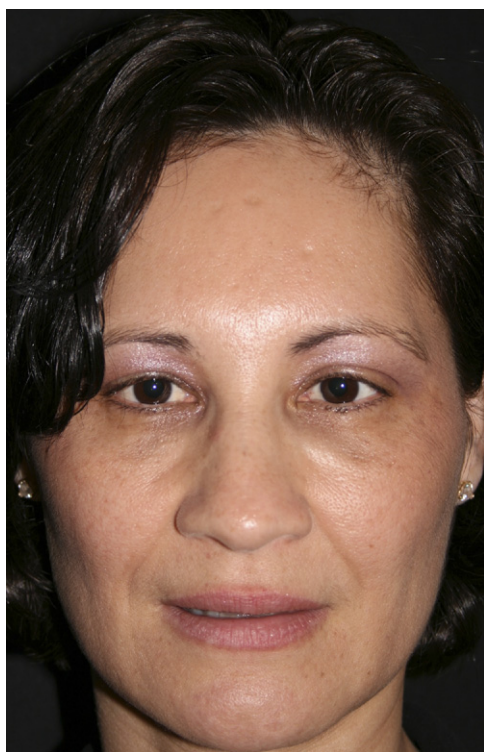

Figure 5 Latino (Puerto Rican) woman, age 46. (used with permission.)



Figure 6 Asian (Chinese woman), age 26. (used with permission.)

Asian Facial Analysis

The aging face in the Asian population is significantly different than aging in Caucasian patients.⁵¹ Studies that have evaluated the Asian facial structure suggest that Asians have a weaker facial skeletal framework, which results in greater gravitational soft-tissue descent of the midface, malar fat pad ptosis, and tear trough formation. Shirakabe et al⁵² also proposes that the facial structure and soft tissue of Asians is similar to that of an infant, including a wider and rounder face, higher eyebrow, fuller upper lid, lower nasal bridge with horizontally placed flared ala, flatter malar prominence and midface, more protuberant lips, and more receded chin (Fig. 6). The distance from the eyebrow to the upper-lid margin in Asians is much greater than in the Caucasians due to the fuller upper eyelid and to the narrower palpebral fissure.⁵³ There is also more malar fat in the midface of Asians, moderate premaxillary deficiency, and more prominent soft tissue in the lips compared to Caucasians that have thinner lips and a more prominent chin.⁵⁴ Additionally, Asians have a broad prominent forehead, wider intercanthal distance, short palpebral fissure, and a lack of supratarsal crease.^{55,56} Koreans also have wider lower face with recessed chin, and a wider mandibular angle.⁵⁷

A study by Biller and Kim,⁵⁸ characterizing ideal nasolabial angle, nasal tip width, and location of eyebrow apex for Asian and white women, demonstrates that neither the ethnicity of the model nor the ethnicity of the volunteer evaluating the model played a significant role in determining the ideal angle or position of the above parameters. They found that, in general, a more lateral brow apex is preferable in younger faces, whereas a more medial apex is preferred in older faces. In addition, moderate nasolabial angles of 104 and 108 de-

grees and a nasal tip width of 35% of the alar base was most attractive in both ethnicities. The study supports some claims that beauty is considered innate and independent of culture; however, the study is limited by a small number of models (4), representing only 2 ethnicities. In addition, all the volunteers evaluating the models were from the United States, which may represent a more “westernized” ideal of beauty.

The aforementioned differences in facial structure as well as previously mentioned differences in photoaging have contributed to different esthetic procedures sought by patients in different ethnic groups. For example, with regard to blepharoplasty, in the Asian eye there is an absence of a superior palpebral fold, which produces a “single eyelid,” the presence of an epicanthal fold, and more prominent periorbital fat pads, resulting in significantly different surgical approach. Moreover, Japanese women often like to preserve the greater of the epicanthal crease and opt for cosmetic procedures to restore a full-lid contour and prefer more thin lips.^{59,60} Korean women opt for a more defined palpebral crease, fuller lips, and a more delicate mandibular angle.^{61,62} Similarly, rhinoplasty in the African-American nose differs as most patients have a more bulbous tip, thicker skin, wider alar base compared with a drooping tip and short nasal length in the Latino nose. The understanding of these structural differences is thus imperative in the approach to any esthetic procedure.

Dyschromia: Melasma and Postinflammatory Hyperpigmentation

Unfortunately, the same wonderful features of melanocytes that prevent photoaging can contribute to less-desirable properties in darker skin types that make them more reactive to inflammation resulting in dyschromia. The most common complaints of dark-skinned patients are the dyschromic disorders, mainly postinflammatory hyperpigmentation and melasma. Although many skin-lightening agents and procedures are available to these patients, it is important to have an open and realistic conversation with them about skin dyspigmentation and set realistic goals about therapy.

There are very complex cultural factors associated with skin dyspigmentation and skin bleaching. Westernized, and generally lighter-skinned, ideals of beauty stem from complex social and cultural paradigms as historically Europeans colonized and dominated every corner of the world.⁶³ These ideals are beginning to change as racial intermixing has occurred and as persons of color continue to have a greater presence in leadership positions and in the media worldwide. Nonetheless, cultural beliefs valuing lighter skin still exist, especially in the Asian community.⁶⁴ In Japan, great lengths are taken to achieve the ideal *irojiro*, or fair skin, with some bleaching creams even advertised to bleach the lips or nipples. One survey by Synovate found that 4 of 10 women in Hong Kong, Malaysia, the Philippines, and South Korea used a skin-whitening cream. It is estimated that in Asia more than 60 global companies are competing for a share of their US\$18

billion dollar market.⁶⁵ These ideals are inherent in old Japanese and Chinese proverbs that state that “white skin makes up for seven defects” (Japanese) and “white skin can cover 1000 ugliness” (Chinese).^{66,67} Even in countries where pigmentation among the inhabitants is quite varied, such as Brazil, the Dominican Republic, and India, lighter-skinned individuals are often predominate in the upper socioeconomic echelon as well as leadership positions in government. A comprehensive level of understanding of these issues is necessary to address and treat patients with dyschromia.

Postinflammatory Pigmentary Alteration

Postinflammatory hyperpigmentation or hypopigmentation is a common consequence of many inflammatory skin conditions and treatment modalities in dark-skinned patients. Hyperpigmentation is caused by an increase in melanin production or an abnormal distribution of melanin pigment, whereas in hypopigmentation there is a decrease in melanin production.⁶⁸ The etiology of this phenomenon in dark-skinned patients is still unknown; however, literature supports the hypothesis that it is secondary to cytokines and inflammatory mediators, such as leukotriene (LT), prostaglandins (PG), and thromboxane (TXB) released during the inflammatory process.⁶⁹ Tomita et al⁷⁰ have shown from in vitro studies that LTC₄, LTD₄, PGE₂, and TXB₂ stimulate melanocyte enlargement and LTC₄ not only increases tyrosinase activity in melanocytes but also increases mitogenic activity of melanocytes.

Melasma

Melasma is common to many ethnic groups particularly Hispanics, African Americans, and Asians. It is an acquired disorder associated with multiple etiologic factors, including pregnancy, endocrine abnormalities, and oral contraceptive use. It often manifests as irregular, symmetric brown patches distributed over sun-exposed areas of the face.

Woods-light examination aids in the distinction of epidermal-type vs. dermal-type melasma. There can also be mixed and indeterminate variations; all of which are based on the depth of pigmentation. Epidermal-type of melasma, is intensified by Woods light examination as there is increased melanin throughout the epidermis, whereas dermal melasma is not enhanced by Wood’s light examination.⁷¹

Although the etiologic role is unclear, there is some genetic predisposition to developing melasma. Grimes et al⁷² reported that melasma may be the result of hyperactive and hyperfunctional melanocytes causing increased melanin deposition in the epidermis and dermis. Studies have also implicated progesterone in the etiology of melasma because postmenopausal women on estrogen therapy do not usually develop melasma but those on estrogen/progesterone therapy often do.^{73,74}

It is imperative that the underlying cause of melasma or postinflammatory pigmentary alteration be eliminated, including sun avoidance, oral contraceptives, and photosensitizing drugs. Ethnic patients use sunscreen less than their age-matched fair skin counterparts. Sunscreen usage is im-

portant in not only skin cancer prevention and the prevention of photo-aging, but also vital to the prevention of dyschromia. Patients should be instructed to wear daily broad-spectrum UVA-UVB sunscreens which include brookite and zincite. However, some formulations with zinc or brookite are less cosmetically acceptable to darker-skinned patients because they may leave a whitish or chalk-like hue on a darker-skinned individual; thus, the micronized forms of these ingredients may be preferable. Some sunscreens may be potent photosensitizers, such as sunscreens containing para-aminobenzoic acid, and should be used with caution because they may cause worsening dyspigmentation in the darker-skinned patient.

Treatments for Disorders of Hyperpigmentation and Hypopigmentation

Hydroquinones and other topical bleaching agents are the most commonly used treatments for melasma and postinflammatory hyperpigmentation. A thorough discussion of treatments for hyperpigmentation is provided in this journal in the article titled "Management of Hyperpigmentation" by Pearl Grimes. Although topical creams have been effective, in the authors' experience, the most effective mechanism for treating dyschromia includes a combination of topical lightening agents, sunscreen, and sun avoidance and in-office procedures, including chemical peels. A summary of chemical peels in ethnic skin is presented in the sections to follow. Other treatments for dyschromia include microdermabrasion, and lasers. The use of lasers for dyschromia is discussed in further detail in this journal in the article titled "The Use of Lasers in Darker Skin Types" by Cylburn Soden and Eliot Battle.

Chemical Peels

Chemical peels have been reluctantly introduced in to the armamentarium of cosmetic treatments in ethnic populations. Treatment of dyschromia with chemical peels has only recently been investigated.⁷⁵ Chemical peels should be performed with great care and caution because the risk of hyperpigmentation and worsening of dyschromia is an all too common consequence and, thus, peels are often paired with topical regimens to minimize potential side effects. The physiological differences in darker-skinned patients mentioned previously, including increased reactivity of melanocytes, larger fibroblasts, and increased melanin content, are features that render increased susceptibility to scarring and dyspigmentation. Peels should be implemented in the treatment of melasma and postinflammatory pigmentation in patients who have tried and failed topical bleaching agents.

The approach to peels in darker skin types should be done with great caution. Patients should be pretreated with hydroquinone, azelaic acid 20% or kojic acid for several weeks before the peel and initial peels should be performed in the lowest concentration to assess sensitivity and reactivity of the skin.⁷⁶ If tretinoin is used before peeling procedures, it should be discontinued 2 to 4 weeks before the peel because it enhances penetration of the peel and thus increases the risk of hyperpigmentation.

Table 7 Chemical Peels

Type of Peel	Depth	Peeling Agents
Superficial	Stratum corneum to papillary dermis	Salicylic acid Glycolic acid 10-70% Jessner's solution (14% resorcinol, 14% salicylic acid, 14% lactic acid, ethanol) TCA 10-30%
Medium	Penetrates upper reticular dermis	TCA 35-50% Undiluted phenol 88% Jessner's 40-50% with TCA 35% Glycolic acid 70% with TCA 35%
Deep	Mid-reticular dermis	Baker Gordon formula (phenol, croton oil, sepiisol, water) TCA >50%

Chemical peels are classified by their depth of skin penetration as superficial, medium-depth, or deep peels (Table 7).⁷⁷ As the depth of the peel increases, so does the risk of dyspigmentation. Every patient regardless of pigmentation has a risk of dyspigmentation and scarring. Thus, it is best to start with superficial peels to minimize potential side effects in susceptible patients. For dyschromia, peels can be done in 2- to 4-week intervals for a series of 3 to 6 peels. If there is no reactivity and increased depth is indicated, titration of the strength is suggested in gradual degrees. Glycolic acid can be started at 20% to 30%, and titrated up to 50% and 70%. Salicylic acid can be started at 10% to 15% and titrated up to 20% to 30%. Gentle postpeel care with mild cleansers and emollients is also important to avoid any residual skin irritation and reactivity. Bleaching agents are then resumed after the peel.

Studies have shown significant benefits in the use of glycolic acid in darker-skinned patients for the treatment of melasma,⁷⁸ acne,⁷⁹ and postinflammatory pigmentary alteration.⁸⁰ Both African-American and Asian patients in these studies had improvement in their skin dyschromias with minimal irritation and postpeel dyspigmentation when titrating doses of the peels were used. In a study by Grimes, salicylic acid was also beneficial in the treatment of postinflammatory pigmentary alteration and melasma when used in 20% to concentrations for a series of 5 peels (2 20% and 3 30% salicylic acid peels). Peels were performed biweekly in titrating doses. Patients were pretreated for 2 weeks with 4% hydroquinone and minimal to mild side effects occurred in 16% of the patients which eventually resolved in 7-14 days.⁸¹

Jessner's is a superficial peel when used alone or is a medium depth peel when used with trichloroacetic acid. Lawrence et al. compared the efficacy of Jessner's solution to 70% glycolic acid or the treatment of melasma in a split-face study of 16 patients. Of the total group, 5 were skin type IV and 3 were skin type V, and one was skin type VI. There was no statistically significant difference in improvement between

the 2 groups. There was no increased frequency of side effects in patients of skin types IV-VI with either treatment.⁸²

Trichloroacetic acid (TCA) is a common peel used in skin types I-III. Its use in darker skin types has been more limited as there are increased risks of post peel hyperpigmentation compared to salicylic acid and glycolic acid. TCA causes a concentration-dependent precipitation of epidermal proteins, causing sloughing and necrosis of the treated area. This peel may be used at concentrations of 10% to 30% if patients fail titrating doses of salicylic acid and glycolic acid peels, but with caution.

Chemical peels are a great adjunct in the treatment of photoaging and dyschromia in darker skinned patients. Mild superficial peels should be used and gradually titrated to optimal therapeutic benefit to minimize irritation and worsening dyspigmentation.

Lasers

Laser technology has advanced significantly in the last 5 years. Initially developed and used in skin types I-III, many lasers now have been developed and used widely in darker skinned patients. Ethnic patients and dermatologists have historically been hesitant to use lasers in darker skin types given risks of scarring and dyspigmentation. There is now more literature validating the efficacy and safety of lasers in darker skin types. Problems specific to ethnic patients conducive to laser treatment include hair removal, including that for pseudofolliculitis barbae, dermatosis papulosa nigra, photoaging, melasma, lentigines, nevus of Ota, Hori's nevus, and tattoo removal. We briefly highlight lasers that have been studied in ethnic skin, however an in-depth review has been dedicated to this topic in this journal.

Pigment Lasers. The treatment of dyschromia in darker skin types is challenging. There is increased melanin in darker skin types. The absorption spectrum of the chromophore melanin is 250-1200 nm, and heavily pigmented skin contains more melanin, thus absorbing laser light high in the epidermis rather than allowing it to reach the deeper targets. This absorption in the epidermis is converted to heat which has the potential to cause epidermal damage and scarring. When comparable fluences are used, the less laser energy reaching the target chromophore in the deep dermis, the less efficacious the treatment. Newer laser devices with better surface cooling, longer pulse durations, and longer wavelengths are now in the armamentarium for safer and more efficacious use in the darker skinned patients.

Despite the increased safety, darker-skinned patients may require more treatments compared with fair-skinned patients and often have refractory skin conditions. Melasma, in particular, is often refractory to laser treatment because melanin incontinence and repackaging is often not altered by laser treatment.

Dermatosis papulosa nigra is common in many darker skin types and is often successfully treated with pigment lasers, such as the 532 nm KTP and 532-nm frequency-doubled Q-switched neodymium: yttrium-aluminum-garnet (Nd:YAG) lasers. Choosing a low fluence and small spot size limits

scarring and surrounding epidermal damage.⁸³ Light electrocautery is also an effective treatment for this condition, with minimal side effects.

A common pigmentary abnormality in Asian and Hispanic patients is the dermal melanocytosis of the Nevus of Ota. Studies have shown benefits from Q-switched ruby, alexandrite, and 1064-nm Nd:YAG lasers. Although reported complication rates are low, similar precautions, including choosing a longer wavelength, longer pulse duration and the shortest fluence for the desired benefit are important to consider to limit epidermal injury.⁸⁴⁻⁸⁶

Tattoo removal in darker-skinned patients is often associated with pigmentary alteration. A candid discussion about realistic expectations is necessary with every patient as treatment sites will have some level of pigmentary alteration. The best laser for blue/black tattoo removal in darker skinned patients is the Q-switched Nd:YAG as it has the longest wavelength resulting in the least risk of scarring and pigmentary alteration. For green/purple tattoos, the Q-switched alexandrite is often used and for red tattoos the 532-nm Q-switched Nd:YAG is the best option. These lasers are absorbed within the absorption spectrum of melanin and once again increase the risk of hypopigmentation and scarring.⁸⁷

Vascular Lasers. Treatment of vascular lesions (port wine stains, telangiectasias, hemangiomas, and veins) in darker-skinned patients is controversial because the absorption spectrum for hemoglobin is within the spectrum of the absorption spectrum for melanin. Scarring and epidermal damage is minimized by the use of lasers with longer wavelengths, such as the Nd:YAG laser. However, the greater the fluence needed to achieve the desired treatment effect, the greater the risk of epidermal damage.^{88,89} Although shorter-wavelength vascular lasers, such as the 595-nm pulse-dye laser, may also absorb melanin in addition to hemoglobin, their use may be required to achieve effective results. If the longer-wavelength lasers are ineffective, a test spot with the shorter-wavelength lasers should be tried first before treating the entire affected area.

Skin Rejuvenation. Skin rejuvenation with ablative resurfacing has been infrequently used in darker skin types because there are significant risks of scarring and dyspigmentation. Newer nonablative resurfacing devices are more favorable alternatives for skin rejuvenation in this population. Test spots should be performed in all patients. Patients are often pretreated with hydroquinone to minimize the risk of post-treatment hyperpigmentation, although the efficacy of pre-laser hydroquinone is debated. Nonablative fractionated techniques, such as the Fraxel Restore device (Solta Medical, Hayward, CA) have been used in skin types III-VI for the treatment of rhytides, acne scarring, and pigmentary changes with some success and minimal complications.⁹⁰⁻⁹² Collagen remodeling is thought to occur with nonablative fractional resurfacing improving skin laxity without epidermal ablation limiting potential epidermal injury. Fraxel Restore is the only laser FDA approved for the treatment of melasma. Fraction-

ated CO₂ lasers are beginning to be used in skin types IV and above, but with extreme caution.

Hair Removal. Ethnic patients frequently request hair removal procedures. Almost every skin type can be treated with hair removal lasers because side effects are minimized with long new longer wavelength lasers, long pulse duration, and effecting skin cooling. The diode and Nd:YAG lasers are the most effective wavelengths to treat darker skin types.^{93,94} Although there are risks of dyspigmentation, they are minimized with adequate precautions. Hair removal in patients with pseudofolliculitis barbae can also be very effective treatment and should be considered despite skin pigmentation. The long pulsed Nd:YAG is the treatment of choice for hirsutism and pseudofolliculitis barbae in African-American patients with Fitzpatrick skin types V and VI.⁹⁵ The wavelength of the Nd:YAG (1064 nm) is at the end of the absorption spectrum of melanin. This wavelength is sufficient to achieve significant thermal injury in dark coarse hairs while sparing epidermal pigment. Additionally, the adjustable pulse width of long pulsed Nd:YAG laser allows the laser energy to be delivered over a longer period allowing for the heat to dissipate and sufficient epidermal cooling to occur. Challenges with the long pulsed Nd:YAG in darker skin types arise in those patients with dark skin but fine hair. In these patients, permanent hair reduction is more challenging because the fluence necessary to achieve permanent reduction of fine hair becomes risky. In these patients, it is important to educate the patient on the potential limitations of laser-assisted hair removal.

The risks of scarring and postinflammatory pigmentary alteration pose a therapeutic challenge in patients with ethnic skin. Although all lasers pose some threat of dyspigmentation and scarring, newer devices with longer wavelengths, more effective contact cooling and longer pulse durations have been developed making lasers safer for use in patients with darker skin. Complications are minimized with clinical experience and patients should be adequately educated about the risk benefit ratio, setting realistic goals, and the need for test spots.

Botox. The chemodenervation of skeletal muscles induced by Botulinum A exotoxin (BoNT-A) has been used for more than 20 years in the treatment of dynamic rhytides. Dynamic facial muscles result in rhytides and deep furrows in all ethnic skin types. The most common cosmetic uses of botulinum toxin are for the treatment of glabellar rhytides, forehead lines, and crow's feet. Studies have illustrated similar benefits in ethnic patients with minimal side effects.⁹⁶ In a study by Ahn, et al,⁹⁷ BoNT-a (Botox, Allergan, Irvine, CA) was effectively used for the treatment of dynamic rhytides in the upper face of Asian patients. Although dermal thickness and fibroblast number may be increased in African Americans, possibly affecting botulinum toxin dosing and response, a study by Carruthers et al⁹⁸ evaluating the use and dose of Botox in African Americans found that there were similar effects and doses used in African-American women compared to Caucasian patients. Similarly, Grimes and Shabazz⁹⁹ also found that

doses of both 20 and 30 U of BoNT-A demonstrate efficacy and safety in African-American women with skin types V and VI. Botox is used commonly in ethnic patients for dynamic rhytides, similar to its use in Caucasians, but has also been used in novel ways in ethnic patients for their unique cosmetic concerns.

In Asian patients, BTX-A can be injected in the lower eyelid to create a wider ocular aperture. This eyelid recontouring is done with very small amounts of the toxin, often 1-2 U of BTX-A into the mid lower lid. Flynn and Carruthers injected Botox into the orbicularis oculi of 15 women. One lower eyelid received 2 U subdermally in midpupillary line 3 mm below ciliary margin, whereas the opposite eye received 2 U in the lower eyelid with 12 U into the lateral crow's feet (3 injections of 4 U each were placed 1.5 cm from the lateral canthus each 1 cm apart). Their results revealed that in 40% of subjects who had injection of lower eyelid alone there was an increased palpebral aperture, whereas 86% of subjects who had injection of the lower eyelid and the lateral orbital area had increased palpebral aperture. In this study there were no reported no side effects, including ectropion, ptosis, dry eyes, or photophobia.¹⁰⁰

Facial beauty in Asian patients is also defined by delicate oval lower face structure. Korean patients often have a bony malar or mandibular prominence or masseter muscular hypertrophy giving their lower face a more squared appearance. When bony hypertrophy is the culprit, skeletal reduction surgery is the procedure of choice and is a popular technique in Asia.¹⁰¹ However, muscular hypertrophy and a prominent mandibular angle can be altered with chemodenervation of the masseter muscle.^{102,103} Approximately 25 U of Botox, 5 U/0.1 mL is injected at the inferior masseter border. Some practitioners will inject an additional 25 U injected per side at 1-week intervals to ensure optimal paralysis, with maintenance reinjections at 6 and 8 months. Most patients will only require 2 to 3 consecutive treatments, and only patients who have residual masseter motion require reinjection.¹⁰⁴ Side effects include mild fatigue with chewing and transient buccal weakness. It is important to only inject the lower portion of the masseter and avoid injection in the upper half to avoid complete masseter paralysis.

In Japan, calf hypertrophy is referred to as "daikon-ashi" and in Korea it is called "muu-dari." Similar to masseter hypertrophy, injection of the gastrocnemius muscle with Botox causing a chemical denervation of the muscle can help decrease calf volume.^{105,106}

Injectable Filling Agents. The nonsurgical treatment of volume loss of the lower face is becoming increasingly common in ethnic patients. Darker-skinned patients develop significantly more volume loss in the lower face compared with deep furrows and rhytides of the lower face seen in Caucasian patients.¹⁰⁷ There are many different soft-tissue fillers on the market, all of which have been safely used in darker-skinned patients. As with all procedures, there are risks of postinflammatory pigmentary alteration even after minor injection related trauma. With all soft-tissue augmentation products, the correct injection strategies, including tissue depth and

proper injection technique, are necessary to minimize potential adverse outcomes. Furthermore, skin properties of ethnic patients, including thicker skin and darker pigment, are important to consider preinjection to ensure proper filler choice and placement. Pre and post treatment cold compresses help prevent bruising similar to lighter skin types.

Multiple injection techniques have been suggested, including linear threading, serial puncture, serial threading, fan technique, and crosshatching. Some studies have suggested that serial threading, fanning, and cross hatching minimize multiple injections and thus decrease the potential for additional trauma. Although edema and erythema are common at injection sites in all skin types, no studies have suggested any additional benefit for reducing erythema and edema via any of these techniques in darker skin types. There have been no reports of long term scarring or keloid formation in ethnic patients treated with fillers.

Oduaze et al¹⁰⁸ reported 60 patients with Fitzpatrick skin type IV-VI injected with Restylane (Q-med Esthetics Stockholm, Sweden) and distributed in the United States by Medicis Pharmaceutical Corporation, (Scottsdale, AZ) to evaluate adverse outcomes, including hypersensitivity, scar formation, altered pigmentation, and contour irregularities. In patients with skin types IV-VI, there was no increased hyperpigmentation or scarring at injection sites.

In recent years, the beauty trend has shifted toward the desire for more voluminous lips. African-American women accept and enjoy enhancing this unique ethnic trait. Technique for lip augmentation, however, slightly differs in African-American women. African-American women develop rhytides below the vermilion border due to loss of lip volume with age. This is in comparison to Caucasian women who develop lip thinning and longitudinal rhytides above and below the vermilion border because of a thinning dermis, volume loss, and activity of the orbicularis oris muscle. Thus, placement of fillers is unique in African-American women depending on the mechanism of aging. Choice of filler for lip augmentation may also differ. Collagen fillers can often provide a more natural appearance than hyaluronic acid fillers in an already full ethnic lip in the opinion of the authors. However, the current collagen fillers available for use in the United States for the lip have a much shorter duration of action than the hyaluronic acid fillers, and Evolence (Orthonetrogena esthetics, Skillman, NJ) available in the United States, although longer lasting, is too thick for the lips and can result in nodule formation. Evolence Breeze (ColBar LifeScience Ltd., Hertzelia, Israel) once approved for use in the United States, may prove to be a useful thinner collagen filler with a longer duration for lip augmentation in already full lips based on its efficacy in other countries.

Body Image and Contouring

Body contours also have ethnic variation. Many Hispanic and African-American patients opt for fuller legs, thighs, and hips in comparison with more delicate and thinner contour preferred by Asian patients. Natural ethnic variations of the hips and thighs in African/African-American and Brazilian women

have been embraced by these cultures with more cosmetic procedures being performed to enhance these features.

Tumescent liposuction is a common procedure among all ethnicities. Hypertrophic scars, keloids, and hyperpigmentation are risks in ethnic patients at cannula insertion sites. Ultrasound-assisted liposuction, laser-assisted liposuction, and selective cryolysis are more novel techniques, the efficacy of which, are still being studied in ethnic patients.^{109,110}

Gluteal enhancement, initially popularized in Brazil, has been performed most commonly via use of implants and a combination of liposuction/autologous mini fat grafting procedures.^{111,112} Potential complications of excessive liposuction in the gluteal area are the banana fold and sensuous triangle deformity. The “banana fold”, or the infragluteal fold, is a fat deposit on the posterior thigh near the gluteal crease and parallel to it. The “sensuous triangle” is found at the junction of the lateral buttocks, the lateral thigh, and the posterior thigh. Correction of these iatrogenic deformities via autologous fat transplantation has been described by Brazilian plastic surgeons.¹¹³

Methods for treating cellulite have also been described in ethnic patients, predominately in Brazil. Techniques for cellulite reduction include topical application of caffeine, botanical extracts, endermologie, mesotherapy, radiofrequency delivery, and subcision.¹¹⁴⁻¹¹⁸ A novel noninvasive technology for circumference and cellulite reduction is a device that combines Bi-polar radiofrequency, infrared Light, Vacuum and Mechanical Massage (VelaShape, Syneron, Inc., Irvine, CA). At the time of this writing, there are no published reports of the use of VelaShape in ethnic patients in peer-reviewed journals.¹¹⁹

Hair Transplantation

Hair transplantation is performed at a lower frequency in African-American men with male pattern hair loss in than in white men,¹²⁰ It has also become more culturally acceptable for African-American men to shave their heads bare as a way to camouflage androgenetic alopecia. If hair transplantation is a consideration, caution must be taken in African-American men for development of keloids, particularly at the donor site. It is suggested that test grafts are performed with a 3 month wait before proceeding with procedure.

Modification in technique has been proposed for very curly hair in African Americans. Modifications include the use of larger 4-mm punch grafts and manual removal of the donor grafts instead of mechanical removal to prevent transection of the hair follicles.¹²¹ In addition, adding saline to the donor sites after infiltration with local anesthesia may help straighten the curly follicle and provide more viable hair for transplantation.¹²²

Conclusion

The perception of beauty is determined by genetics, cultural, environmental, and historical influences. Skin of color comprises a phenotypically heterogeneous group of patients. Understanding unique differences in skin physiology, aging mechanisms, and treatment options are an important part of

the care of ethnic patients. Ethnocentric beauty is one that should be celebrated. More ethnic patients are requesting esthetic procedures than ever before, however they do not all necessarily desire "westernized" appearances. They often wish to enhance their culture-specific beauty. The understanding of these culture and ethnic-specific features is the first step in taking care of ethnic patients and using specialized esthetic approaches to their care.

References

- US Census Bureau. Population projections of the US by age, sex, race and Hispanic origin: 1995-2050. Current population report: 25-1130. Washington, DC, US Government Press, 2002
- Porter JP, Lee JI: Facial analysis: Maintaining ethnic balance. *Facial Plast Surg Clin North Am* 10:343-349, 2002
- American Society of Aesthetic Plastic Surgery. Cosmetic Surgery National Data Bank. American Society for Aesthetic Plastic Surgery, 2005, pp 1-20
- Berardesca E, Maibach H: Racial differences in skin pathophysiology. *J Am Acad Dermatol* 34:667-672, 1996
- Carter EL: Race vs ethnicity in dermatology. *Arch Dermatol* 139:539-540, 2003
- Elgart ML, Silver SE, Taylor SC: Defining skin of color. *Cutis* 71:142-143, 2003
- Johnson LC, Corah NL: Racial differences in skin resistance. *Science* 139:766-767, 1963
- McKenzie K, Crowcroft NS: Describing race, ethnicity, and culture in medical research. *BMJ* 312:1054, 1996
- Kaplan JB, Bennett T: Use of race and ethnicity in biomedical publication. *JAMA* 289:2709-2716, 2003
- Fitzpatrick TB: The validity and practicality of skin reactive skin type I through VI. *Arch Dermatol* 124:869-871, 1988
- Lancer HA: Lancer Ethnicity Scale (LES). *Lasers Surg Med* 22: 9, 1998
- Toda K, Patnak MA, Parrish A, et al: Alteration of racial differences in melanosome distribution in human epidermis after exposure to ultraviolet light. *Nat New Biol* 236:143-145, 1972
- Olson RL, Gaylor J, Everett MA: Skin color, melanin, and erythema. *Arch Dermatol* 108:541-544, 1973
- Smit NP, Kolb RM, Lentjes EGWM, et al: Variations in melanin formation by cultured melanocytes from different skin types. *Arch Dermatol Res* 290:342-349, 1998
- Alaluf S, Atkins D, Barrett K, et al: Ethnic variation in melanin content and composition in photoexposed and photoprotected human skin. *Pigment Cell Res* 15:112-118, 2002
- Bohm M, Wolff I, Scholzen TE, et al: Alpha-melanocyte-stimulating hormone protects from ultraviolet radiation-induced apoptosis and DNA damage. *J Biol Chem* 280:5795-5802, 2005
- Sugino K, Imokawa G, Maibach HI: Ethnic differences in stratum corneum lipid in relation to stratum corneum function. *J Invest Dermatol* 100:594, 1993 (abstr)
- Berardesca E, de Rigo J, Leveque JL, et al: In vivo biophysical characterization of skin physiological differences in races. *Dermatologica* 182:89-93, 1991
- Montagna W, Carlisle K: The architecture of black and white facial skin. *J Am Acad Dermatol* 24:929-937, 1991
- Wesley NO, Maibach HI: Racial (ethnic) differences in skin properties: The objective data. *Am J Clin Dermatol* 4:843-860, 2003
- Sugiyama-Nakagiri Y, Sugata K, Hachiya A, et al: Ethnic differences in the structural properties of facial skin. *J Dermatol Sci* 53:135-139, 2009
- Glogau RG: Aesthetic and anatomic analysis of the aging skin. *Semin Cutan Med Surg* 15:134-138, 1996
- Kligman LH, Kligman AM: The nature of photoaging: Its prevention and repair. *Photodermatology* 3:215-227, 1986
- Gartsetin V, Kligman AM, Montagna W, et al: Age, sunlight, and facial skin: A histologic and quantitative study. *J Am Acad Dermatol* 25: 751-760, 1991
- Halder RM, Ara CJ: Skin cancer and photoaging in ethnic skin. *Dermatol Clin* 21:725-723, 2003
- Kaidbey KH, Agin PP, Sayre RM, et al: Photoprotection by melanin: A comparison of black and Caucasian skin. *J Am Acad Dermatol* 1:249-260, 1979
- Kligman AM: Solar elastosis in relation to pigmentation, in: Fitzpatrick TB, et al (eds): *Sunlight and Man*. Tokyo, University of Tokyo Press, 1974, pp 157-163
- Nouveau-Richard S, Yang Z, Mac-Mary S, et al: Skin aging: A comparison between Chinese and European populations: A pilot study. *J Dermatol Sci* 40:187-193, 2005
- Morizot F, Guehenneux S, Dheurle S, et al: Do features of aging difference between Asian and Caucasian women. *J Invest Dermatol* 123:A67, 2004
- Hillebrand GG, Miyamoto K, Schnell B, et al: Quantitative evaluation of skin condition in an epidemiological survey of females living in northern versus southern Japan. *J Dermatol Sci* 27:542-552, 2001
- Kligman AM, Grove GL, Hirose R, et al: Topical tretinoin for photoaged skin. *J Am Acad Dermatol* 15:836-859, 1986
- Weiss JS, Ellis CN, Headington JT, et al: Topical tretinoin improves photoaged skin. *JAMA* 259:527-532, 1998
- Kotrajaras R, Kligman AM: The effect of topical tretinoin on photo-damaged facial skin. The Thai experience. *Br J Dermatol* 129:302-309, 1993
- Griffiths CEM, Goldfarb MT, Finkel LJ, et al: Topical tretinoin (retinoic acid) treatment of hyperpigmented lesions associated with photoaging in Chinese and Japanese patients: A vehicle-controlled study. *J Am Acad Dermatol* 30:76-84, 1994
- Burgess CM: Soft tissue augmentation in skin of color: Market growth, available fillers, and successful techniques. *J Drugs Dermatol* 6:51-55, 2007
- Powell N, Humphreys B: Proportions of the aesthetic face. Thieme-Stratton, New York, 1984
- Farkas LG: Vertical and horizontal proportions of the face in young adult North American Caucasians: Revision of the neoclassical canons. *Plast Reconstr Surg* 75:328-337, 1985
- Matory WE Jr: Definitions of beauty in the ethnic patient. In Matory WE Jr., ed: *Ethnic Considerations in Facial Aesthetic Surgery*. Philadelphia, Lippincott-Raven Publishers, 1998, pp 61-83
- Holland E: Marquardt's Phi mask: Pitfalls of relying on fashion models and the golden ratio to describe a beautiful face. *Aesthetic Plast Surg* 32:200-208, 2008
- Grimes PE, Beauty A: Historical and Societal Perspective, in: Grimes PE, Kim J, Hexsel D, Soriano T (eds): *Aesthetics and Cosmetic Surgery for Darker Skin Types*. Philadelphia, Lippincott Williams & Wilkins, 2007, p 8
- Website of Dr. Stephen Marquardt. Available at: http://www.beautyanalysis.com/index2_mba.htm. Accessed May 22, 2009
- Farkas LG: Revision of neoclassical canons in young adult Afro-Americans. *Aesth Plast Surg* 24:179-184, 2000
- Grimes PE: Beauty: A historical and societal perspective, in: Grimes PE, Kim J, Hexsel D, Soriano T (eds): *Aesthetics and Cosmetic Surgery for Darker Skin Types*. Philadelphia, Lippincott Williams & Wilkins, 2007, p 9
- Porter JP, Olson KL: Anthropometric facial analysis of the African American female. *Arch Facial Plastic Surg* 3:191-197, 2001
- Matory WE: Aging in people of color, in: Matory WE (ed): *Ethnic Considerations in Facial Aesthetic Surgery*. Philadelphia, PA, Lippincott-Raven, 1998, pp 151-70
- Ortiz-Monasterio F, Olmedo A: Rhinoplasty on the Mestizo nose. *Clin Plast Surg* 4:89-102, 1977
- Sanchez AE: Rhinoplasty in the "Chata" nose of the Caribbean. *Aesth Plast Surg* 4:169-177, 1980
- Milgrim LM, Lawson W, Cohen AF: Anthropometric analysis of the female Latino nose: revised aesthetic concepts and their surgical implications. *Arch Otolaryngol Head Neck Surg* 122:1079-1086, 1996
- Crumley RL, Lanser M: Quantitative analysis of nasal tip projection. *Laryngoscope* 98:202-208, 1988

50. Grimes PE, Beauty A: Historical and Societal Perspective, in: Grimes PE, Kim J, Hessel D, Soriano T (eds): *Aesthetics and Cosmetic Surgery for Darker Skin Types*. Philadelphia, Lippincott Williams & Wilkins, 2007, p 10
51. Wang D, Qian G, Zhang M, et al: Differences in horizontal, neoclassical facial canons in Chinese (Han) and North American Caucasian populations. *Aesth Plastic Surg* 21:265-269, 1997
52. Shirakabe Y: A new paradigm for the aging Asian face. *Aesthetic Plastic Surg* 27:397-402, 2003
53. Lam SM, Kim YK: The partial-incision technique for the creation of the double eyelid. *Aesthetic Surg* 23:170-176, 2003
54. McCurdy JA: *Cosmetic surgery of the Asian face*. New York, Thieme Medical Publishers, 1990
55. Dawei W, Guozheng Q, Mingli Z, et al: Differences in horizontal, neoclassical facial canons in Chinese (Han) and North American Caucasian populations. *Aesth Plast Surg* 21:265-269, 1997
56. Sim RS, Smith JD, Chan AS: Comparison of the aesthetic facial proportions of southern Chinese and white women. *Arch Facial Plast Surg* 2:113-120, 2000
57. Choe KS, Sclafani AP, Litner JA, et al: The Korean American woman's face: Anthropometric measurements and quantitative analysis of facial aesthetics. *Arch Facial Plast Surg* 6:244-252, 2004
58. Biller JA, Kim DW: A contemporary assessment of facial aesthetic preferences. *Arch Facial Plast Surg* 11:91-97, 2009
59. Farkas LG, Kolar JC: Anthropometrics and art in the aesthetics of women's faces. *Clin Plast Surg*. 1987;14:599-616
60. Prasad A: Ethnic considerations in eyelid surgery. *Plast Surg Prod* 12:34-36, 2002
61. Lee JS, Park YW: Intraoral approach for reduction malarplasty: A simple method. *Plast Reconstr Surg* 111:453-460, 2003
62. Choe KS, Sclafani AP, Litner JA, et al: The Korean American woman's face: Anthropometric measurements and quantitative analysis of facial aesthetics. *Arch Facial Plast Surg* 6:244-252, 2004
63. Grimes PE: Beauty: A Historical and Societal Perspective, in: Grimes PE, Kim J, Hessel D, Soriano T (eds): *Aesthetics and Cosmetic Surgery for Darker Skin Types*. Philadelphia, Lippincott Williams & Wilkins, 2007, p 9
64. Ying Mak AK: Advertising whiteness: An assessment of skin color preferences among urban Chinese. *Visual Communication Q* 14:144-157, 2007
65. Martin P: Skin whitening big business in Asia. *PR's The World*. March 11, 2009. Available at: <http://www.theworld.org/node/25036>. Accessed May 22, 2009
66. Buchanan DC: *Japanese proverbs and sayings*. Norman and London, University of Oklahoma Press, 1965, p 265
67. Grimes PE: Beauty: A Historical and Societal Perspective, in: Grimes PE, Kim J, Hessel D, Soriano T (eds): *Aesthetics and Cosmetic Surgery for Darker Skin Types*. Philadelphia, Lippincott Williams & Wilkins, 2007, p 9
68. Ruiz-Maldonado R, Orozco-Covarrubias M: Postinflammatory hypopigmentation and hyperpigmentation. *Semin Cutan Med Surg* 16:36-43, 1997
69. Morelli JG, Kincannon J, Yohn JJ, et al: Leukotriene C and TGF-alpha are stimulators of human melanocyte migration in vitro. *J Invest Dermatol* 98:290-295, 1992
70. Tomita Y, Maeda K, Tagami H: Melanocyte-stimulating properties of arachidonic acid metabolites: Possible role in postinflammatory pigmentation. *Pigment Cell Res* 5:357-361, 1992
71. Gilchrist BA: Localization of melanin pigmentation in skin with Wood's lamp. *Br J Dermatol* 96:245-247, 1977
72. Grimes PE: Melasma: Etiologic and therapeutic considerations. *Arch Dermatol* 131:1453-1457, 1995
73. Perez M, Sanchez JL, Aguilo F: Endocrinologic profile of patients with idiopathic melasma. *J Invest Dermatol* 81:543-545, 1983
74. Varma S, Roberts DL: Melasma of the arms associated with hormone replacement therapy. *Br J Dermatol* 141:592, 1999
75. Lim JT, Tham SN: Glycolic acid peels in the treatment of melasma in Asian women. *Dermatol Surg* 23:177-179, 1997
76. Grimes PE: The safety and efficacy of salicylic acid chemical peels in darker racial-ethnic groups. *Dermatol Surg* 25:18, 1999
77. Coleman WP, Brady HJ: Advances in chemical peeling. *Adv Clin Res* 15:19-26, 1997
78. Lim JT, Tham SN: Glycolic acid peels in the treatment of melasma in Asian women. *Dermatol Surg* 20:27-34, 1997
79. Wang CM, Huang CL, Hu CT, et al: The effects of glycolic acid on the treatment of melasma among Asian skin. *Dermatol Surg* 23:23-29, 1997
80. Burns RI, Provost-Blank PC, Lawry MA, et al: Glycolic acid peels for post inflammatory hyperpigmentation in black patients: a comparative study. *Dermatol Surg* 23:171-174, 1997
81. Grimes PE: The safety and efficacy of salicylic acid chemical peels in darker racial-ethnic groups. *Dermatol Surg* 25:18-22, 1999
82. Laurence NL, Cox SE, Brady HJ: Treatment of melasma with Jessner's solution versus glycolic acid: A comparison of clinical efficacy and evaluation of the predictive ability of Wood's light examination. *J Am Acad Dermatol* 36:589-593, 1977
83. Spoor TC: Treatment of dermatosis papulosis nigra with the 532 nm diode laser. *Cosmet Dermatol* 14:21-23, 2001
84. Chan HH, Leung RS, Ying SY, et al: A retrospective analysis of complications in the treatment of nevus of Ota with the Q-switched alexandrite and Q-switched Nd:YAG lasers. *Dermatol Surg* 26:1000-1006, 2000
85. Chan HH, Lam LK, Wong DS, et al: Nevus of Ota: A new classification based on the response to laser treatment. *Lasers Surg Med* 28:267-272, 2001
86. Watanabe S, Takahashi H: Treatment of nevus of Ota with the Q switched ruby Laser. *N Engl J Med* 331:1745-1750, 1994
87. Jones A, Roddey P, Orengo I, et al: Q switched Nd: YAG laser effectively treats tattoos in darkly pigmented skin. *Dermatol Surg* 22:999-1001, 1996
88. Garret AB, Shieh S: Treatment of vascular lesions in pigmented skin with the pulsed dye laser. *J Cutan Med Surg* 4:36-39, 2000
89. Ho WS, Chan HH, Ying SY, et al: Laser treatment of congenital facial port wine stains: long term efficacy and complication in Chinese patients. *Lasers Surg Med*. 30:44-47, 2002
90. Lee HS, Lee JH, Ahn G, et al: Fractional photothermolysis for the treatment of acne scars: a report of 27 Korean patients. *J Dermatol Treatment* 19:45-49, 2008
91. Graber EM, Tanzi EL, Alster TS: Side effects and complications of fractional laser photothermolysis: Experience with 961 treatments. *Dermatol Surg* 34:301-307, 2008
92. Kono T, Chan HH, Groff W, et al: Prospective direct comparison study of fractional resurfacing using different fluences and densities for skin rejuvenation in Asians. *Lasers Surg Med* 39:311-314, 2007
93. Alster TS, Bryan H, Williams CM: Long-pulsed Nd: YAG laser-assisted hair removal in pigmented skin: a clinical and histological evaluation. *Arch Dermatol* 137: 885-889, 2001
94. Campos V, Dierickx C, Farinelli B, et al: Hair removal with an 800-nm pulsed diode laser. *J Am Acad Dermatol* 43:442-447, 2000
95. Ross EV, Cooke LM, Timko AL, et al: Treatment of pseudofolliculitis barbae in skin types IV, V, and VI with a long-pulsed neodymium: yttrium aluminum garnet laser. *J Am Acad Dermatol* 47:263-267, 2002
96. Lew H, Yun YS, Lee SY, et al: Effect of botulinum toxin A on facial wrinkle lines in Koreans. *Ophthalmologica* 216:50-54, 2002
97. Ahn KY, Park MY, Park DH, et al: Botulinum toxin A for the treatment of facial hyperkinetic wrinkle lines in Koreans. *Plast Reconstr Surg* 105:778-784, 2000
98. Carruthers JA, Lowe NJ, Menter MA, et al: A multicenter, double-blind, randomized, placebo-controlled study of the efficacy and safety of botulinum toxin type A in the treatment of glabellar lines. *J Am Acad Dermatol* 46: 840-849, 2002
99. Grimes PE, Shabazz D: A four-month randomized, double-blind evaluation of the efficacy of botulinum toxin type A for the treatment of glabellar lines in women with skin types V and VI. *Dermatol Surg* 35:429-435; discussion 435-436, 2009

100. Flynn TC, Carruthers JA, Carruthers JA: Botulinum A toxin treatment of the lower eyelid improves infraorbital rhytides and widens the eye. *Dermatol Surg* 27:703-708, 2001
101. Choi HY, Lee SW, Lew JM: True intraoral reduction malarplasty with a minimally invasive technique. *Aesthetic Plast Surg* 23:354-360, 1999
102. To EW, Ahuja AT, Ho WS, et al: A prospective study of the effect of botulinum toxin A on masseteric muscle hypertrophy with ultrasonographic and electromyographic measurement. *Br J Plast Surg* 54:197-200, 2001
103. Kim NH, Chung JH, Park RH, et al: The use of botulinum toxin type A in aesthetic mandibular contouring. *Plast Reconstr Surg* 115:919-930, 2006
104. Ahn J, Horn C, Blitzer A: Botulinum toxin for masseter reduction in Asian patients. *Arch Facial Plast Surg* 6:188-191, 2004
105. Lee HJ, Lee DW, Park YH, et al: Botulinum toxin A for aesthetic contouring of enlarged medial gastrocnemius muscle. *Dermatol Surg* 30: 867-871, 2004
106. Han KH, Joo YH, Moon SE, et al. Botulinum toxin A treatment for contouring of the lower leg. *J Dermatol Treat* 17:250-254, 2006
107. Burgess CM: Soft tissue augmentation in skin of color: Market growth, available fillers, and successful techniques. *J Drugs Dermatol* 6:51-55, 2007
108. Odunze M, Cohn A, Few J: Restylane in people of color. *Plast Reconstr Surg* 120:2011-2016, 2007
109. Goldman A: Submental Nd:Yag laser-assisted liposuction. *Lasers Surg Med* 38:181-184, 2006
110. Manstein D, Laubach H, Watanabe K, et al: Selective cryolysis: A novel method of non-invasive fat removal. *Lasers Surg Med* 40:595-604, 2008
111. Harrison D, Selvaggi G: Gluteal augmentation surgery: indications and surgical management. *J Plast Reconstr Aesthet Surg* 60:922-928, 2007
112. Roberts TL 3rd, Weinfeld AB, Bruner TW, et al: "Universal" and ethnic ideals of beautiful buttocks are best obtained by autologous micro fat grafting and liposuction. *Clin Plast Surg* 33:371-394, 2006
113. Pereira LH, Sterodimas A: Correction for the iatrogenic form of banana fold and sensuous triangle deformity. *Aesthetic Plast Surg* 32: 923-927, 2008
114. Velasco MV, Tano CT, Machado-Santelli GM, et al: Effects of caffeine and siloxanetriol alginate caffeine, as anticellulite agents, on fatty tissue: histological evaluation. *J Cosmet Dermatol* 7:23-29, 2008
115. Hexsel D, Orlandi C, Zechmeister do Prado D: Botanical extracts used in the treatment of cellulite. *Dermatol Surg* 31:866-872, 2005
116. Monteux C, Lafontan M: Use of the microdialysis technique to assess lipolytic responsiveness of femoral adipose tissue after 12 sessions of mechanical massage technique. *J Eur Acad Dermatol Venereol* 22: 1465-1470, 2008
117. Alexiades-Armenakas M, Dover JS, Arndt KA: Unipolar radiofrequency treatment to improve the appearance of cellulite. *J Cosmet Laser Ther* 10:148-153, 2008
118. Hexsel DM, Mazzuco R: Subcision: A treatment for cellulite. *Int J Dermatol* 39:539-544, 2000
119. Romero C, Caballero N, Herrero M, et al: Effects of cellulite treatment with RF, IR light, mechanical massage and suction treating one buttock with the contralateral as a control. *J Cosmet Laser Ther* 10:193-201, 2008
120. Callender VD, McMichael AJ, Cohen GF: Medical and surgical therapies for alopecias in black women. *Dermatol Ther* 17:164-176, 2004
121. Pierce HE: The uniqueness of hair transplantation in black patients. *J Derm Surg Oncol* 3:533-535, 1977
122. Pierce HE: *Cosmetic Plastic Surgery in Non-White Patients*, New York, Grune & Stratton, 1982, pp 70-75