

# Role of Phototherapy in Patients with Skin of Color

Zain U. Syed, MD, and Iltefat H. Hamzavi, MD

Phototherapy has proven to be one of the most versatile and effective treatment options for a variety of inflammatory and pigmentary skin diseases. However, the use of these treatment modalities in patients of color requires some special considerations. The modality chosen, the dosing of the treatment and duration of treatment are all issues to be considered for patients of color treated with ultraviolet phototherapy. In addition, there are some diseases which are more commonly seen in patients of color. These diseases may have better treatment outcomes using newer phototherapeutic options such as the long pulsed Nd:YAG laser or UVA1. As our population in the United States becomes more diverse it would behoove all dermatologists to acquaint themselves with the special circumstances of treating ethnic patients with phototherapy.

Semin Cutan Med Surg 30:184-189 © 2011 Elsevier Inc. All rights reserved.

**KEYWORDS** psoriasis, atopic dermatitis, vitiligo, hidradenitis suppurative, phototherapy, skin of color

Phototherapy is a mainstay of treatment in many dermatologic conditions. It most commonly consists of ultraviolet (UV), visible light, or infrared (IR) radiation in the treatment of disease. The spectrum of light may be broadband, narrowband, or monochromatic and may be in the form of a laser. In addition, phototherapy can be used in conjunction with a chemical agent, either topical or oral. The spectrum of light chosen for phototherapy greatly influences its therapeutic applications.

Phototherapy presents a unique set of treatment approaches to the skin of patients of color. There are increased amounts of melanin in these patients, and therefore increased dosing in phototherapy may be required for treatments to be effective. In addition, there are several adverse effects, such as hyperpigmentation after phototherapy, that may be more pronounced in the skin of patients of color. This may limit the dosing of phototherapy for these patients.

This article presents a review of phototherapy for use in psoriasis, atopic dermatitis, vitiligo, and hidradenitis suppu-

rativa. A specific focus will be placed on treating these conditions in patients with skin of color.

## Psoriasis

Psoriasis is a chronic inflammatory condition characterized by red, scaly, pruritic plaques appearing on the extensor surfaces of the body, such as the elbows and knees. It also may occur on the abdomen (particularly around the umbilicus) and scalp. It has a worldwide prevalence of approximately 2%, whereas studies have shown that it is slightly less prevalent among African-American than Caucasian patients in the United States (1.3% vs 2.5%).<sup>1</sup> The etiology of psoriasis is thought to be immunologically related but has not been fully elucidated.

Phototherapy is one of the leading treatments for patients with psoriasis that covers more than 10% of the body surface area. At this stage, topical treatments, such as corticosteroids and calcineurin inhibitors become inconvenient. Although other systemic treatments may be useful for psoriasis, such as methotrexate, cyclosporine, and biologics, phototherapy generally has a better side effect profile and may be a cheaper option. The most common forms of phototherapy for psoriasis are psoralens plus UVA (PUVA), broadband UVB (BB-UVB), and narrowband UVB (NB-UVB).

PUVA therapy, which is more accurately described as a form of photochemotherapy, is the combination of UVA radiation (320-400 nm) with psoralens, an oral photo-sensitizing agent. The most commonly available form of psoralens in the United States is 8-methoxypsoralen.<sup>2</sup> The authors of sev-

Department of Dermatology, Multicultural Dermatology Center, Henry Ford Hospital, Detroit, MI.

*Conflict of Interest Disclosures:* Dr Hamzavi has served as an investigator for Dow Pharmaceuticals, Basilea, Galderma, Abbott, Pfizer, Fujisawa, and Cipher. He has served as a consultant to Kythera and Daavlin. This review was supported in part by the C. S. Livingood Lectureship and Education Fund and the R. and C. Shahani Fund of the Department of Dermatology, Henry Ford Hospital, Detroit, MI.

Address reprint requests to Iltefat Hamzavi, MD, Department of Dermatology, Henry Ford Hospital, Detroit, MI. E-mail: [ihamzav1@hfhs.org](mailto:ihamzav1@hfhs.org)

eral large studies have shown the efficacy of PUVA for use in psoriasis,<sup>3,4</sup> with approximately 89% of patients achieving clearance. In addition to oral PUVA therapy, topical PUVA can also be used to treat psoriasis. Bath PUVA, a form of topical PUVA, has been shown in many European studies to be as effective as oral PUVA but, because of the direct contact of psoriatic lesions with psoralens, requires a much lower cumulative dose of UVA.<sup>5-8</sup> Acute adverse effects of PUVA therapy include erythema, pruritis, xerosis, irregular pigmentation, and nausea and vomiting.<sup>2</sup> Longer-term effects include an increased chance of squamous cell carcinoma<sup>9</sup> and a theoretically increased chance of cataract formation, although studies have not shown any increased incidence of visual impairment.<sup>10</sup>

In the skin of patients of color, the risk of hyperpigmentation after PUVA therapy is of great concern because the skin of these patients is much more melanocompetent. A study in 2008 by El-Mofty et al<sup>11</sup> suggests that using twice-weekly dosing versus thrice-weekly dosing for PUVA therapy does not change efficacy as determined by the psoriasis area and severity index score, but decreases the cumulative dose of UVA significantly.<sup>11</sup> Studies into dosing of NB-UVB have shown that although twice-weekly dosing maybe effective, longer treatments are usually required.<sup>12</sup>

BB-UVB uses the entirety of the UVB spectrum (254-313 nm) and has been used for many decades as a treatment for psoriasis. In previous studies authors demonstrated the efficacy of BB-UVB,<sup>13,14</sup> but NB-UVB is generally considered preferable because of the superior results in many half-body comparison studies.<sup>15-17</sup> The adverse effects of BB-UVB and NB-UVB are similar in nature, and include erythema, pruritis, burning and stinging.<sup>2</sup> Long-term side effects include photoaging, wrinkling, and lentigines. Although there is a theoretically increased chance for carcinogenesis, the authors of a review found no significant increase in squamous cell carcinoma, basal cell carcinoma, or melanoma in a follow-up period of 5.5 years.<sup>18</sup> When compared with oral PUVA, NB-UVB has been shown to achieve similar rates of clearance, but it required more frequent treatment sessions.<sup>19</sup> In addition, NB-UVB has been shown to have fewer adverse effects than oral PUVA.<sup>20</sup>

With darker-skinned patients, there may be a push by practitioners to increase the dose of NB-UVB to achieve erythrogenic levels. However, the authors of a recent study suggest that in darker-skinned individuals, suberythrogenic doses of NB-UVB are just as effective (same PASI score) as erythrogenic doses.<sup>21</sup> Thus, there is no need for pushing greater doses to achieve similar efficacy rates.

## Atopic Dermatitis

Atopic dermatitis (AD) is a chronic, relapsing, eczematous dermatitis affecting patients of all ages, although typically it begins at a young age. AD typically appears acutely on the extensor surfaces as erythematous, scaling, and possibly vesicular papules to plaques. In patients with chronic AD, the flexural surfaces may have a thickened, lichenified look. It can be extremely pruritic and cause sufficient distress to

those affected. The prevalence of AD is approximately 10% across the United States, with variation on the location studied. In addition, people with dark-pigmented skin have a greater disease prevalence (odds ratio 1.70).<sup>22</sup> It is associated with patients who have a history of asthma and allergies (atopy). The exact cause of AD is unknown, but it is associated with defects in skin barrier function, as well as increased hypersensitivity to allergens.

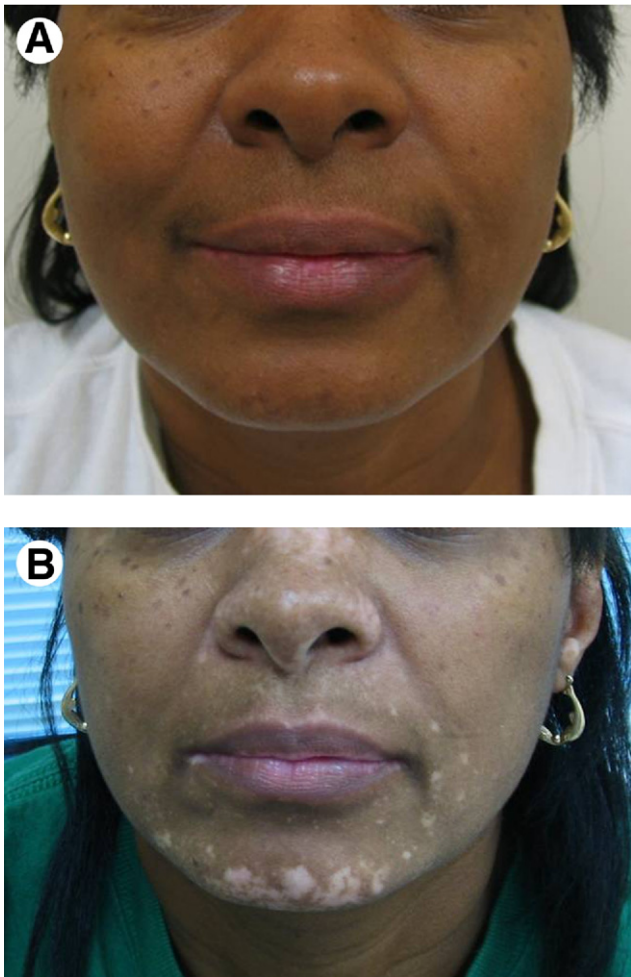Patients suffering from AD tend to improve when exposed to sunny conditions, and therefore artificial sunlight in the form of UV radiation has been used as a treatment approach. Broadband UV, NB-UVB, and UVA1 (340-400 nm) have all been used as modalities in treating AD. UVA1 has been shown to provide good results for many skin conditions, including AD, specifically for acute exacerbations.<sup>23</sup> Several authors have shown that UVA1 performs better than broadband UVA plus UVB for acute exacerbations of severe AD.<sup>24-26</sup> In addition, the dosing for UVA1 should fall between 50 and 100 J/cm<sup>2</sup> per treatment at 5 times per week, with studies showing that doses closer to 50 J/cm<sup>2</sup> have similar efficacy but lower cumulative dose and side effects when compared with greater dosing schemes.<sup>27,28</sup> In all studies, the first week of treatment showed the greatest reduction in symptoms.<sup>24-28</sup> It was noted in a study at our institution that darker skinned patients tend not to respond as well as patients with lighter skin.<sup>23</sup>

In terms of treating chronic AD, early studies showed some benefit to using a combined approach of UVA and UVB because it tended to have better results when compared with UVB alone.<sup>29,30</sup> Neither of these studies had control areas with no treatment, and therefore it is difficult to determine what systemic effects may have been present. The authors of other studies compared NB-UVB with both broadband UVA and UVA1 and showed that thrice-weekly NB-UVB decreased pruritis and improved sleep better than UVA or UVA1, with trends towards better disease control.<sup>31,32</sup>

There are few reports on the use of phototherapy in darker skin types. In the authors' experience, there does not appear to be any difference between lighter skin types, but more treatments are often needed at lower doses than compared to psoriasis patients. The push to treat darker-skinned patients with longer treatments may cause a build-up of heat, which then leads to a flare of their AD.

## Vitiligo

Vitiligo is a form of dyschromia in which hypopigmented and depigmented macules and patches form on the skin. There are several forms of vitiligo, which range from single asymmetric stable patches (segmental) to symmetric widespread (generalized) forms. Although it is prevalent in all skin types, patients with skin of color suffer from this disease a greater degree because of the contrast between the depigmented areas and their normal skin tone. Although the disease has relatively few physical symptoms and is not fatal, the psychosocial impact of this disease can be very severe. Misconceptions about the possible infectious etiology of vitiligo and its confusion with leprosy can cause extreme social isolation and



**Figure 1** Vitiligo before (A) and after (B) phototherapy.

have a severe impact on day-to-day life, especially in areas of the world where ignorance of the disease is widespread. It affects approximately 1% of the population of the United States, with varying rates worldwide.<sup>33</sup>

The pathogenesis of vitiligo is not precisely known, although the current understanding is that autoimmunity plays a large role. Thus, the most often used topical and systemic therapies involve some form of immunomodulation or immunosuppression, such as topical steroids, topical calcineurin inhibitors and phototherapy. Phototherapy is typically indicated for vitiligo in patients with more than 5% body surface area involvement. **Figure 1** is an example of a patient with vitiligo who responded to NB-UVB.

Phototherapy options for vitiligo typically involve some form of ultraviolet radiation. PUVA has been a mainstay in the treatment of vitiligo for many decades.<sup>34</sup> NB-UVB was first used in the treatment of vitiligo in 1997<sup>35</sup> and has been shown in recent years to be an effective treatment.<sup>36-40</sup> NB-UVB has been shown to improve pigmentation more effectively than PUVA. Both treatments, however, are ineffective on hands and feet.<sup>34</sup> Yones et al<sup>41</sup> published similar findings in a randomized double-blind trial of 50 patients that showed a >50% improvement in repigmentation for 64% of the patients receiving NB-UVB. In comparison, only 36% of

the patients receiving PUVA showed >50% improvement. In addition, the repigmented areas in the patients receiving PUVA were a poor color match to unaffected skin.

As with any treatment, NB-UVB has its share of adverse side effects but for the most part has been shown to be a safe modality. The most acute of these is phototoxicity from the ultraviolet radiation. Transient hyperpigmentation has also been noted.<sup>42</sup> One possible consideration may be an increased chance for nonmelanoma skin cancer in Fitzpatrick skin types I and II in patients with vitiligo. This is likely independent of artificial UV radiation exposure. In 2009, a retrospective review of 477 vitiligo patients determined that there was a nonstatistically significant increased risk of non-melanoma skin cancer among vitiligo patients when compared with the U.S. average.<sup>43</sup> All patients were baseline type I or II skin, and none had received UV phototherapy for their vitiligo. However, there were no skin cancers reported in vitiligo patients with darker pigmented skin. This observation is unusual given the assumption that the lack of pigment should increase the risk of skin cancer as it does in albinism.<sup>44</sup>

Another phototherapy modality available for vitiligo is the excimer laser, a monochromatic 308-nm high-intensity light source. It has been shown in multiple studies to be an effective treatment for vitiligo, with a faster repigmentation rate, and less incident irradiation to unaffected areas<sup>45-47</sup> than NB-UVB. The excimer laser has been shown in studies to cause quicker and more thorough repigmentation than NB-UVB.<sup>48,49</sup> Neither study, however, used a validated scoring method, nor were body locations of the affected regions considered. As stated earlier, hands and feet tend not to respond while the face has a much better response.

Newer, more objective measures of repigmentation can facilitate clinical study validation. In 2004, Hamzavi et al<sup>40</sup> published a study on the effectiveness of NB-UVB in treating vitiligo by using a novel quantitative metric, the vitiligo area scoring index, or VASI. The VASI uses the surface of the palm to approximate 1% of the body's surface area, then determines the degree of depigmentation (or repigmentation after treatment) within each "hand unit" of vitiligo on the body. This allows the total pigmentation level of the affected areas to be determined in a quantitative and parametric manner and for the reporting of the degree of response for the average patient. This is much more intuitive than the nonparametric system, which only allows one to stipulate the degree of repigmentation in a subgroup of a population. For example, the VASI score stated the average degree of repigmentation to be 43% in areas receiving NB-UVB as compared with an average repigmentation rate of 3% at the control sites.<sup>40</sup> Meanwhile, the nonparametric system used by Yones et al<sup>41</sup> stated 64% of patients achieved >50% repigmentation, which is much more difficult to interpret for most patients and physicians.

## Hidradenitis Suppurativa

Follicular disorders, such as acne keloidalis nuchae and pseudofolliculitis barbae are common among patients of color because of the differences in their hair shape and struc-

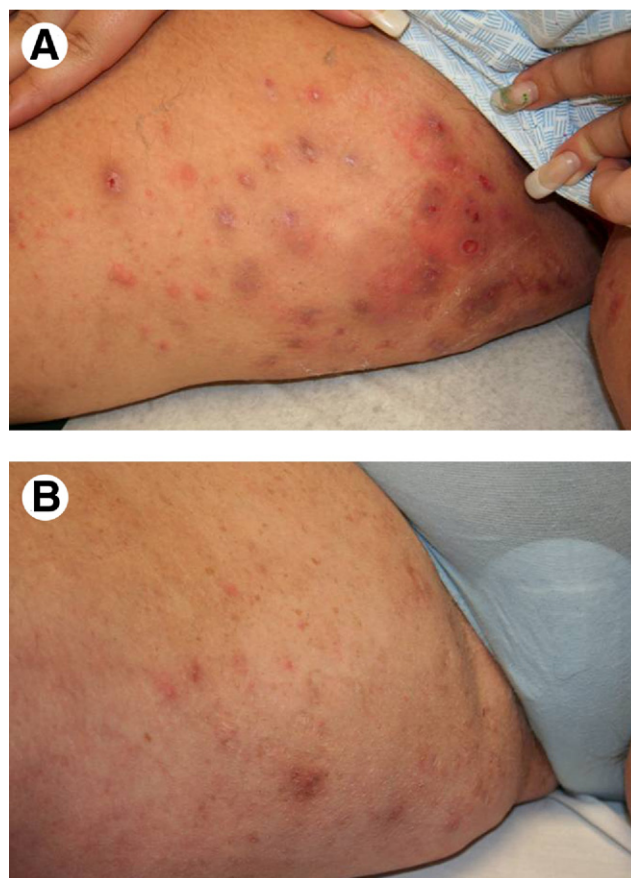
ture. Of these diseases, hidradenitis suppurativa (HS) is one of the most disfiguring and debilitating. It affects between 0.5% and 1% of the population, and has a female-to-male ratio of approximately 2:1. The condition is characterized by the presence of chronic inflammatory nodules and abscesses in the apocrine gland bearing areas of the skin: axillae, inframammary regions, groin, and gluteal cleft. These nodules may coalesce to form sinus tracts with multiple draining openings and eventually cause severe scarring and fibrosis in involved areas.<sup>51-55</sup> First-line treatment for HS involves good hygiene with benzoyl peroxide (ie, BPO) washes and topical antibiotics. Moderate-to-severe HS may be treated with systemic antibiotics, hormonal agents, biologics, and excisional surgery.

Most reported uses of phototherapy for HS are case reports, but some have led to better controlled studies. Nonablative radiofrequency devices have been shown to cause dermal and subcutaneous heating, which lead to some relief of the condition.<sup>56</sup> A 1450-nm diode laser can improve HS after 4 treatments but causes minimal changes to areas of scarring and sinus tracts.<sup>57</sup> Photodynamic therapy in conjunction with aminolevulinic acid has been noted to show clearance of 75%-100% of patients.<sup>58</sup> CO<sub>2</sub> laser stripping with healing through secondary intention has been shown to be an effective alternative to surgery in removing chronic lesions, with a low recurrence rate.<sup>59</sup>

One of the newer treatment modalities for HS is the long-pulsed Nd:YAG laser, which has been used in the past for hair removal. The justification for the use of this laser in this condition is based on a report that showed good results in the treatment of dissecting cellulitis.<sup>50</sup> In 2009, Tierney et al<sup>60</sup> published a randomized controlled trial for the use of the long-pulsed Nd:YAG laser in the treatment of moderate to severe HS (Hurley stages II to III). Patients were given topical antibiotics on one half of their body (control), and treated with 1064-nm long-pulsed Nd:YAG laser plus topical antibiotics on the treated side. The HS lesion, area and severity index<sup>51</sup> was used to quantitatively determine the extent that the lesions changed after treatment. After 3 months of treatment, the severity of HS decreased by 65.3%, averaged over all treated anatomic sites, as compared with a decrease of 7.5% for control sites.<sup>60</sup> Figure 2 is an example of a patient suffering from HS who responded to 3 treatments with a long pulsed YAG laser.

## Future of Phototherapy

The vast majority of phototherapy used in dermatology falls in the spectrum of UV light. It is by far the most studied and long-lived treatment modality within photomedicine. Research into the visible light spectrum, however, may hold promise for future treatment modalities. In a study published in 2010, Mahmoud et al<sup>61</sup> showed that visible light alone was able to produce pigmentation in patients with darker skin phototypes (IV to VI). The pigmentation lasted longer than similar pigmentation generated with the use of a UVA1 device and was accompanied by less erythema. Full-spectrum



**Figure 2** (A) Hidradenitis suppurativa at baseline, (B) Hidradenitis suppurativa after long pulsed YAG laser.

light has also been investigated as a therapeutic modality for use in atopic dermatitis. In a recently published study, patients irradiated with full-spectrum light showed a significant improvement in their atopic dermatitis, as well as a decrease in their mean eosinophil, IL-4 and IL-5 levels.<sup>62</sup>

Laser therapy similarly falls within a very narrow number of frequencies that have not changed in many years. Most laser therapy is designed to heat tissue, ablate cells, or cause damage at some level to have an effect. Recently there has been a surging interest in low-level laser therapy, which seeks to “bio-stimulate” cells, rather than cause damage. Yu et al studied the use of helium–neon laser irradiation (632.8 nm) at low-energy levels (1-3 J/cm<sup>2</sup>), and showed that it was able to stimulate the migration and proliferation of melanocytes in vitro, as well as repigment patients with segmental-type vitiligo when used twice a week.<sup>63</sup> Further studies showed that this laser may induce repigmentation through various mechanisms, including melanoblast differentiation,<sup>64</sup> improvement of microcirculation abnormalities,<sup>65</sup> and interactions with type IV collagen.<sup>66</sup> In more recent studies some authors have shown that low level lasers of this wavelength (or similar wavelengths) may be useful in enhancing the proliferation of cultured cells in general,<sup>67</sup> which may be of use in future cell transplant procedures, such as those used in the treatment of vitiligo.

## References

- Gelfand JM, Stern RS, Nijsten T, et al: The prevalence of psoriasis in African Americans: Results from a population-based study. *J Am Acad Dermatol* 52:23-26, 2005
- Menter A, Korman NJ, Elmets CA, et al: Guidelines of care for the management of psoriasis and psoriatic arthritis: section 5. Guidelines of care for the treatment of psoriasis with phototherapy and photochemotherapy. *J Am Acad Dermatol* 62:114-135, 2010
- Henseler T, Wolff K, Hönigsmann H, et al: Oral 8-methoxypsoralen photochemotherapy of psoriasis. The European PUVA study: A cooperative study among 18 European Centres. *Lancet* 1:853-857, 1981
- Melski JW, Tanenbaum L, Parrish JA, et al: Oral methoxsalen photochemotherapy for the treatment of psoriasis: A cooperative clinical trial. *J Invest Dermatol* 68:328-335, 1977
- Cooper EJ, Herd RM, Priestley GC, et al: A comparison of bathwater and oral delivery of 8-methoxypsoralen in PUVA therapy for plaque psoriasis. *Clin Exp Dermatol* 25:111-114, 2000
- Collins P, Rogers S: Bath-water compared with oral delivery of 8-methoxypsoralen PUVA therapy for chronic plaque psoriasis. *Br J Dermatol* 127:392-395, 1992
- Lowe NJ, Weingarten D, Bourget T, et al: PUVA therapy for psoriasis: Comparison of oral and bath-water delivery of 8-methoxypsoralen. *J Am Acad Dermatol* 14:754-760, 1986
- Turjanmaa K, Salo H, Reunala T: Comparison of trioxsalen bath and oral methoxsalen PUVA in psoriasis. *Acta Derm Venereol* 65:86-88, 1985
- Stern RS, Lunder EJ: Risk of squamous cell carcinoma and methoxsalen (psoralen) and UV-A radiation (PUVA). A meta-analysis. *Arch Dermatol* 134:1582-1585, 1998
- Malanos D, Stern RS: Psoralen plus ultraviolet A does not increase the risk of cataracts: A 25-year prospective study. *J Am Acad Dermatol* 57:231-237, 2007
- El-Mofty M, El Weshahy H, Youssef R, et al: A comparative study of different treatment frequencies of psoralen and ultraviolet A in psoriatic patients with darker skin types (randomized-controlled study). *Photodermatol Photoimmunol Photomed* 24:38-42, 2008
- Cameron H, Dawe RS, Yule S, et al: A randomized, observer-blinded trial of twice vs. three times weekly narrowband ultraviolet B phototherapy for chronic plaque psoriasis. *Br J Dermatol* 147:973-978, 2002
- Larkö O, Swanbeck G: Home solarium treatment of psoriasis. *Br J Dermatol* 101:13-16, 1979
- Adrian RM, Parrish JA, Momtaz-T K, et al: Outpatient phototherapy for psoriasis. *Arch Dermatol* 117:623-626, 1981
- Karvonen J, Kokkonen EL, Ruotsalainen E: 311 nm UVB lamps in the treatment of psoriasis with the Ingram regimen. *Acta Derm Venereol* 69:82-85, 1989
- Larkö O: Treatment of psoriasis with a new UVB-lamp. *Acta Derm Venereol* 69:357-359, 1989
- Coven TR, Burack LH, Gilleaudeau R, et al: Narrowband UV-B produces superior clinical and histopathological resolution of moderate-to-severe psoriasis in patients compared with broadband UV-B. *Arch Dermatol* 133:1514-1522, 1997
- Hearn RM, Kerr AC, Rahim KF, et al: Incidence of skin cancers in 3867 patients treated with narrow-band ultraviolet B phototherapy. *Br J Dermatol* 159:931-935, 2008
- Yones SS, Palmer RA, Garibaldinos TT, et al: Randomized double-blind trial of the treatment of chronic plaque psoriasis: Efficacy of psoralen-UV-A therapy vs narrowband UV-B therapy. *Arch Dermatol* 142:836-842, 2006
- Martin JA, Laube S, Edwards C, et al: Rate of acute adverse events for narrow-band UVB and Psoralen-UVA phototherapy. *Photodermatol Photoimmunol Photomed* 23:68-72, 2007
- Youssef RM, Mahgoub D, Mashaly HM, et al: Different narrowband UVB dosage regimens in dark skinned psoriatics: A preliminary study. *Photodermatol Photoimmunol Photomed* 24:256-259, 2008
- Shaw TE, Currie GP, Koudelka CW, et al: Eczema prevalence in the United States: Data from the 2003 National Survey of children's Health. *J Invest Dermatol* 131:67-73, 2011
- Tuchinda C, Kerr HA, Taylor CR, et al: UVA1 phototherapy for cutaneous diseases: An experience of 92 cases in the United States. *Photodermatol Photoimmunol Photomed* 22:247-253, 2006
- Krutmann J, Czech W, Diepgen T, et al: High-dose UVA1 therapy in the treatment of patients with atopic dermatitis. *J Am Acad Dermatol* 26:225-230, 1992
- Krutmann J, Diepgen TL, Luger TA, et al: High-dose UVA1 therapy for atopic dermatitis: Results of a multicenter trial. *J Am Acad Dermatol* 38:589-593, 1998
- von Kobyletzki G, Pieck C, Hoffmann K, et al: Medium-dose UVA1 cold-light phototherapy in the treatment of severe atopic dermatitis. *J Am Acad Dermatol* 41:931-937, 1999
- Tzaneva S, Seeber A, Schwaiger M, et al: High-dose versus medium-dose UVA1 phototherapy for patients with severe generalized atopic dermatitis. *J Am Acad Dermatol* 45:503-507, 2001
- Kowalick L, Kleinheinz A, Weichenthal M, et al: Low dose versus medium dose UV-A1 treatment in severe atopic eczema. *Acta Derm Venereol* 75:43-45, 1995
- Jekler J, Larkö O: Combined UVA-UVB versus UVB phototherapy for atopic dermatitis: A paired-comparison study. *J Am Acad Dermatol* 22:49-53, 1990
- Jekler J, Larkö O: Phototherapy for atopic dermatitis with ultraviolet A (UVA), low-dose UVB and combined UVA and UVB: Two paired-comparison studies. *Photodermatol Photoimmunol Photomed* 8:151-156, 1991
- Reynolds NJ, Franklin V, Gray JC, et al: Narrow-band ultraviolet B and broad-band ultraviolet A phototherapy in adult atopic eczema: A randomised controlled trial. *Lancet* 357:2012-2016, 2001
- Legat FJ, Hofer A, Brabek E, et al: Narrowband UV-B vs medium-dose UV-A1 phototherapy in chronic atopic dermatitis. *Arch Dermatol* 139:223-224, 2003
- Kovacs SO: Vitiligo. *J Am Acad Dermatol* 38:647-666, 1998; quiz: 667-648
- Bhatnagar A, Kanwar AJ, Parsad D, et al: Comparison of systemic PUVA and NB-UVB in the treatment of vitiligo: An open prospective study. *J Eur Acad Dermatol Venereol* 21:638-642, 2007
- Westerhof W, Nieuweboer-Krobotova L: Treatment of vitiligo with UV-B radiation vs topical psoralen plus UV-A. *Arch Dermatol* 133:1525-1528, 1997
- Njoo MD, Bos JD, Westerhof W: Treatment of generalized vitiligo in children with narrow-band (TL-01) UVB radiation therapy. *J Am Acad Dermatol* 42:245-253, 2000
- Scherschun L, Kim JJ, Lim HW: Narrow-band ultraviolet B is a useful and well-tolerated treatment for vitiligo. *J Am Acad Dermatol* 44:999-1003, 2001
- Kanwar AJ, Dogra S: Narrow-band UVB for the treatment of generalized vitiligo in children. *Clin Exp Dermatol* 30:332-336, 2005
- El Mofty M, Mostafa W, Esmat S, et al: Narrow band ultraviolet B 311 nm in the treatment of vitiligo: Two right-left comparison studies. *Photodermatol Photoimmunol Photomed* 22:6-11, 2006
- Hamzavi I, Jain H, McLean D, et al: Parametric modeling of narrow-band UV-B phototherapy for vitiligo using a novel quantitative tool: The vitiligo Area Scoring Index. *Arch Dermatol* 140:677-683, 2004
- Yones SS, Palmer RA, Garibaldinos TM, et al: Randomized double-blind trial of treatment of vitiligo: Efficacy of psoralen-UV-A therapy vs narrowband-UV-B therapy. *Arch Dermatol* 143:578-584, 2007
- Welsh O, Herz-Ruelas ME, Gómez M, et al: Therapeutic evaluation of UVB-targeted phototherapy in vitiligo that affects less than 10% of the body surface area. *Int J Dermatol* 48:529-534, 2009
- Hexsel CL, Eide MJ, Johnson CC, et al: Incidence of nonmelanoma skin cancer in a cohort of patients with vitiligo. *J Am Acad Dermatol* 60:929-933, 2009
- Lookingbill DP, Lookingbill GL, Leppard B: Actinic damage and skin cancer in albinos in northern Tanzania: Findings in 164 patients enrolled in an outreach skin care program. *J Am Acad Dermatol* 32:653-658, 1995
- Spencer JM, Nossa R, Ajmeri J: Treatment of vitiligo with the 308-nm excimer laser: A pilot study. *J Am Acad Dermatol* 46:727-731, 2002
- Taneja A, Trehan M, Taylor CR: 308-nm excimer laser for the treatment of localized vitiligo. *Int J Dermatol* 42:658-662, 2003

47. Leone G, Iacovelli P, Paro Vidolin A, et al: Monochromatic excimer light 308 nm in the treatment of vitiligo: A pilot study. *J Eur Acad Dermatol Venereol* 17:531-537, 2003
48. Casacci M, Thomas P, Pacifico A, et al: Comparison between 308-nm monochromatic excimer light and narrowband UVB phototherapy (311-313 nm) in the treatment of vitiligo—A multicentre controlled study. *J Eur Acad Dermatol Venereol* 21:956-963, 2007
49. Hong SB, Park HH, Lee MH: Short-term effects of 308-nm xenon-chloride excimer laser and narrow-band ultraviolet B in the treatment of vitiligo: A comparative study. *J Korean Med Sci* 20:273-278, 2005
50. Krasner BD, Hamzavi FH, Murakawa GJ, et al. Dissecting cellulitis treated with the long-pulsed Nd:YAG laser. *Dermatol Surg* 32:1039-1044, 2006
51. Sartorius K, Lapins J, Emtestam L, et al: Suggestions for uniform outcome variables when reporting treatment effects in hidradenitis suppurativa. *Br J Dermatol* 149:211-213, 2003
52. Revuz J: [Modifications to the Sartorius score and instructions for evaluating the severity of suppurative hidradenitis]. *Ann Dermatol Venereol* 134:173-174, 2007
53. Lam J, Krakowski AC, Friedlander SF: Hidradenitis suppurativa (acne inversa): Management of a recalcitrant disease. *Pediatr Dermatol* 24:465-473, 2007
54. Sellheyer K, Krahl D: "Hidradenitis suppurativa" is acne inversa! An appeal to (finally) abandon a misnomer. *Int J Dermatol* 44:535-540, 2005
55. Fitzsimmons JS, Guilbert PR, Fitzsimmons EM: Evidence of genetic factors in hidradenitis suppurativa. *Br J Dermatol* 113:1-8, 1985
56. Iwasaki J, Marra DE, Fincher EF, et al: Treatment of hidradenitis suppurativa with a nonablative radiofrequency device. *Dermatol Surg* 34:114-117, 2008
57. Downs A: Smoothbeam laser treatment may help improve hidradenitis suppurativa but not Hailey–Hailey disease. *J Cosmet Laser Ther* 6:163-164, 2004
58. Gold M, Bridges TM, Bradshaw VL, et al: ALA-PDT and blue light therapy for hidradenitis suppurativa. *J Drugs Dermatol* 3:S32-S35, 2004 (1 suppl)
59. Hazen PG, Hazen BP: Hidradenitis suppurativa: Successful treatment using carbon dioxide laser excision and marsupialization. *Dermatol Surg* 36:208-213, 2010
60. Tierney E, Mahmoud BH, Hessel C, et al: Randomized control trial for the treatment of hidradenitis suppurativa with a neodymium-doped yttrium aluminium garnet laser. *Dermatol Surg* 35:1188-1198, 2009
61. Mahmoud BH, Ruvolo E, Hessel CL, et al: Impact of long-wavelength UVA and visible light on melanocompetent skin. *J Invest Dermatol* 130:2092-2097, 2010
62. Byun HJ, Lee HI, Kim B, et al: Full-spectrum light phototherapy for atopic dermatitis. *Int J Dermatol* 50:94-101, 2011
63. Yu HS, Wu CS, Yu CL, et al: Helium–neon laser irradiation stimulates migration and proliferation in melanocytes and induces repigmentation in segmental-type vitiligo. *J Invest Dermatol* 120:56-64, 2003
64. Lan CC, Wu CS, Chiou MH, et al: Low-energy helium–neon laser induces locomotion of the immature melanoblasts and promotes melanogenesis of the more differentiated melanoblasts: Recapitulation of vitiligo repigmentation in vitro. *J Invest Dermatol* 126:2119-2126, 2006
65. Wu CS, Hu SC, Lan CC, et al: Low-energy helium–neon laser therapy induces repigmentation and improves the abnormalities of cutaneous microcirculation in segmental-type vitiligo lesions. *Kaohsiung J Med Sci* 24:180-189, 2008
66. Lan CC, Wu CS, Chen GS, et al: Helium–neon laser and topical tacrolimus combination therapy: Novel treatment option for vitiligo without additional photocarcinogenic risks. *J Eur Acad Dermatol Venereol* 23:344-345, 2009
67. Alghamdi KM, Kumar A, Moussa NA: Low-level laser therapy: A useful technique for enhancing the proliferation of various cultured cells. *Lasers Med Sci*, in press