

Periprosthetic Supracondylar Femur Fracture Treated With Spanning External Fixation

Motasem Refaat, MD, Sheldon Coleman, MD, John P. Meehan, MD, and Amir A. Jamali, MD

Abstract

Periprosthetic supracondylar fractures of the femur after total knee arthroplasty represent a devastating complication for the patient and a technical challenge for the surgeon. Treatment is often complicated by advanced patient age, retained cement, and accompanying osteoporosis.

We present the case of a 54-year-old woman with a comminuted fracture of the distal femur just above a total knee prosthesis. She had a complex past medical history, including extensive coronary artery disease, morbid obesity, chronic osteoporosis, anemia, diabetes, and rheumatoid arthritis. She was a Jehovah's Witness and thus refused all blood products. Given her medical history, religious preferences, and fracture comminution, a spanning external fixator was used. She completed fracture union with an excellent clinical and radiographic result at 2 years.

The incidence of periprosthetic supracondylar fractures of the femur after total knee arthroplasty (TKA) ranges from 0.6% to 2.5%.¹ Treatment of periprosthetic fractures is often complicated by advanced patient age and osteoporosis, which frequently accompanies these fractures. Management of a periprosthetic fracture depends on the relation between the fracture site and the prosthesis, displacement of the prosthesis, integrity of the fixation of the prosthesis, extent of the bone loss caused by fracture comminution or preexisting osteolysis, general health of the patient, and surgeon expertise.^{2,3} The aim is to achieve fracture union around a stable, well-aligned arthroplasty with preserved or restored bone stock and therefore to return the patient to previous level of function. Although nonoperative treatments have been shown to be successful,^{4,5} in the great majority of cases surgical treatment is advised for these fractures.⁶⁻¹⁰ In cases in which bone stock is adequate for fixation rather than replacement of the distal femur, 2 modalities are commonly used: retrograde intramedullary nailing and locking plates. Each has its drawbacks and advantages.^{11,12}

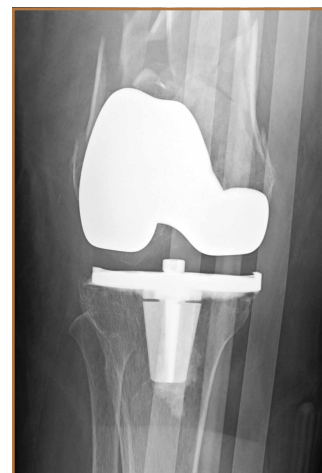Although external fixation has been used in the treatment of distal femoral fractures,¹³ it is seldom considered in the treatment of periprosthetic fractures. Several authors have described cases that used external fixators, occasionally spanning the knee. The specific types of external fixators discussed in the literature have included ring fixators,¹⁴⁻¹⁷ hybrid fixators,¹⁸ and uniplanar nonspanning fixators^{14,19} (Table). Use of a simple anterior spanning external fixator in treating a periprosthetic femoral fracture has received little attention in the literature.

The patient provided written informed consent for print and electronic publication of this case report.

Case Report

A 54-year-old woman with previous total hip arthroplasty (THA) and ipsilateral TKA tripped on a carpet and sustained a comminuted fracture of the distal femur just above the TKA prosthesis (Figure 1). She was a Jehovah's Witness and thus refused all blood products. She had an extensive history of osteoporosis, morbid obesity (5 feet tall, 250 pounds; body mass index, 49), diabetes, and rheumatoid arthritis. Evaluation by the internal medicine service revealed severe coronary artery disease on a stress thallium test and anemia with hematocrit of 24%. Given the patient's medical comorbidities and religious status, and the location of the comminuted distal femur fracture, several treatment options were considered. First was nonoperative treatment with a cast or cast-brace (hinged cast). Because of her body habitus, however, we thought she would very likely experience skin complications, inadequate immobilization of the bone, and significant discomfort.

Figure 1. Anteroposterior radiograph of knee in immobilizer brace immediately after periprosthetic fracture.



Authors' Disclosure Statement: The authors report no actual or potential conflict of interest in relation to this article.

Ultimately, use of a spanning external fixator was chosen as the safest course, given the significant medical risks accompanying a more extensive surgical reconstruction. With the spanning external fixator, the main risks were the inability to fully control fracture alignment and the potential introduction of infection into the functional THA. We thought that, by limiting the amount of time in the fixator and managing the pin site aggressively, we could minimize the risk for infection in this setting.

The procedure was performed with the patient under general anesthesia. During surgery, a lateral image of the femur was used to identify the distal end of the THA prosthesis. A level was marked 2 to 3 cm distal to the tip of this prosthesis, and another about 1 cm above the fracture (noted to be above the most proximal extent of the knee joint). These planned pin-entry sites were prepared from an anterior approach with incisions (using a No. 11 blade) of about 1 cm each. Blunt dissection was carried down to the femur. Each planned pin site was predrilled with a 3.5-mm drill; then, a 5-mm Shanz pin was

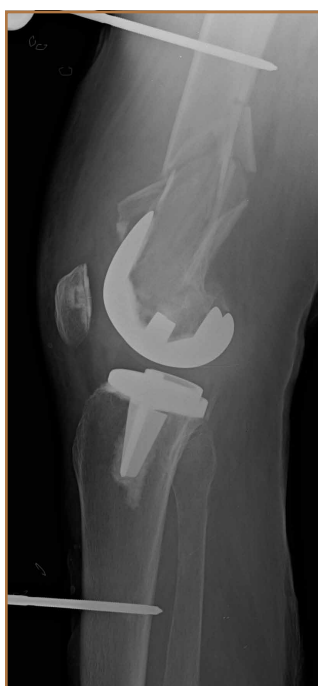

Figure 2. Lateral radiograph of knee immediately after application of spanning uniplanar external fixator.

placed. This process was repeated immediately distal to the tibial component and at the junction of the mid and distal thirds of the tibia (Figure 2). The preliminary external fixator frame was then applied. Once the reduction was satisfactory in the anteroposterior and lateral planes, the fixator clamps were tightened. A second row of bars was then incorporated.

Six weeks after surgery, radiographs showed early callus formation. Removing the external fixator and examining the knee under anesthesia confirmed there was no significant motion through the fracture site. A cast-brace (fiberglass thigh segment, fiberglass lower leg cast with hinged knee segment) was then applied. We remained concerned about skin complications but were encouraged by the early healing achieved with the fixator. The patient was started on a physical therapy program of gait training with a walker and toe-touch weight-bearing on the injured extremity. She also started a limited lower-extremity strengthening program. Three months after surgery, she was tolerating

Table. External Fixation in the Treatment of Periprosthetic Fractures of the Knee

Authors	Year	Case	Fixation	Spanning/ Nonspanning	Outcome Measure	
					Knee ROM	Radiographs
Merkel & Johnson ⁹	1986	1	Uniplanar	Nonspanning	45 mo—0° to 90°	—
		2	Uniplanar	Nonspanning	45 mo—10° to 95°	
		3	Uniplanar	Nonspanning	45 mo—10° to 100°	
Simon & Brinker ¹⁵	1999	1	Ilizarov/ring	Spanning	14 wk—0° to 85° 19 mo—0° to 110°	10 wk—callus formation
Pleva et al ¹⁴	2004	1	Ilizarov/ring	Spanning	—	—
		2	Uniplanar	Nonspanning		
		3	Uniplanar	Nonspanning		
Hurson et al ¹⁶	2005	1	Ilizarov/ring	Nonspanning	Postoperative day 2—full ROM 14 mo—0° to 120°	Postoperative—satisfactory reduction 8 wk—callus formation
Pafilas & Kourtzis ¹⁸	2006	1	Hybrid external fixation	Nonspanning	6 wk—prefracture ROM 2 y—0° to 100°	10 wk—sufficient callus 2 y—good alignment, no angular deformity
Beris et al ¹⁷	2010	1	Ilizarov/ring	Nonspanning	36 wk—0° to 85°	Postoperative—satisfactory reduction 12 wk—uncomplicated healing 36 wk—5° varus
		2	Ilizarov/ring	Nonspanning	42 mo—0° to 42°	Postoperative—no varus/valgus deformity 6 mo—excellent alignment
		3	Ilizarov/ring	Nonspanning	36 wk—0° to 100°	Postoperative—6° varus 6 wk—uncomplicated healing
Present case	2015	1	Uniplanar	Spanning	3 mo—0° to 120°	6 wk—callus formation

Abbreviation: ROM, range of motion.

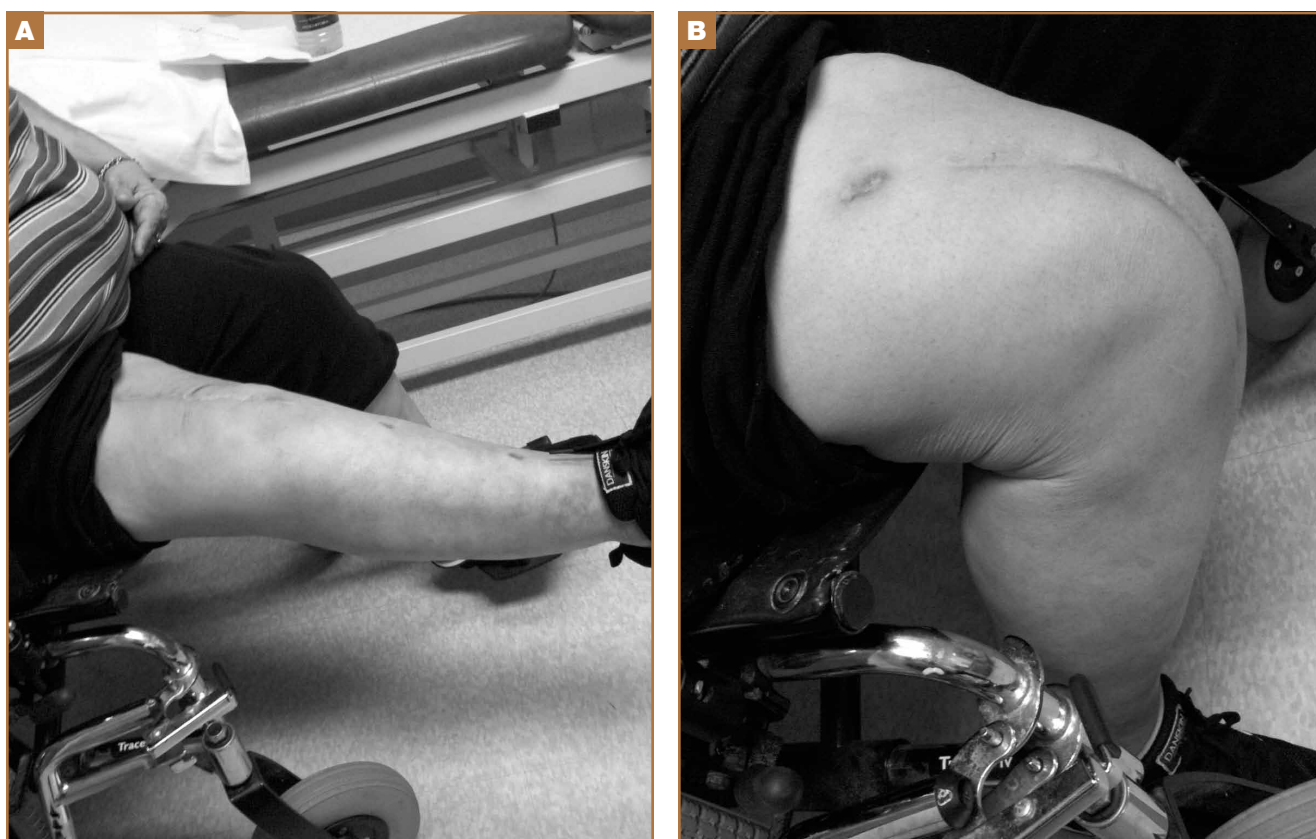


Figure 3. Clinical radiograph 6 months after surgery shows (A) 10° extensor lag and (B) 120° of active flexion of knee.

weight-bearing on the injured extremity with no pain. At 6 months, knee radiographs showed fracture consolidation with active range of motion of 10° to 120° and no pain (Figures 3A, 3B). Distal sensation, motor function, and vascular examination were normal. Two years after surgery, radiographs of the right knee showed minor malalignment in the coronal and sagittal planes (Figures 4A, 4B) and complete consolidation of the fracture.

Discussion

Periprosthetic fractures of the femur after TKA often occur in the setting of osteopenia, and some are associated with concurrent implant loosening. In most cases, these fractures require surgical stabilization. Nevertheless, the goals of treatment are to obtain and maintain anatomical alignment and stability to allow early range of motion. Nonoperative options include skeletal traction, cast, pins and plaster, and cast-brace.^{3-5,20} Operative options include intramedullary fixation,^{12,21} stabilization with various plates,²¹⁻²³ revision knee arthroplasty, and arthrodesis.¹ Treatment selection should be based on patient health, fracture displacement, comminution, osteopenia severity, and status of the prosthetic components.

The present case exemplifies some of the highest degrees of medical and surgical risk factors in people with a periprosthetic femoral fracture after TKA. Patients with rheumatoid arthritis, patients having corticosteroid treatment, patients of advanced

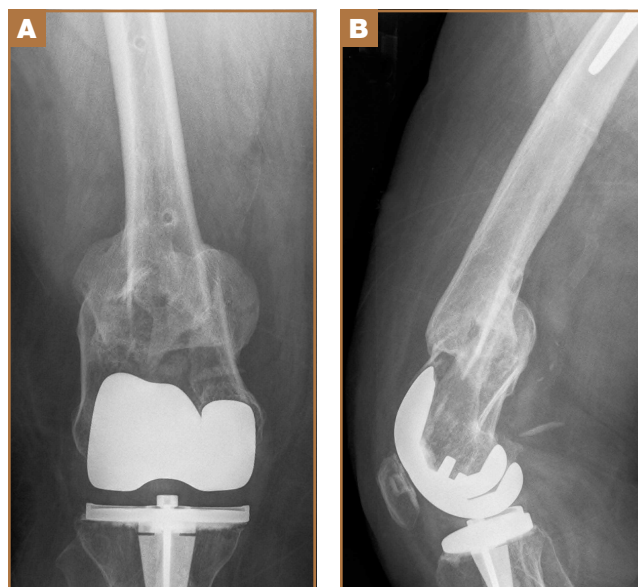


Figure 4. (A) Anteroposterior and (B) lateral radiographs of knee at 2-year follow-up, after spanning external fixation of knee.

age, and female patients are all at higher risk for supracondylar femoral fracture.⁹ Our patient had these risk factors on a background of anemia and extensive coronary artery disease.

Given her past medical history and refusal of blood products out of religious belief, we thought she was too high risk for extensive surgical treatment for her fracture. In addition, she was not an ideal candidate for nonoperative treatment, as a periprosthetic fracture typically is treated with surgical revision or open reduction and internal fixation. Therefore, we selected an unconventional treatment modality, typically used as a temporizing measure in severe fractures around the knee—a spanning external fixator worn for 6 weeks and a cast-brace for an additional 6 weeks. This led to successful clinical and radiographic outcomes. We consider spanning external fixation a viable option for periprosthetic fractures after TKA in morbidly obese patients with relatively well-aligned fractures and extremely high risk for medical complications associated with traditional open surgery.

Dr. Refaat is Resident Physician, Dr. Coleman is Research Associate, and Dr. Meehan is Attending Physician, Department of Orthopaedic Surgery, University of California Davis, Sacramento, California. Dr. Jamali is Medical Director, Joint Preservation Institute, Sacramento, California.

Address correspondence to: Motasem Refaat, MD, Department of Orthopaedic Surgery, University of California Davis, 4860 Y St, #3800, Sacramento, CA 95817 (tel, 916-734-2182; fax, 916-734-7904; e-mail, moerefaat@gmail.com).

Am J Orthop. 2015;44(2):90-93. Copyright Frontline Medical Communications Inc. 2015. All rights reserved.

References

1. Figgie MP, Goldberg VM, Figgie HE 3rd, Sobel M. The results of treatment of supracondylar fracture above total knee arthroplasty. *J Arthroplasty.* 1990;5(3):267-276.
2. Su ET, Kubiak EN, Dewal H, Hiebert R, Di Cesare PE. A proposed classification of supracondylar femur fractures above total knee arthroplasties. *J Arthroplasty.* 2006;21(3):405-408.
3. Kim KI, Egol KA, Hozack WJ, Parvizi J. Periprosthetic fractures after total knee arthroplasties. *Clin Orthop.* 2006;(446):167-175.
4. Sochart DH, Hardinge K. Nonsurgical management of supracondylar fracture above total knee arthroplasty. Still the nineties option. *J Arthroplasty.* 1997;12(7):830-834.
5. Delport PH, Van Audekercke R, Martens M, Mulier JC. Conservative treatment of ipsilateral supracondylar femoral fracture after total knee arthroplasty. *J Trauma.* 1984;24(9):846-849.
6. Frigg R, Appenzeller A, Christensen R, Frenk A, Gilbert S, Schavan R. The development of the distal femur less invasive stabilization system (LISS). *Injury.* 2001;32(suppl 3):SC24-SC31.
7. Goesling T, Frenk A, Appenzeller A, Garapati R, Marti A, Krettek C. LISS PLT: design, mechanical and biomechanical characteristics. *Injury.* 2003;34(suppl 1):A11-A15.
8. Huang HT, Huang PJ, Su JY, Lin SY. Indirect reduction and bridge plating of supracondylar fractures of the femur. *Injury.* 2003;34(2):135-140.
9. Dennis DA. Periprosthetic fractures following total knee arthroplasty. *Instr Course Lect.* 2001;50:379-389.
10. Jamali AA, Lee MA, Donthineni R, Meehan JP. Minimally invasive management of a floating prosthesis injury with locking plates. *J Arthroplasty.* 2007;22(6):928-933.
11. Bong MR, Egol KA, Koval KJ, et al. Comparison of the LISS and a retrograde-inserted supracondylar intramedullary nail for fixation of a periprosthetic distal femur fracture proximal to a total knee arthroplasty. *J Arthroplasty.* 2002;17(7):876-881.
12. Firoozbakhsh K, Behzadi K, DeCoster TA, Moneim MS, Naraghi FF. Mechanics of retrograde nail versus plate fixation for supracondylar femur fractures. *J Orthop Trauma.* 1995;9(2):152-157.
13. Arazi M, Memik R, Ogun TC, Yel M. Ilizarov external fixation for severely comminuted supracondylar and intercondylar fractures of the distal femur. *J Bone Joint Surg Br.* 2001;83(5):663-667.
14. Pleva L, Sir M, Madeja R. Our experiences with the treatment of periprosthetic fractures of femur. *Biomed Pap Med Fac Univ Palacky Olomouc Czech Repub.* 2004;148(1):75-79.
15. Simon RG, Brinker MR. Use of Ilizarov external fixation for a periprosthetic supracondylar femur fracture. *J Arthroplasty.* 1999;14(1):118-121.
16. Hurson C, Synnott K, McCormack D. Above-knee Ilizarov external fixation for early periprosthetic supracondylar femoral fracture—a case report. *Knee.* 2005;12(2):145-147.
17. Beris AE, Lykissas MG, Sioros V, Mavrodontidis AN, Korompilias AV. Femoral periprosthetic fracture in osteoporotic bone after a total knee replacement: treatment with Ilizarov external fixation. *J Arthroplasty.* 2010;25(7):1168.e9-e12.
18. Pafilas D, Kourtzis N. Hybrid external fixation as a new treatment method for periprosthetic femoral fracture. A case report. *J Bone Joint Surg Am.* 2006;88(1):188-192.
19. Merkel KD, Johnson EW Jr. Supracondylar fracture of the femur after total knee arthroplasty. *J Bone Joint Surg Am.* 1986;68(1):29-43.
20. Cordeiro EN, Costa RC, Carazzato JG, Silva Jdos S. Periprosthetic fractures in patients with total knee arthroplasties. *Clin Orthop.* 1990;(252):182-189.
21. Riemer BL, Butterfield SL, Burke CJ 3rd, Mathews D. Immediate plate fixation of highly comminuted femoral diaphyseal fractures in blunt polytrauma patients. *Orthopedics.* 1992;15(8):907-916.
22. Kregor PJ, Hughes JL, Cole PA. Fixation of distal femoral fractures above total knee arthroplasty utilizing the less invasive stabilization system (L.I.S.S.). *Injury.* 2001;32(suppl 3):SC64-SC75.
23. Althausen PL, Lee MA, Finkemeier CG, Meehan JP, Rodrigo JJ. Operative stabilization of supracondylar femur fractures above total knee arthroplasty: a comparison of four treatment methods. *J Arthroplasty.* 2003;18(7):834-839.

This paper will be judged for the Resident Writer's Award.