

# Retrograde Reamer/Irrigator/Aspirator Technique for Autologous Bone Graft Harvesting With the Patient in the Prone Position

John Mansour, DO, and Janet D. Conway, MD

## Abstract

In recent years, the Reamer/Irrigator/Aspirator (RIA) system (Synthes, West Chester, Pennsylvania) has emerged as an extremely effective alternative in harvesting large volumes of autologous bone graft through reaming of the femoral intramedullary canal. The technique has been described in the literature as using an antegrade approach to the femur with the patient in the supine or prone position. It has also been described as a retrograde approach in the supine position.

In this article, we describe a new technique—a retrograde femoral approach with the patient in the prone position. This technique allows for more efficient preparation by eliminating the need to reposition, reprepare, and redrape the extremity, thus decreasing operative time and risk of infection. Although we present this technique for use in ankle and hindfoot arthrodesis, we think it can be valuable in any prone-position procedure, including spine surgery.

our knowledge, however, the RIA technique for the femur with the retrograde approach and the prone position has not been described. Antegrade harvesting uses the trochanteric entry point, and retrograde harvesting uses an entry at the intercondylar notch just anterior to the posterior cruciate ligament. In this article, we detail the technique for RIA harvesting of the femur with the patient in the prone position. Patient positioning is based on the diagnosis and the proposed procedure.

Advantages of a retrograde starting point include a more concentric trajectory (vs that of an antegrade starting point) and more efficient canal pressure reduction, which might decrease the risk of intraoperative fat embolization.<sup>10</sup> This technique offers a more efficient solution to any procedure that requires the prone position, and it avoids the need to reposition, reprepare, or redrape the extremity. It is also very useful in treating obese patients.

After obtaining institutional review board (IRB) approval, we retrospectively reviewed patient files. Because the study was retrospective, the IRB waived the requirement for informed consent. The patients described here provided written informed consent for print and electronic publication of these case reports.

## Surgical Technique

The patient is placed in a prone position on a radiolucent table with a bump under the thigh to allow access to the knee joint with full extension of the hip (Figures 1, 2A, 2B). The knee is then flexed to gain access to the intercondylar notch.

The anatomical axis of the femur is identified in the coronal and sagittal planes with the help of an image intensifier. Frequent intraoperative fluoroscopic imaging is required to prevent eccentric reaming and guide-wire movement from causing iatrogenic fractures and perforations, respectively.<sup>8</sup> A 2-mm Steinmann pin is used to identify the point of entry into the femoral canal, which is located just above the posterior cruciate ligament insertion in the intercondylar notch, and care is taken not to ream this structure. A minimally invasive incision of about 15 mm is centered on this pin using a patellar tendon-splitting approach.

The Reamer/Irrigator/Aspirator (RIA) system (Synthes, West Chester, Pennsylvania) has become a powerful tool for harvesting autologous bone graft from the intramedullary canal of the long bones of the lower extremity for the treatment of osseous defects, nonunions, and joint fusions.<sup>1,2</sup> The RIA system provides satisfactory quality and quantity of bone graft (range, 40-90 mL)<sup>3-5</sup> with osteogenic properties that rival those harvested from the iliac crest.<sup>6,7</sup> Minimal donor-site morbidity and mortality have been reported in association with the RIA technique compared with iliac crest bone graft harvest.<sup>8</sup>

The RIA technique for the femur—with the antegrade approach and the supine position,<sup>8</sup> with the antegrade approach and the prone position,<sup>9</sup> and with the retrograde approach and the supine position<sup>4</sup>—has been described in the literature. To

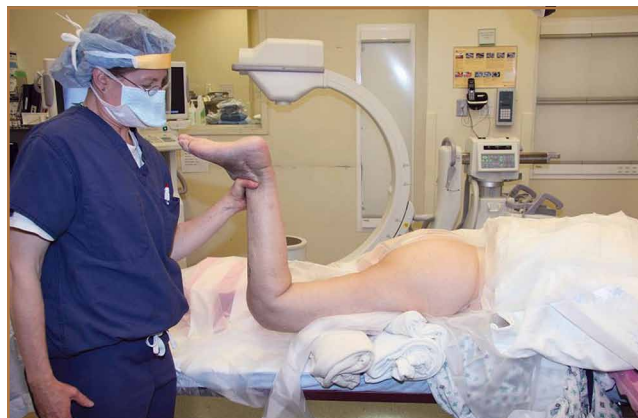**Authors' Disclosure Statement:** Dr. Conway reports that she is a consultant for Biomet and DePuy Synthes (for the RIA system) and received a grant from Medtronic for another research project. Dr. Mansour reports no actual or potential conflict of interest in relation to this article.

An 8-mm cannulated anterior cruciate ligament reamer is passed over the pin to enlarge the opening at the entry point, and a 2.5-mm ball-tipped guide wire is positioned in the femur. The image intensifier is used to confirm positioning of the guide in the trochanteric region and centered in the intramedullary canal. A radiolucent diving board facilitates fluoroscopic imaging.

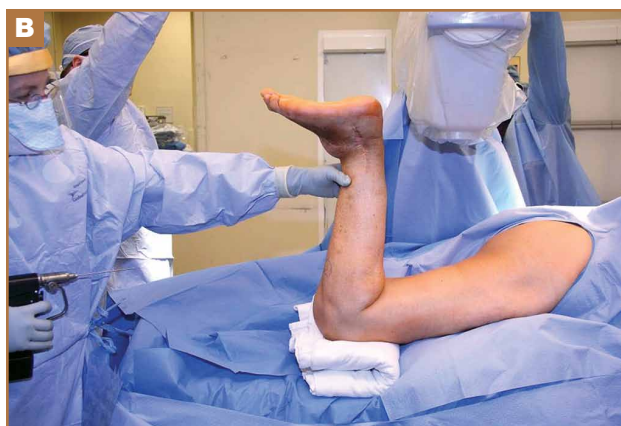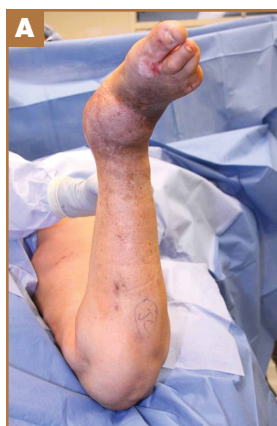The diameter (12.5 or 16.5 mm) of the reaming head is selected after the intramedullary guide is placed in the femoral canal. The isthmus of the femur is then identified radiographically, and a radiopaque ruler with increments in millimeters is used to measure the canal diameter (Figures 3A, 3B). Because the femoral canal is an ellipsoid, the canal diameter usually is much larger anteroposteriorly than laterally.<sup>8</sup> We prefer to use a reaming head that overlaps the inner cortical diameter by 1 mm on each side. An alternative method includes measuring the outer diameter of the narrowest portion of the bone and using a reamer head no more than 45% of the outer diameter at the isthmus.<sup>8</sup>

The RIA system is prepared on the back table by attaching the reaming head to the irrigation and suction systems. As the reamer head enters the intramedullary canal, an approach-withdraw-pause technique is used to slowly advance the reamer through the femur. It is crucial to use the image intensifier to guide reaming in order to avoid overdrilling the anterior cortex and prevent eccentric reaming of the canal, which more commonly occurs in patients with large anterior femoral bows.<sup>11</sup> When the collection filter becomes full, reaming is stopped. The bone graft in the filter is emptied into a specimen cup for measurement and storage until subsequent use (Figure 4). Suctioning is suspended when reaming is stopped because substantial blood loss can occur with prolonged suction and aspiration.<sup>12</sup> When repeat reaming is required, care is taken not to overream the cortices, thereby avoiding the risk of iatrogenic fracture.<sup>10,12</sup>

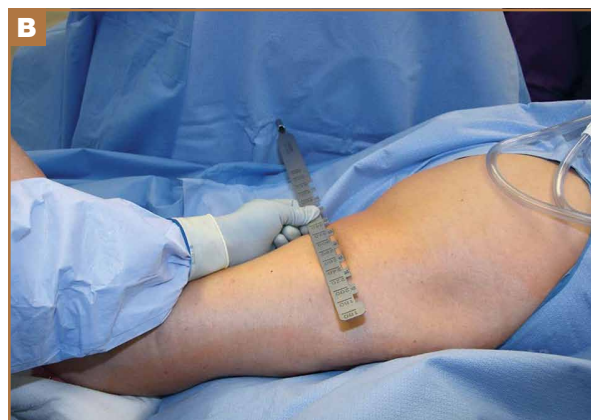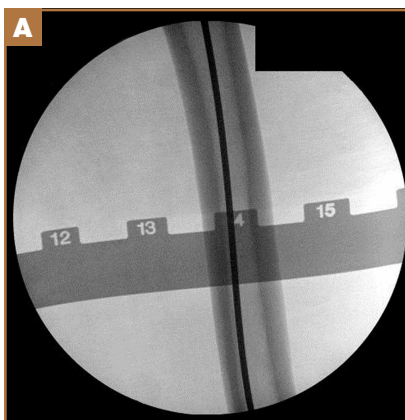
The knee joint is irrigated to remove any



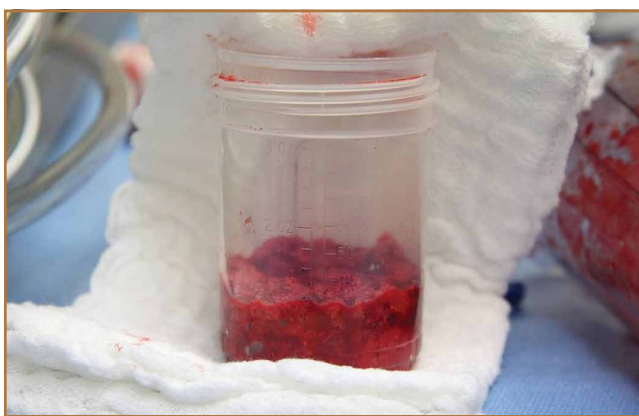**Figure 1.** Clinical photograph shows prone positioning of patient on radiolucent table. Copyright 2014, Rubin Institute for Advanced Orthopedics, Sinai Hospital of Baltimore.



**Figure 2.** Clinical photographs: (A) anteroposterior view, (B) lateral view. Ipsilateral extremity is prepared and draped with complete access to entire femur. Note large anteromedial free flap, which requires trans-Achilles posterior approach to avoid tenuous blood supply. Copyright 2014, Rubin Institute for Advanced Orthopedics, Sinai Hospital of Baltimore.



**Figure 3.** (A) Fluoroscopic C-arm image of radiolucent ruler over femoral isthmus. (B) Clinical photograph shows placement of radiolucent ruler over posterior thigh. Copyright 2014, Rubin Institute for Advanced Orthopedics, Sinai Hospital of Baltimore.



**Figure 4.** Specimen cup of bone graft (~30 mL) harvested from intramedullary canal after removal of supernatant fluid. Copyright 2014, Rubin Institute for Advanced Orthopedics, Sinai Hospital of Baltimore.

intramedullary debris. Typically there is no debris, as it is captured by the RIA. The wound is closed in 2 layers. Dressing with Ace bandage (3M, St. Paul, Minnesota) is placed around the knee for comfort. Weight-bearing status is determined by the index procedure.

## Case Reports

### Case 1

A 68-year-old female smoker presented to our facility with right ankle pain after recent ankle arthrodesis for pilon fracture nonunion. Almost 3 years earlier, the patient sustained a Gustilo-Anderson type II open pilon fracture in a motorcycle accident. She underwent antibiotic therapy, irrigation and débridement of the fracture site, and external fixation before definitive treatment with repeat irrigation and débridement and open reduction and internal fixation of the tibial plafond. About 6 months after surgery, she presented to her surgeon with a draining abscess over the anteromedial surgical incision. Multiple débridement procedures were performed, the implant was removed, the ankle was stabilized with a bridging external fixator, and culture-specific antibiotic therapy was administered. Intraoperative cultures confirmed methicillin-resistant *Staphylococcus aureus*. Vancomycin was administered intravenously for 6 weeks. Once C-reactive protein level and erythrocyte sedimentation rate returned to normal, repeat débridement with a rectus abdominis free flap and ankle fusion were performed.

When the patient presented to our clinic, we saw atrophic nonunion of the ankle fusion on radiographs. Smoking cessation was encouraged but not required before surgery. The patient returned to the operating suite for tibiotalar calcaneal fusion with a retrograde intramedullary nail. With the patient in the prone position, retrograde femoral RIA reaming was performed to harvest 30 mL of autologous bone. After resection of the nonunion site using a trans-Achilles approach and insertion of the intramedullary nail, the autologous bone graft was mixed with recombinant human bone morphogenetic protein 2 (BMP-2), and the mixture was introduced into

the fusion site. At final follow-up, 18 months after surgery, the patient was clinically asymptomatic and radiographically healed—without further intervention and despite continued smoking. She did not report any knee pain from the harvest site.

### Case 2

A 59-year-old noncompliant woman with diabetes and Charcot neuropathy sustained a trimalleolar ankle fracture-dislocation that was initially treated with ankle and hindfoot arthrodesis. The postoperative course was uneventful, and she was discharged home. Less than a week later, she presented to the emergency department with a midshaft tibial fracture just proximal to the ankle and hindfoot fusion nail. She subsequently had the device removed and a long arthrodesis rod inserted to span the fracture site up to the proximal tibial metadiaphysis. About 9 months later, she returned to our office complaining of ankle pain. No signs of infection were clinically evident. Radiographs showed nonunion of the ankle and subtalar joint. Findings of the initial bone biopsy and pathologic examination were negative for infection. The patient returned to the operating room 4 weeks later for revision ankle fusion. With the patient in the prone position, autologous bone (~30 mL) was harvested using retrograde femoral RIA reaming. The nonunion site was resected, and a mixture of autologous bone graft and BMP-2 was applied. Through a posterior approach, an anterior ankle arthrodesis locking plate was applied to the posterior aspect of the calcaneus and tibia. The patient was kept non-weight-bearing for 3 months and progressed in weight-bearing for another 4 to 6 weeks. Ambulatory status was restored about 4 months after surgery. No harvest-site knee pain was reported.

## Discussion

Given its osteogenic, osteoconductive, and osteoinductive properties, autologous cancellous bone graft is the gold standard for reconstruction and fusion procedures in foot and ankle surgery.<sup>13</sup> Bone graft can be obtained from many potential donor sites, but the most common is the iliac crest.<sup>2</sup> However, many comorbidities, such as residual donor-site pain, neurovascular injuries, infection, and increased surgical time, have been reported in the literature.<sup>14,15</sup> The RIA system was initially developed for simultaneous reaming and aspiration to reduce intramedullary pressure, heat generation, operating time, and the systemic effects of reaming, such as the embolic phenomenon.<sup>16-22</sup> The single-pass reamer has provided a minimally invasive strategy for procuring voluminous amounts of autologous cancellous bone from the intramedullary canal of lower extremity long bones. Schmidmaier and colleagues<sup>3</sup> recently quantified the measurements of several growth factors, such as insulinlike growth factor 1, transforming growth factor  $\beta$  1, and BMP-2—proving that RIA-derived aspirates have amounts comparable to if not larger than those of iliac crest autologous bone graft. Pratt and colleagues<sup>23</sup> provided insight into the possibility of induction of mesenchymal stem cells using the previously unwanted supernatant reamings after filtration. Recently, the RIA technique of autologous tibial and

hindfoot bone graft harvest was described for use in ankle or tibiototalcaneal arthrodesis.<sup>2</sup> Although this technique is a useful surgical option, tibia size remains a limiting factor. Kovar and Wozasek<sup>24</sup> reported harvesting significantly more bone graft in the femur than in the tibia. A tibia that cannot accommodate the 12-mm (smallest) reamer head in the RIA system would be a contraindication. In addition, concerns about the association between tibial stress fractures and reaming of the entire tibial canal and concerns about the overall donor-site morbidity of the tibial shaft remain.

## Conclusion

With its retrograde approach and prone positioning, this RIA technique is an effective and efficient solution for harvesting autologous femoral bone graft. Although we have described its use in ankle and hindfoot arthrodesis, this technique can be applied to any prone-position surgical procedure, including spine surgery.

Dr. Mansour is Orthopedic Trauma Surgeon, Pikeville Medical Center, a Mayo Clinic Care Network Member, Pikeville, Kentucky. Dr. Mansour was a resident at Philadelphia College of Osteopathic Medicine at the time the article was written. Dr. Conway is Head of Bone and Joint Infection, International Center for Limb Lengthening, Rubin Institute for Advanced Orthopedics, Sinai Hospital of Baltimore, Baltimore, Maryland.

Acknowledgments: The authors thank Amanda Chase, MA, and Doris Kelly, MA, for their invaluable assistance with the manuscript.

Address correspondence to: Janet D. Conway, MD, International Center for Limb Lengthening, Rubin Institute for Advanced Orthopedics, Sinai Hospital of Baltimore, 2401 W Belvedere Ave, Baltimore, MD 21215 (tel, 410-601-8500; fax, 410-601-4292; e-mail, jconway@lifebridgehealth.org).

*Am J Orthop.* 2015;44(5):202-205. Copyright Frontline Medical Communications Inc. 2015. All rights reserved.

## References

- Kobbe P, Tarkin IS, Frink M, Pape HC. Voluminous bone graft harvesting of the femoral marrow cavity for autologous transplantation. An indication for the "reamer-irrigator-aspirator-" (RIA-)technique [in German]. *Unfallchirurg.* 2008;111(6):469-472.
- Herscovici D Jr, Scaduto JM. Use of the reamer-irrigator-aspirator technique to obtain autograft for ankle and hindfoot arthrodesis. *J Bone Joint Surg Br.* 2012;94(1):75-79.
- Schmidmaier G, Herrmann S, Green J, et al. Quantitative assessment of growth factors in reaming aspirate, iliac crest, and platelet preparation. *Bone.* 2006;39(5):1156-1163.
- Quick LM, Ritter CA, Mutty CE, Rohrbacher BJ, Buyea CM, Anders MJ. Donor site morbidity with reamer-irrigator-aspirator (RIA) use for autogenous bone graft harvesting in a single centre 204 case series. *Injury.* 2013;44(10):1263-1269.
- Lehman AA, Irgit KS, Cush GJ. Harvest of autogenous bone graft using reamer-irrigator-aspirator in tibiototalcaneal arthrodesis: surgical technique and case series. *Foot Ankle Int.* 2012;33(12):1133-1138.
- Wildemann B, Kadow-Romacker A, Haas NP, Schmidmaier G. Quantification of various growth factors in different demineralized bone matrix preparations. *J Biomed Mater Res A.* 2007;81(2):437-442.
- Sagi HC, Young ML, Gerstenfeld L, Einhorn TA, Tornetta P. Qualitative and quantitative differences between bone graft obtained from the medullary canal (with a reamer/irrigator/aspirator) and the iliac crest of the same patient. *J Bone Joint Surg Am.* 2012;94(23):2128-2135.
- Belthur MV, Conway JD, Jindal G, Ranade A, Herzenberg JE. Bone graft harvest using a new intramedullary system. *Clin Orthop.* 2008;466(12):2973-2980.
- Nichols TA, Sagi HC, Weber TG, Guiot BH. An alternative source of autograft bone for spinal fusion: the femur: technical case report. *Neurosurgery.* 2008;62(3 suppl 1):E179.
- Van Gorp CC, Falk JV, Kmiec SJ Jr, Siston RA. The reamer/irrigator/aspirator reduces femoral canal pressure in simulated TKA. *Clin Orthop.* 2009;467(3):805-809.
- Quintero AJ, Tarkin IS, Pape HC. Technical tricks when using the reamer irrigator aspirator technique for autologous bone graft harvesting. *J Orthop Trauma.* 2010;24(1):42-45.
- Stafford PR, Norris B. Reamer-irrigator-aspirator as a bone graft harvester. *Tech Foot Ankle Surg.* 2007;6(2):100-107.
- Whitehouse MR, Lankester BJ, Winson IG, Hepple S. Bone graft harvest from the proximal tibia in foot and ankle arthrodesis surgery. *Foot Ankle Int.* 2006;27(11):913-916.
- Scharfenberger A, Weber T. RIA for bone graft harvest: applications for grafting large segmental defects in the tibia and femur. Presented at: 21st Annual Meeting of the Orthopaedic Trauma Association; 2005; Ottawa, Canada.
- Arrington ED, Smith WJ, Chambers HG, Bucknell AL, Davino NA. Complications of iliac crest bone graft harvesting. *Clin Orthop.* 1996;(329):300-309.
- Bedi A, Karunakar MA. Physiologic effects of intramedullary reaming. *Instr Course Lect.* 2006;55:359-366.
- Higgins TF, Casey V, Bachus K. Cortical heat generation using an irrigating/aspirating single-pass reaming vs conventional stepwise reaming. *J Orthop Trauma.* 2007;21(3):192-197.
- Husebye EE, Lyberg T, Madsen JE, Eriksen M, Røise O. The influence of a one-step reamer-irrigator-aspirator technique on the intramedullary pressure in the pig femur. *Injury.* 2006;37(10):935-940.
- Müller CA, Green J, Südkamp NP. Physical and technical aspects of intramedullary reaming. *Injury.* 2006;37(suppl 4):S39-S49.
- Pape HC, Dwenger A, Grotz M, et al. Does the reamer type influence the degree of lung dysfunction after femoral nailing following severe trauma? An animal study. *J Orthop Trauma.* 1994;8(4):300-309.
- Pape HC, Zelle BA, Hildebrand F, Giannoudis PV, Krettek C, van Griensven M. Reamed femoral nailing in sheep: does irrigation and aspiration of intramedullary contents alter the systemic response? *J Bone Joint Surg Am.* 2005;87(11):2515-2522.
- Schult M, Küchle R, Hofmann A, et al. Pathophysiological advantages of rinsing-suction-reaming (RSR) in a pig model for intramedullary nailing. *J Orthop Res.* 2006;24(6):1186-1192.
- Pratt DJ, Papagiannopoulos G, Rees PH, Quinell R. The effects of medullary reaming on the torsional strength of the femur. *Injury.* 1987;18(3):177-179.
- Kovar FM, Wozasek GE. Bone graft harvesting using the RIA (reamer irrigation aspirator) system—a quantitative assessment. *Wien Klin Wochenschr.* 2011;123(9-10):285-290.

*This paper will be judged for the Resident Writer's Award.*