

Total Hip Arthroplasty for Posttraumatic Osteoarthritis of the Hip Fares Worse Than THA for Primary Osteoarthritis

Sonya Khurana, MD, Tamar B. Nobel, MD, Justin S. Merkow, MD, Michael Walsh, PhD, MPH, and Kenneth A. Egol, MD

Abstract

We conducted a study to evaluate differences between patients who had total hip arthroplasty (THA) for posttraumatic osteoarthritis (OA) and patients who had THA for primary OA.

Using a prospective database, we followed 3844 patients who had THA for OA. Those who had THA for secondary causes of hip OA, developmental hip dysplasia, or inflammatory processes were excluded. Of the remaining 1199 patients, 62 (63 fractures) had THA for posttraumatic OA after previous acetabular or proximal femur fracture fixation, and 1137 had THA for primary OA and served as the control group.

In the posttraumatic OA group, mean time between fracture repair and conversion to THA was 74 months. Compared with the control patients, the posttrauma patients lost more blood, were transfused more units of blood, had longer operating room times, and had more complications (all P s < .001). Posttrauma patients had a mean follow-up of 4.44 years and a mean postoperative modified Harris Hip Score of 81.3 at latest follow-up. Of these patients, 12.5% required revision a mean of 3.5 years after initial arthroplasty.

THA in patients with posttraumatic hip OA after an acetabular or proximal femur fracture is a longer and more complicated procedure with a higher rate of early failure.

The incidence of hip fractures decreased between 1995 and 2005, but these injuries continue to occur in large numbers. Between 1986 and 2005, the mean annual number of hip fractures was 957.3/100,000, and the majority of these occurred in patients 75 to 84 years old.¹ Investigators have described total hip arthroplasty (THA) performed after initial surgical treatment in patients who developed osteoarthritis (OA) of the hip secondary to a fracture.²⁻⁷ Only 1 of these studies compared these patients with a control group of patients who had THA for primary hip OA.² No study included

both previous proximal femur and acetabular fractures.

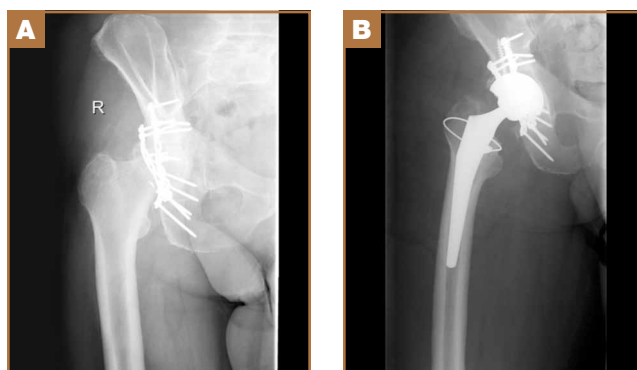
Postfracture OA may occur when there is residual articular incongruity after fracture or osteonecrosis of the femoral head. THA is commonly used to treat OA when more conservative treatments have failed.⁶ Other indications for conversion to THA include femoral neck nonunion, significant leg-length discrepancy, and femoral head damage caused by previous internal fixation.⁴

Given these conditions and previous study findings, THA performed in patients with previous hip fracture fixation is potentially more complicated than THA for primary OA. We therefore conducted a study to evaluate differences in sociodemographic factors, surgical details, and outcomes between patients who had THA for posttraumatic OA and patients who had THA for primary OA.

Materials and Methods

After obtaining institutional review board approval and patient consent, we used a prospective database to follow 3844 patients who had THA performed for OA by 1 of 17 different surgeons at a single center over an 8-year period. Patients who had THA for secondary causes of hip OA, developmental hip dysplasia, or inflammatory processes were excluded. Of the

Figure 1. Patient, 65-year-old man. (A) Two years after open reduction and internal fixation of acetabular fracture. (B) One year after uncemented total hip arthroplasty.



Authors' Disclosure Statement: The authors report no actual or potential conflict of interest in relation to this article.

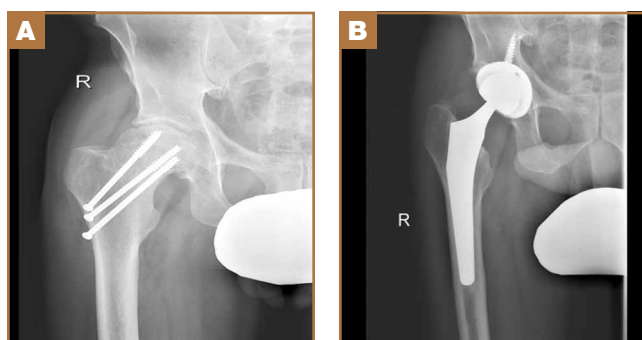


Figure 2. Patient, 51-year-old man. (A) Fourteen months after open reduction and internal fixation of proximal femur fracture. (B) Nine months after uncemented total hip arthroplasty.

remaining 1199 patients, 62 (5.2%) had THA for posttraumatic OA after previous acetabular or proximal femur fracture fixation (Figures 1, 2) (no THA was performed at time of initial fracture treatment), and 1137 had THA for primary OA and served as the control group.

We collected data on age, sex, fracture location, reason for THA, time between open reduction and internal fixation (ORIF) and THA, type of components, cement use, leg-length discrepancy, intraoperative complications, blood loss, operating room time, and postoperative complications. All patients were aseptically at time of THA. All posttraumatic OA patients had previous hardware removed; the extent of hardware removal was dictated by the exposure required for prosthesis implantation. These patients were contacted, and clinical follow-up was assessed with modified Harris Hip Score (HHS).⁸ HHS was determined by Dr. Khurana. Statistical analysis was performed with Student t test and Pearson χ^2 test using PASW Statistics 18 (SPSS, Chicago, Illinois).

The 62 posttraumatic OA patients had 63 fractures, 41 of the proximal femur (femoral neck and intertrochanteric; 65%) and 22 acetabular (35%). This group consisted of 33 females and 29 males. Their mean age at time of THA surgery was 58 years (range, 31-90 years). Mean age of the control patients was 59.4 years (range, 18-95 years). There were 35 right hips and 27 left hips in the posttrauma group. Mean body mass index (BMI) was 28.4 for the posttrauma group and 28.9 for the

control group. There were no differences in age ($P = .451$), sex ($P = .674$), or BMI ($P = .592$) between the 2 groups (Table 1).

All 62 posttraumatic OA patients had complete hospital data, and 32 (52%) of the 62 underwent long-term follow-up (mean, 4.3 years; range, 4 months–10.5 years). At time of attempted contact (mean, 6.79 years after THA), 7 patients were deceased; cause of death was an unrelated medical condition (1) or unknown (6). The rest of the patients did not respond to multiple telephone and mail summons. Primary reasons for conversion to THA included OA (34 patients, 54%), development of osteonecrosis (12 patients, 19%), and nonunion (12 patients, 19%). The rest of the patients had fixation failure. The mechanisms of injury were motor vehicle accidents (30 patients), falls (20), and other causes (15).

Results

Thirty-two (52%) of the posttraumatic OA patients had a preoperative leg-length discrepancy. For these patients, mean time between initial fracture fixation and conversion to THA was 74 months (range, 1-480 months). Four patients required grafting with cancellous autogenous bone graft or allograft chips to fill a bony defect. Mean acetabular component diameter was 54 mm. Nineteen patients had acetabular fixation supplemented with screws. (Screw supplementation data were not recorded for control patients.) Three patients (4.7%) with an acetabular fracture had heterotopic bone removed at time of THA. Two patients underwent neurolysis of the sciatic nerve at time of surgery for preexisting nerve palsy.

Mean postoperative hemoglobin was 109 g/L in the posttraumatic OA group and 121 g/L in the control group ($P < .001$). Mean postoperative hematocrit was 0.327 and 0.367, respectively ($P < .001$). Mean amount of Cell Saver (Haemonetics) used by patients was 176.2 and 72.9 mL, respectively ($P < .001$). Posttrauma patients lost a mean of 360 mL of blood more than control patients did ($P < .001$) and were transfused a mean of 1.59 units of blood, compared with 0.85 unit in the controls ($P < .001$). Patients with acetabular fractures required a mean of only 0.65 unit of transfused blood. Mean operating room time was 240.5 minutes for posttrauma patients and 135.6 minutes for control patients ($P < .001$). In the posttrauma group, mean size of the head of the femoral component was 29 mm (head size was not recorded for the control group). Posttrauma patients had 18 (29%) hybrid cemented hip replacements (femoral component only) and 44 uncemented hip replacements. Data on femoral stem size and type were not reported for either group.

Twenty-four posttrauma patients (39%) had a total of 63 perioperative complications, and 131 control patients (11.5%) had a total of 160 complications ($P < .001$). Complications in posttrauma patients with proximal femur fractures included excess bleeding (5 patients), in-hospital dislocations (2), and postoperative infections (4: 2 superficial

Table 1. Demographics of Patients Who Had THA for Posttraumatic OA and Patients Who Had THA for Primary OA

Demographic	OA Group	
	Posttraumatic	Primary
Age, y	58	59.43
Sex	29 males, 33 females	492 males, 625 females
Side	35 right, 27 left	591 right, 545 left, 1 not recorded
Body mass index	28.37	28.85

Abbreviations: OA, osteoarthritis; THA, total hip arthroplasty.

Table 2. Complications

Complication	Osteoarthritis Group				
	Posttraumatic			Total	Primary
	Acetabular	Femoral	Both		
Intraoperative	2	4	0	6	—
Postoperative	5	13	0	18	—
Bleeding	0	5	0	5	12
Dislocation	1	2	0	3	4
Fever	1	1	0	2	16
Postoperative ileus	1	0	0	1	3
Deep vein thrombosis/pulmonary embolism	0	0	0	0	5
Wound-healing problem	0	2	0	2	12
Infection	0	4	0	4	3
Draining	2	6	0	8	49
Mental	0	5	0	5	15
Cardiac	0	6	0	6	17
Pneumonia	0	1	0	1	2
Urinary retention	0	0	0	0	9
Urinary tract infection	0	1	0	1	13

wound infections, 1 implant infection requiring explant, 1 *Clostridium difficile* infection); in patients with acetabular fractures, there was only 1 dislocation (no infections). The posttraumatic OA group did not develop any symptomatic venous thromboembolic complications. One patient developed a sciatic nerve palsy after surgery. Of the 3 patients who sustained dislocations, 2 were treated with closed reduction and maintenance of implants, and 1 with revision THA. Complications in the control group included 3 infections, 4 dislocations, and 12 cases of extensive blood loss (Table 2).

In patients with long-term follow-up, mean postoperative modified HHS was 81.33 (range, 34.1-100.1). Twelve patients had an excellent score (>90), 10 a good score (80-89), 4 a fair score (70-79), and 6 a poor score (<70). Mean HHS was 84.2 for the 16 patients with a femoral head or neck fracture, 77.7 for the 6 patients with an intertrochanteric fracture, and 84.3 for the 9 patients with an acetabular fracture. Nine patients reported using a cane, 3 required walkers, 2 required wheelchairs, and 18 did not require any walking support. Four (12.5%) of the 32 patients required THA revision a mean of 3.5 years (range, 2 months-8 years) after initial arthroplasty. Reasons for revision were infections (2 patients), multiple dislocations (1), and dissociation of acetabular lining (1) (Table 3). Two of the patients who underwent THA revision had a cemented femoral stem, and 2 did not have any cemented implants. Additional details of the femoral stem components were not available for either group.

Discussion

Patients who develop posttraumatic OA of the hip have limited options. THA has emerged as an excellent option in cases of failed repair of fractures about the hip joint. The results of the

Table 3. Follow-Up Data for Patients Who Had Total Hip Arthroplasty for Posttraumatic Osteoarthritis

Harris Hip Score	
Group mean	81.3
Excellent	12 (37.5%)
Good	10 (31.3%)
Fair	4 (12.5%)
Poor	6 (18.8%)
Femoral head/neck mean	84.2
Intertrochanteric mean	77.7
Acetabular mean	84.3
Ambulatory assistance	
None	18
Cane	9
Walker	3
Wheelchair	2
Revision	
No. of patients	4 (12.5%)
Infection	2
Multiple dislocations	1
Dissociation of acetabular lining	1

present study are consistent with earlier findings of the effectiveness of THA in salvaging posttraumatic hips.²⁻⁷ THA for patients with posttraumatic arthritis of the hip after acetabular or proximal femur fracture is longer and more complicated than THA for primary OA, and there is significantly more blood loss. In addition, the rate of early failure appears to be higher.⁹

In this study, mean amount of blood transfused for patients with previous acetabular fracture was 0.65 unit, much less than the mean of 3.5 units noted by Weber and colleagues.⁶ In their study, complications associated with THA were increased in patients with posttraumatic OA from acetabular fractures. The authors attributed these complications to scarring from previous surgery, retained hardware, heterotopic bone, and residual osseous deformity and deficiency. Our results support their conclusion. Operating times were longer, as well as blood loss and the need for blood transfusions and other blood products were increased in the patients with posttraumatic OA, as compared with patients with primary OA. Fifteen percent of patients with an acetabular fracture had undergone removal of heterotopic bone at time of surgery—similar to the rate of 18% noted in the Weber study.⁶

Our results showed that the rate of revision THA was also higher than in patients with primary THA within the general population—reported to be about 4%.⁹ The higher rate may be the result of the additional surgeries performed on patients with fractures, or hardware retention increasing the infection risk over the years. Our revision rate of 12.5% was similar to the 19% found by Ranawat and colleagues⁷ in their study.

A majority of the patients in our study had favorable long-term HHS. Mean overall HHS was 83, slightly better than the 79 reported by Srivastav and colleagues.⁴ We found that patients with intertrochanteric fractures ultimately had worse outcome scores than patients with acetabular or femoral neck fractures. These results are consistent with findings reported by Mehlhoff and colleagues⁵ in a study comparing patients with femoral neck and intertrochanteric fractures. Mean HHS for the intertrochanteric fracture patients in our study was 77.7, comparable to the mean of 78 reported by Mehlhoff and colleagues.⁵ Mean HHS for the femoral neck or head fractures in our study was 84.2, similar to the mean of 81 they noted. Patients with a previous acetabular fracture in our study had a mean HHS of 84.3, consistent with the 84 reported by Ranawat and colleagues⁷ for patients who had initially undergone ORIF for acetabular fracture. Mean HHS in our study (83) was slightly less than the 88.5 reported by Shi and colleagues¹⁰ in their study of primary THAs.

Few studies have been conducted exclusively on one type of hip fracture (acetabular) or another (proximal femur), and all except 1 did not perform a comparison. Tabsh and colleagues² compared similar cohorts but focused solely on patients with previous proximal femur fractures. The present study included a control group and both acetabular and proximal femur fractures, which allowed us to compare patients with and without previous fracture fixation and to consider the 2 different fracture types and see if they affected outcomes.

The strengths of this study include the large control group

and the relatively short data-collection period. The shorter period decreased the influence of improvements in implants on patient outcomes. In addition, the control group was our own population, as we did not compare our cohort of patients with previous internal fixation and patients who had primary THAs in other studies, aside from comparisons for revision rates and HHS.

Although the ultimate long-term follow-up rate for patients with previous internal fixation was 50%, our sample size was still larger than that in most reported studies. Another weakness of our study was the large number of surgeons (17), representing an array of techniques, approaches, and surgical experience. All these factors could have influenced patient outcomes and operative data. In addition, data on revision rates and HHS were not available for our control group, so we could not directly compare these outcomes with those of the posttraumatic group. However, we used previously reported data on revision rates and HHS in primary THAs for comparison with the posttraumatic group.^{9,10}

Conclusion

In this study, THA was a viable option for patients with posttraumatic arthritis from a previous acetabular or proximal femur fracture. The outcomes, however, were less reliable than the outcomes of primary THA for degenerative arthritis, and the complication rates were higher. Surgeons should counsel patients about the complexity of the procedure as well as its ultimately favorable outcomes. Surgeons should expect additional technical difficulties in the operating room when treating this patient population.

Dr. Khurana is Orthopaedic Surgery Resident, New York Medical College/Westchester Medical Center, Valhalla, New York; and former Research Assistant, New York University Hospital for Joint Disease, New York, New York. Dr. Nobel and Dr. Merkow are former Research Assistants, New York University Hospital for Joint Diseases, New York, New York. Dr. Walsh is Assistant Professor, Epidemiology and Biostatistics, School of Public Health, State University of New York–Downstate, New York, New York. Dr. Egol is Professor and Vice-Chairman, Department of Orthopaedic Surgery, New York University Hospital for Joint Diseases, New York, New York.

Acknowledgments: This study was partially funded by a grant from the New York Arthritis Foundation. The authors thank Raj Karia, MPH, for his help with the statistical analysis.

Address correspondence to: Kenneth A. Egol, MD, Department of Orthopaedic Surgery, New York University Hospital for Joint Diseases, 301 E 17th St, Room 1402, New York, NY 10003 (tel, 212-598-3889; fax, 212-598-6015; email, kenneth.egol@nyumc.org).

Am J Orthop. 2015;44(7):321-325. Copyright Frontline Medical Communications Inc. 2015. All rights reserved.

References

1. Brauer CA, Coca-Perrillon M, Cutler DM, Rosen AB. Incidence and mortality of hip fractures in the United States. *JAMA.* 2009;302(14):1573-1579.
2. Tabsh I, Waddell JP, Morton J. Total hip arthroplasty for complications of proximal femoral fractures. *J Orthop Trauma.* 1997;11(3):166-169.
3. Haidukewych GJ, Berry DJ. Hip arthroplasty for salvage of failed treatment of intertrochanteric hip fractures. *J Bone Joint Surg Am.* 2003;85(5):899-904.

4. Srivastav S, Mittal V, Agarwal S. Total hip arthroplasty following failed fixation of proximal hip fractures. *Indian J Orthop.* 2008;42(3):279-286.
5. Mehlhoff T, Landon GC, Tullos HS. Total hip arthroplasty following failed internal fixation of hip fractures. *Clin Orthop Relat Res.* 1991;(269):32-37.
6. Weber M, Berry DJ, Harmsen WS. Total hip arthroplasty after operative treatment of an acetabular fracture. *J Bone Joint Surg Am.* 1998;80(9):1295-1305.
7. Ranawat A, Zelken J, Helfet D, Buly R. Total hip arthroplasty for posttraumatic arthritis after acetabular fracture. *J Arthroplasty.* 2009;24(5):759-767.
8. Harris WH. Traumatic arthritis of the hip after dislocation and acetabular fractures: treatment by mold arthroplasty. An end-result study using a new method of result evaluation. *J Bone Joint Surg Am.* 1969;51(4):737-755.
9. Mahomed NN, Barrett JA, Katz JN, et al. Rates and outcomes of primary and revision total hip replacement in the United States Medicare population. *J Bone Joint Surg Am.* 2003;85(1):27-32.
10. Shi HY, Mau LW, Chang JK, Wang JW, Chiu HC. Responsiveness of the Harris Hip Score and the SF-36: five years after total hip arthroplasty. *Qual Life Res.* 2009;18(8):1053-1060.

This paper will be judged for the Resident Writer's Award.

AJO

DO NOT COPY