

# Septic Arthritis and Osteomyelitis Caused by *Pasteurella multocida*

Neil Vranis, BA, Ebrahim Paryavi, MD, MPH, Matthew Christian, MD, Manjari Joshi, MBBS, and Raymond A. Pency, MD

## Abstract

This report presents a case of progressive septic arthritis and osteomyelitis caused by a rare pathogen, *Pasteurella multocida*, thought to be provoked by the use of systemic corticosteroids. Despite initial improvement after antibiotics and surgical procedure, the patient returned with new, associated symptoms 1 month later. This concurrent set of circumstances leading to a life-threatening condition has not been reported, to the best of our knowledge. Physicians aware of such a case will be better prepared to diagnose, treat, and educate their patients. Additionally, the diagnostic challenge presented by this case report emphasizes the need for vigilance and thoroughness in obtaining histories from patients presenting with seemingly benign complaints, especially in vulnerable populations, such as infants, pregnant women, and immunocompromised adults.

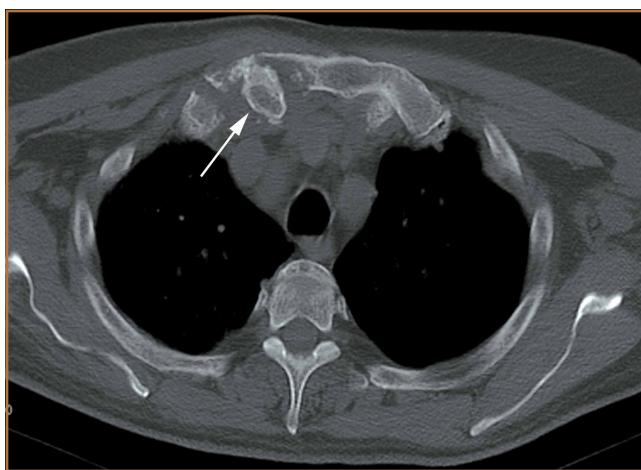
A few days after an incidental cat bite, a patient presented to the emergency department for treatment of poison sumac exposure. He was discharged with oral methylprednisolone for the dermatitis and returned 1 week later with symptoms, examination findings, and laboratory results consistent with sepsis and bilateral upper extremity necrotizing soft-tissue infections. After administering multiple irrigation and débridement procedures, hyperbaric oxygen treatments, and an antibiotic regimen, the patient's status greatly improved. However, the patient returned 1 month later with a new sternoclavicular joint prominence that was associated with painful crepitus. Additionally, he noted that his wrists were gradually becoming more swollen and painful. Imaging studies showed a lytic destruction of the sternoclavicular joint and erosive changes throughout the carpus and radiocarpal joint bilaterally, consistent with osteomyelitis. The patient was treated with ertapenem for 6 weeks, and his polyarthropathy resolved. The patient provided written informed consent for print and electronic publication of this case report.

## Case Report

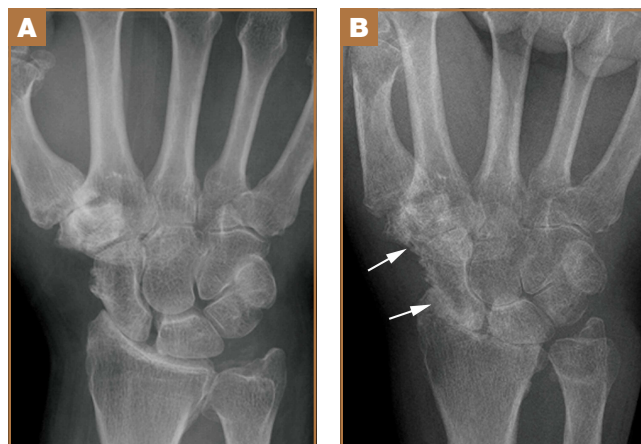
A 73-year-old, right-hand-dominant man with no notable medical history presented to the emergency department for treatment of poison sumac exposure, incidentally, a few days after being bitten by a cat on the bilateral distal upper extremities. He was prescribed a course of oral methylprednisolone for dermatitis. A week later, the patient returned to the emergency department with altered mental status, fevers, diaphoresis, lethargy, and polyarthralgia. At the time of presentation, the patient's vital signs were labile, and he was found to have extensive bilateral upper extremity erythema, blistering, petechiae, purpuric lesions, and exquisite pain with passive range of motion of his fingers and wrists. His leukocyte count was  $25.1 \times 10^9/L$ , and he had elevated C-reactive protein level and erythrocyte sedimentation rate of 150 mg/L and 120 mm/h, respectively. He was admitted for management of sepsis and presumed bilateral upper extremity necrotizing soft-tissue infection.

Broad-spectrum intravenous (IV) antibiotics (vancomycin, piperacillin, tazobactam) were initiated after blood cultures were obtained, and the patient was taken emergently to the operating theatre for irrigation and débridement of his hands and wrists bilaterally. Arthrotomy of the wrist and débridement of the distal extensor compartment and its tenosynovium were performed on the right forearm, in addition to a decompressive fasciotomy of the left forearm. Postoperatively, the patient's mental status improved and his vital signs gradually normalized. He received multiple hyperbaric oxygen treatments and underwent several additional operative débridement procedures with eventual closure of his wounds. At initial presentation, the differential diagnosis for the severe soft-tissue infection included necrotizing fasciitis or myositis caused by any of a variety of bacterial pathogens. Most notably, it was important to elicit the history of a cat bite to include and consider *Pasteurella multocida* as a potential pathogen. Initial cultures supported the diagnosis of acute *P multocida* necrotizing skin and soft-tissue infection, in addition to septic arthritis. The patient's blood and intraoperative wound cultures grew *P multocida*. The antibiotic treatment was tailored initially to ampicillin and sulbactam and then to a final regimen of orally administered ciprofloxacin (750 mg twice a day), once susceptibility testing was performed on the cultures. On hospital day 10, the

**Authors' Disclosure Statement:** The authors report no actual or potential conflict of interest in relation to this article.



**Figure 1.** Axial computed tomography scan of the chest shows bony destruction and loss of congruity of the affected right sternoclavicular joint. Arrow indicates the right sternoclavicular joint.



**Figure 2.** Posteroanterior radiographs of the right wrist, (A) initial presentation and (B) late presentation, show progression of arthrosis caused by chronic *Pasteurella* osteomyelitis. Arrows indicate radiocarpal joint.

patient was discharged home, receiving a 6-week course of ciprofloxacin to complete the 8-week course of treatment.

At follow-up, approximately 1 month after discharge, the patient noted that he had developed a new right sternoclavicular joint prominence that was associated with painful crepitus. He also noted that his wrists were gradually becoming more swollen and painful bilaterally. Computed tomography scans of the chest were obtained to evaluate the sternoclavicular joint (Figure 1). Repeat radiographs of the wrists were also obtained (Figure 2). Imaging showed lytic destruction of the sternoclavicular joint and erosive changes throughout the carpus and radiocarpal joint, consistent with osteomyelitis. The C-reactive protein level and erythrocyte sedimentation rate at this time were 34 mg/L and 124 mm/h, respectively.

The patient returned to the operating room for débridement and biopsy of the right sternoclavicular joint and left wrist.

This patient's delayed presentation was characterized by a subacute worsening of isolated musculoskeletal complaints. The differential diagnosis then included infection with the same bacterial pathogen versus reactive or inflammatory arthritis. Several intraoperative cultures failed to grow any bacteria, including *P multocida*, although *P multocida* was the presumptive cause of the erosive polyarthropathy, considering that symptoms eventually resolved with a repeated course of IV-administered ertapenem for 6 weeks. The patient experienced complete resolution of his joint pain and swelling. He was able to resume his activities of daily living and had no further recurrence of symptoms at follow-up 3 months later.

## Discussion

Cat bites often are the source of *Pasteurella* species infections because the bacteria are carried by more than 90% of cats.<sup>1</sup> These types of infections can cause septic arthritis, osteomyelitis, and deep subcutaneous and myofascial infections because of the sharp and narrow morphology of cat teeth. The infections can progress to necrotizing fasciitis and myositis if not recognized early, as was the case with our patient. Prophylactic antibiotic administration for animal bites is controversial and is not a universal practice.<sup>1,2</sup> *Pasteurella* bacteremia is an atypical progression that occurs more often in patients with pneumonia, septic arthritis, or meningitis. Cases of *Pasteurella* sepsis, necrotizing fasciitis, and septic arthritis have been reported.<sup>3-7</sup> However, associated progressive septic arthritis and osteomyelitis, despite initial clinical improvement, have not been reported. Severe infection (ie, sepsis and septic shock) can occur in infants, pregnant women, and other immunocompromised patients.<sup>7</sup> Immune suppression of our patient with steroid medication for poison sumac dermatitis likely contributed to the progression and systemic spread of an initially benign cat bite. Before prescribing steroids, it is imperative to ask about exposures and encourage patients to seek prompt medical attention with worsening or new symptoms. Healthy individuals rarely develop bacteremia; however, in these cases, mortality remains high at approximately 25%.<sup>4,6</sup>

The clinical course of this case emphasizes the need for vigilance and thoroughness in obtaining histories from patients presenting with seemingly benign complaints, especially in vulnerable populations, such as infants, pregnant women, and immunocompromised adults. In this case, the progression of symptoms might have been avoided if the patient's dermatitis had been treated conservatively or with topical rather than systemic steroids.

Mr. Vranis is Medical Student, University of Maryland School of Medicine; Dr. Paryavi is Attending Physician, Johns Hopkins Bloomberg School of Public Health; Dr. Christian is Resident Physician, Department of Orthopaedics; Dr. Joshi is Attending Physician and Associate Professor of Medicine, R Adams Cowley Shock Trauma Center; and Dr. Pensy is Attending Physician and Assistant Professor of Orthopaedics, Department of Orthopaedics, R Adams Cowley Shock Trauma Center; University of Maryland Medical Center, Baltimore, Maryland.

Acknowledgments: The authors thank senior editor and writer Dori Kelly, MA, for professional editing assistance with the manuscript and figures.

Address correspondence to: Raymond A. Pensy, MD, R Adams Cowley Shock Trauma Center, Department of Orthopaedics, University of Maryland Medical Center, 22 South Greene Street, Baltimore, MD 21201 (tel, 410-328-6280; fax, 410-328-2893; email, rpensy@umoa.umm.edu).

*Am J Orthop.* 2015;44(7):E239-E241. Copyright Frontline Medical Communications Inc. 2015. All rights reserved.

## References

1. Esposito S, Piccioli I, Semino M, Principi N. Dog and cat bite-associated infections in children. *Eur J Clin Microbiol Infect Dis.* 2013;32(8):971-976.
2. Medeiros I, Saconato H. Antibiotic prophylaxis for mammalian bites. *Cochrane Database Syst Rev.* 2001;(2):CD001738.
3. Haybaeck J, Schindler C, Braza P, Willinger B, Drlicek M. Rapidly progressive and lethal septicemia due to infection with *Pasteurella multocida* in an infant. *Wien Klin Wochenschr.* 2009;121(5-6):216-219.
4. Migliore E, Serraino C, Brignone C, et al. *Pasteurella multocida* infection in a cirrhotic patient: case report, microbiological aspects and a review of the literature. *Adv Med Sci.* 2009;54(1):109-112.
5. Mugambi SM, Ullian ME. Bacteremia, sepsis, and peritonitis with *Pasteurella multocida* in a peritoneal dialysis patient. *Perit Dial Int.* 2010;30(3):381-383.
6. Weber DJ, Wolfson JS, Swartz MN, Hooper DC. *Pasteurella multocida* infections. Report of 34 cases and review of the literature. *Medicine (Baltimore).* 1984;63(3):133-154.
7. Oehler RL, Velez AP, Mizrachi M, Lamarche J, Gompf S. Bite-related and septic syndromes caused by cats and dogs. *Lancet Infect Dis.* 2009;9(7):439-447.