

Fingertip Amputation Treatment: A Survey Study

Andrew J. Miller, MD, Michael Rivlin, MD, William Kirkpatrick, MD, Jack Abboudi, MD,
and Christopher Jones, MD

Abstract

Distal fingertip amputations are common injuries in work- and non-work-related accidents. There is a paucity of evidence to support use of any one treatment.

We conducted a study to better understand how surgeon and patient factors influence the treatment preferences for distal fingertip amputations among a cross section of US and international hand surgeons. We sent a 16-question survey to the American Association for Hand Surgery and reciprocal international hand societies and analyzed the response data using a logistic regression model. We hypothesized that hand surgeons' treatment preferences would be varied and influenced by surgeon and patient demographics.

One hundred ninety-eight hand surgeons (62% US, 38% international) responded to the survey. For each clinical scenario (Allen levels 2, 3, and 4 and volar oblique amputations), there were wide variations in treatment preferences. Wound care was less likely performed by surgeons with more than 30 years of experience or plastic surgery backgrounds. Replantation was less likely performed by US surgeons and private practice surgeons. Pedicle and homodigital flaps were more commonly performed internationally. Surgeons in practice for less than 5 years were more likely to perform skeletal shortening.

For all levels and orientations of fingertip amputation queried, there is a wide range of treatment preferences. Our survey results highlight the need for a prospective randomized trial to elucidate the most effective treatments for fingertip amputations.

Finger injuries are common, representing an estimated 3 million emergency department visits per year in the United States, with 44% of these diagnosed as lacerations.¹ Amputations of the finger (partial and complete) in non-work-related accidents alone are estimated at 30,000 per year.¹ The fingertip is a highly specialized structure that contributes to precision function of the hand through tactile feedback and

fine motor control as well as hand aesthetics. An injury can compromise a variety of fingertip structures, including the distal phalanx, which provides length and structural support; the fingernail, germinal matrix, and sterile matrix, which protect the fingertip and function as tools; and the volar skin pad, which is important for sensation and fine motor activity.

There is considerable debate regarding optimal management of fingertip amputations, and to date there have been no prospective, randomly controlled trials to guide treatment.² Injury characteristics, amputation levels, and patient priorities all contribute to management decisions. Treatment goals are to maintain length when possible; to provide stable, supple, and sensate skin coverage; to ensure the nail plate regrows without complication; and to maintain normal overall finger shape and cosmesis. In addition, a simple, cost-effective treatment with short recovery time and no donor-site morbidity is desired.

Treatment recommendations are wide-ranging, and evidence-based literature is sparse. About 30 years ago, 2 retrospective comparative studies found no difference in outcomes between simpler treatments (primary closure, secondary wound healing) and various operative strategies.^{3,4} Since then, most of the scientific studies have been retrospective noncomparative case series, all reporting good to excellent results.⁵⁻¹⁷ Investigators generally implied superior results of a studied procedure over those of more conservative treatments. Recommended treatments include secondary wound healing, simple flaps, staged flaps, pedicle flaps, allograft and autograft coverage, composite grafting, and replantation, for all levels of fingertip injury.

Given our surgical advances, improved techniques, and accumulating experience, we may have expected better outcomes with newer and more complex reconstructive efforts. Unfortunately, in a recent review of 53 fingertip injuries treated with a reconstructive procedure, bone shortening with closure, or secondary healing, Wang and colleagues¹⁸ found no discernible differences in outcomes at 4.5-year follow-up. They questioned whether complex reconstructive procedures are worth the time, expense, and risk. In the absence of prospective, comparative studies, surgeons must rely on anecdotal evidence (including predominantly level IV evidence), training bias, previous experience, and the prevailing common wisdom.

Authors' Disclosure Statement: The authors report no actual or potential conflict of interest in relation to this article.

Toward that end, we became interested in identifying treatment preferences for fingertip amputations. We conducted a study to better understand how surgeon and patient factors influence the treatment preferences for distal fingertip amputations among a cross section of US and international hand surgeons. We hypothesized that hand surgeons' treatment preferences would be varied and influenced by surgeon and patient demographics.

Materials and Methods

An online multiple-choice survey was created and powered by Constant Contact. The survey consisted of 6 surgeon demographic questions; 5 treatment preference questions regarding patient age, sex, occupation, and germinal matrix management; and 5 clinical scenarios based on Allen levels 2, 3 (with and without exposed distal phalanx), and 4 and volar oblique middle-finger amputations. The Allen classification designates level 2 injuries as those involving only the distal pulp and nail.¹⁹ Level 3 injuries also involve the terminal distal phalanx, and level 4 injuries extend to the lunula. The survey questions are listed in the **Appendix**. For the clinical scenario questions, treatment choices included wound care, skeletal shortening and closure, composite graft, autograft, allograft, V-Y/Kutler flap, advancement flap, thenar flap, cross-finger flap, pedicle and homodigital flap, replantation, and other.

An email invitation was sent to members of the American Association for Hand Surgery (AAHS). The survey was also submitted to personal contacts of international hand societies named on the AAHS website to expand the international response. A reminder email was sent 1 week after the original invitation. The survey was closed 5 weeks later, and the responses were analyzed with all non-US hand surgeons grouped collectively as an international group, compared with the US group. Institutional review board approval was not needed for this survey study.

Statistics

A generalized linear regression model was used to implement logistic regression with random effects for question and respondent. This approach accounts for multiple observations from the same respondent, assuming that both respondent and question are random samples from a larger population. The model estimated the probability that a given surgical approach (eg, skeletal shortening, wound care) would be selected, based on the predictors of the US versus international respondent, time in practice, practice type, and whether the fingertip was available. The model returned adjusted odds ratios (ORs) for each predictor, controlling for all the others. By convention, $P < .05$ was considered significant. No attempt was made to prune the model of nonsignificant factors. Analyses were performed using the lme4 package on the R statistical platform (R Foundation for Statistical Computing).

Results

One hundred ninety-eight responses were recorded. Of the 1054 AAHS members invited to take the survey, 174 (US,

international) responded (17% response rate). One hundred twenty-three responses and 62% of the total were generated from US hand surgeons. Fifty-eight percent of US responses were from the Mid-South, Midwest, or Mid-Atlantic region. Fifty-seven percent of international responses were from Brazil and Europe. Respondents' demographic data are listed in **Tables 1 and 2**.

Responses to the 5 clinical scenarios showed a wide variation in treatment preferences. The top 6 preferred treatment selections for an acute, clean long-finger amputation in a

Table 1. Practice Region

Region	n
United States	
Northeast	16
Mid-Atlantic	22
Southeast	13
Midwest	27
Mid-South	22
Central	3
Intermountain West	4
Pacific	16
International	
South America	29
Canada	7
Asia	15
Europe	11
Africa	13

Table 2. Surgeon Demographics

Demographic	%
Experience, y	
<5	23
5-15	28
15-30	36
>30	13
Training background	
Orthopedics	58
Plastic surgery	34
General surgery	4
Academic	
Full-time	29
Part-time	22
Private	43
Operate with fellows	
No	60
<50%	19
>50%	21
Microvascular cases per year, n	
0	23
<3	23
3-10	25
>10	30

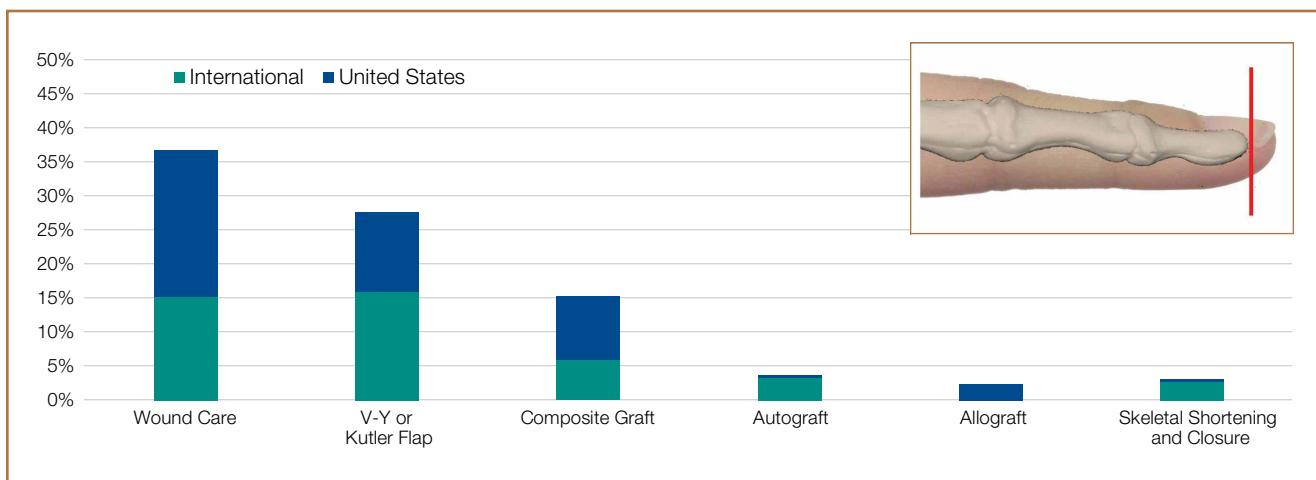


Figure 1. Allen level 2 injuries—6 most common treatment preferences in descending order of use by US and international groups.

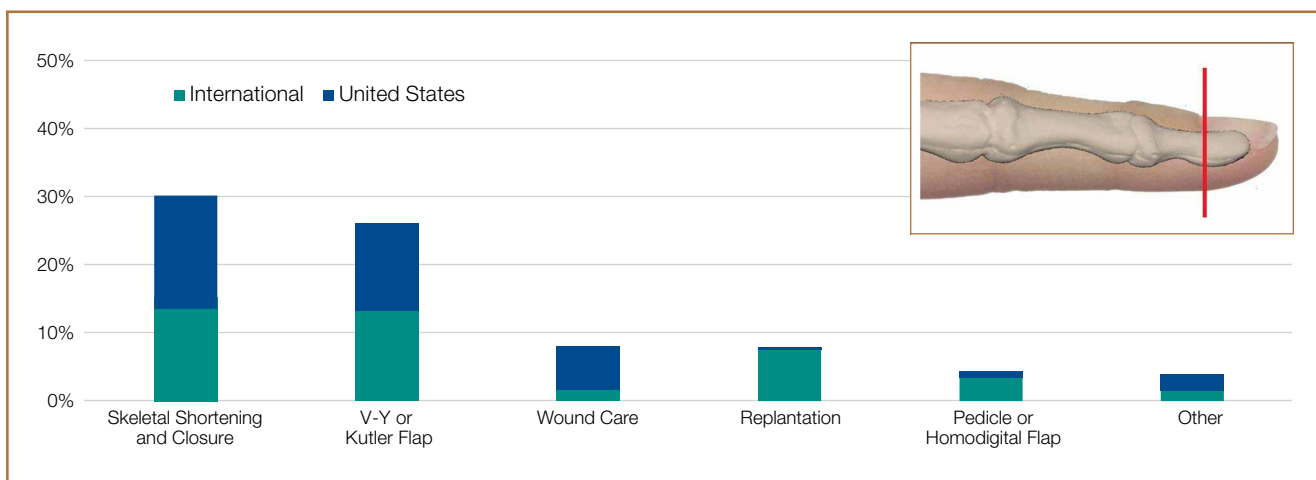


Figure 2. Allen level 3 injuries—6 most common treatment preferences in descending order of use by US and international groups.

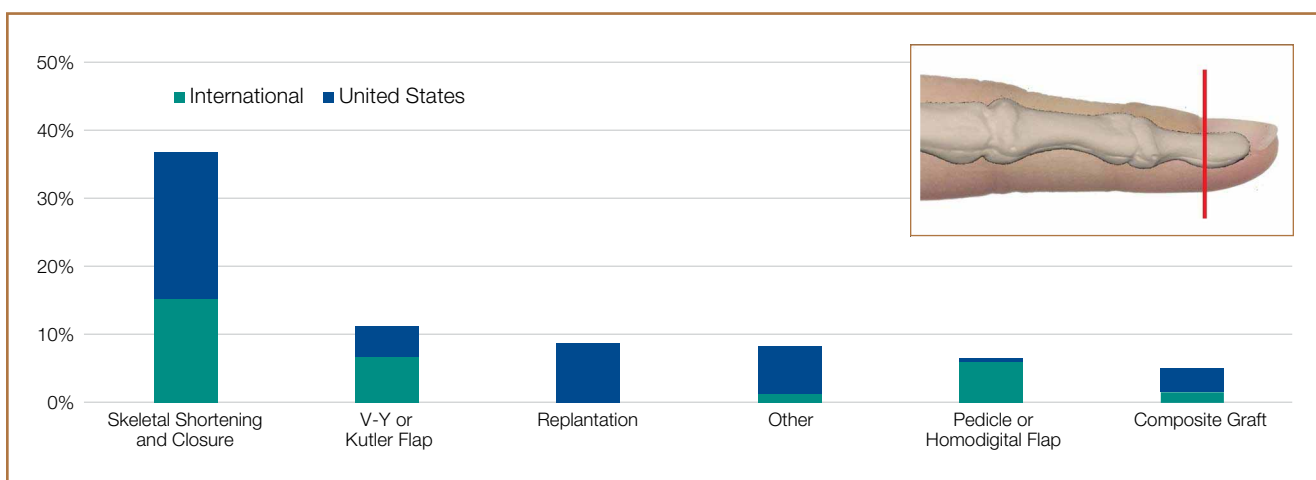


Figure 3. Allen level 3 injuries with 5 mm of bone exposure—6 most common treatment preferences in descending order of use by US and international groups.

healthy 40-year-old office worker are shown in Figures 1 to 5. When surgeons who preferred replant were asked what they would do if the amputated part was not available, they indicated flap coverage more often than less complex treatments, such as skeletal shortening/primary closure or wound care.

There were statistically significant differences in treatment preferences between US and international hand surgeons when controlling for all other demographic variables. Adjusted ORs and their confidence intervals (CIs) for the aggregate clinical scenarios are presented in a forest plot in Figure 6. Figure 4 shows that US surgeons were more likely to choose wound care (OR, 3.6; $P < .0004$) and less likely to attempt a replant (OR, 0.01; $P < .0001$). US surgeons were also less likely to use a pedicle or homodigital island flap when the amputated fingertip was both available (OR, 0.04; $P = .039$) and unavailable (OR, 0.47; $P = .029$).

Among all respondents and across all clinical scenarios,

skeletal shortening with closure was favored among hand surgeons in practice less than 5 years compared with those in practice longer (OR, 2.11; 95% CI, 1.36-3.25; $P = .0008$). Similarly, surgeons with more than 30 years of experience were the least likely to favor wound care (OR, 0.2; 95% CI, 0.09-0.93; $P = .037$). Compared with orthopedic surgeons, plastic surgeons opted for wound care less often (OR, 0.44; 95% CI, 0.23-0.98; $P = .018$) and appeared to prefer replantation, but the difference was not statistically significant (OR, 8.86; 95% CI, 0.99-79.61; $P = .054$).

Replantation was less often chosen by private practice versus full-time academic surgeons (OR, 0.09; 95% CI, 0.01-0.91; $P = .041$.) Part-time academics were no more or less likely to perform replantation than full-time academics were (OR, 0.52; 95% CI, 0.05-5.41; $P = .58$). Of the 59 respondents who performed more than 10 microvascular cases a year, 18 (31%) chose replant for Allen level 4 amputations. In comparison,

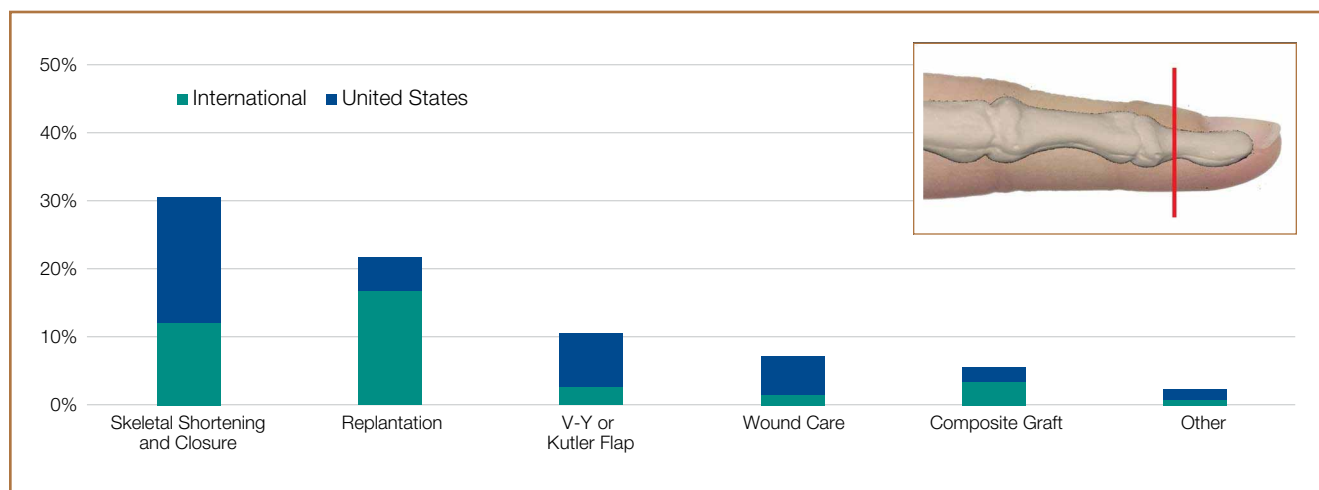


Figure 4. Allen level 4 injuries—6 most common treatment preferences in descending order of use by US and international groups.

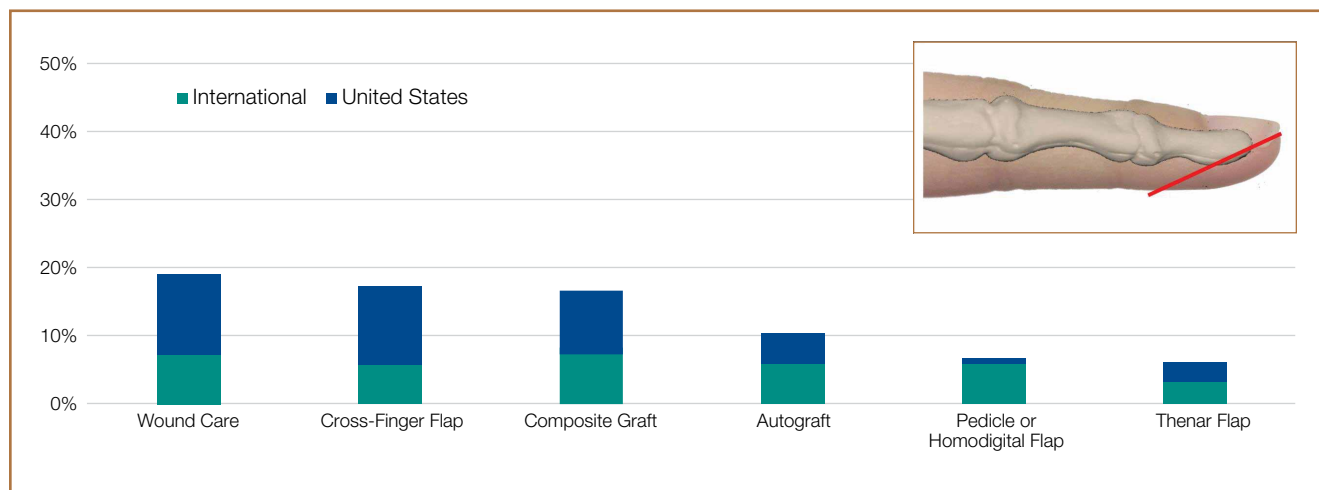


Figure 5. Volar oblique injuries—6 most common treatment preferences in descending order of use by US and international groups.

9 (20%) of the 45 respondents who performed fewer than 3 microvascular cases a year chose replant for amputations at this level. Amount of time working with fellows did not affect treatment preferences.

Patient demographics (age, sex, occupation) also played a role in treatment decisions (Table 3). The most significant factors appeared to be age and occupation. Regarding age, 41% of respondents chose more complex procedures for patients younger than 15, and 62% chose less complex procedures for patients older than 70 years. Regarding occupation, 61% chose more complex procedures for professional musicians, and 60% chose less complex procedures for manual laborers. Sex did not influence clinical decisions for 78% of respondents. There was also substantial variation in both the indications for germinal matrix ablation and the frequency of sterile matrix transplant (Table 3).

Discussion

Although there is a variety of treatment options and published treatment guidelines for distal fingertip amputations, few comparative studies support use of one treatment over another. In our experience, treatment decisions are based mainly on injury parameters, but surgeon preference and patient factors (age, sex, occupation) can also influence care. Our goal in this study was to better understand how surgeon and patient factors influence treatment preferences for distal fingertip amputations among a cross section of US and international hand surgeons. Our survey results showed lack of consensus among hand surgeons and highlighted several trends.

As expected, we found a wide range of treatment prefer-

Table 3. Patient Demographic Impact

Does gender impact treatment?	%
No	78
More complex with females	20
Less complex with females	3
More complex with males	1
Less complex with males	8
<hr/>	
Does age impact treatment?	%
No	20
More complex with <15 y	41
Less complex with <15 y	20
More complex with >70 y	0
Less complex with >70 y	62
<hr/>	
Does occupation impact treatment?	%
No	21
More complex with a musician	61
Less complex with a musician	2
More complex with a manual laborer	5
Less complex with a manual laborer	60
<hr/>	
When is the germinal matrix ablated?	%
Never	10
<25% sterile matrix intact	22
<10% sterile matrix intact	32
No underlying bony defect	62
Mangling injury to sterile matrix	38
<hr/>	
How often is the germinal matrix transplanted?	%
Never	46
<1% fingertip injuries	31
1%-5% fingertip injuries	10
>5% fingertip injuries	2

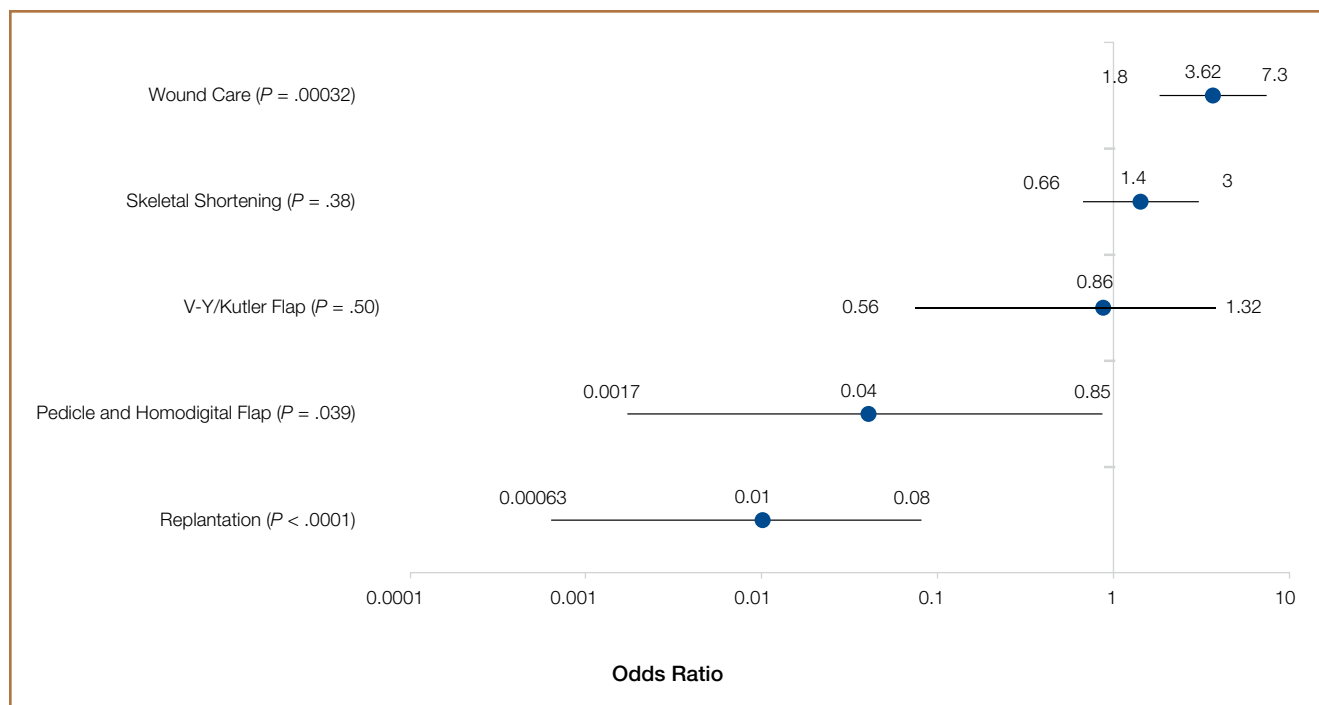


Figure 6. US and international groups' treatment preferences on forest plot with odds ratios on x-axis and corresponding confidence intervals for each treatment.

ences for each clinical scenario queried, ranging from more simple treatments (eg, wound care) to more complex ones (eg, replantation). With patient parameters (age, profession, finger, acuity, injury type, tissue preservation, smoking status) standardized in the clinical scenarios, the treatment differences noted should reflect surgeon preference. However, other patient factors (eg, cultural differences, religious beliefs, surgeon setting, practice pattern, resource availability) that were not included in the clinical scenarios could also affect treatment preferences.

One particularly interesting finding was that international hand surgeons were 6.8 times more likely to replant a distal fingertip amputation. One possible explanation for this variation is the influence of cultural differences. For example, in East Asian countries, there can be a cultural stigma associated with loss of a fingertip, and therefore more of a desire on the part of the patient to restore the original finger.^{20,21} In addition, the international respondents were biased toward academic practices—which could skew the treatment preference toward replantation, as we found that academic surgeons were more inclined to replantation.

Our finding that replantation was more commonly preferred by academic versus private practice surgeons may suggest a training bias, an affinity for more complex or interesting procedures, or access to hospital equipment and staff, including residents and fellows, not usually found at smaller community hospitals, where private practice surgeons are more commonly based. Jazayeri and colleagues²² found that institutions specializing in microsurgery often produced better outcomes than nonspecializing institutions. Therefore, it is not surprising that private practice hand surgeons may less often opt to replant a distal fingertip amputation. It is also not surprising that plastic surgeons are more inclined to perform a replantation or flap coverage, as their training is more microsurgery-intensive and their practice more focused on aesthetics compared with the other specialists.

Distal fingertip replantation is accepted by most as technically demanding, but it seems that the additional effort and resources would be justified if the procedure provided a superior outcome. However, other factors, such as cost of treatment and length of recovery, should also be considered. Average replantation cost has been estimated to range from \$7500 to \$14,000, compared with \$2800 for non-replantation-related care, and median stay is about 4 days longer for replantation-related care.^{23,24} These estimates do not include indirect costs, such as for postoperative rehabilitation, which is likely longer and more expensive, even in distal fingertip replantation. These disparities may not justify the outcome (of having a complete fingertip) if more conservative treatments yield similar results.^{17,18} In addition, there is the expected failure rate of limb replantation surgery. In analysis of the overall societal costs and benefits of larger upper extremity limb replantation, the loss of invested resources sustained with failed limb replantation may be outweighed by the benefit of another patient having a successful outcome. In the case of fingertip replantation, however, does the undefined benefit of the successful patient outcome outweigh the investment of resources lost in cases of

replantation failure? Understandably, there is a need for more robust clinical outcome and cost-comparative evidence to better inform decisions regarding distal fingertip amputation.

We found that wound care and skeletal shortening with primary closure (particularly with Allen level 3 injuries) were preferred more by surgeons within the first 5 years of practice. This finding seems to imply a lack of experience or confidence on the part of younger surgeons performing more complex procedures, such as flap coverage. Conversely, this finding may indicate a shift in treatment principle based on recent literature suggesting equivalent outcomes with simpler procedures.^{17,18} Although our survey study did not provide an option for treatment combinations or staged procedures, several respondents wrote in that skeletal shortening supplemented with various types of autografts and allografts would be their preferred treatment.

Patient factors also play a significant role in clinical decisions. Age and profession seem to be important determinants, with more than 50% of respondents, on average, changing their treatment recommendation based on these 2 factors. A majority of respondents would perform a less involved procedure for a manual laborer, suggesting a quicker return to work is prioritized over a perceived improved clinical outcome. Interestingly, for patients younger than 15 years, the preference was divided, with 41% of surgeons opting for a more complex procedure. This suggests the importance of restoring anatomy in a younger patient, or the perceived decreased risk or failure rate with more involved treatment. Twenty percent preferred a less complex procedure in a younger patient, perhaps relying on the patient's developmental potential for a good outcome or suggesting a concern for patient intolerance or compliance with complex surgery.

Nail plate regrowth can be a problem with fingertip amputations. Nail deformity is highly correlated with injury level, with amputations proximal to the lunula more likely to cause nail plate deformity.^{25,26} Jebson and colleagues²⁷ recommended germinal matrix ablation for amputations proximal to the lunula. We found respondents often performed ablations for other indications, including injured or minimal remaining sterile matrix and lack of bony support for the sterile matrix. Forty-six percent of respondents had never performed sterile matrix transplant, which could indicate that they were unfamiliar with the technique or had donor-site concerns, or that postinjury nail deformities are uncommon, well tolerated, or treated along with other procedures, such as germinal matrix ablation.

Several weaknesses of this study must be highlighted. First, our response rate was smaller than desired. Although this work incorporated a large number of surgeon responses, nearly 200, the response rate was only 17%. In addition, although number of responses was likely adequate to show the diversity of opinion, the preferences and trends reported might not be representative of all hand surgeons. We could not perform a nonresponder analysis because of a lack of specific demographic data for the AAHS and international hand society members. However, AAHS has an approximate 50/50 mix of plastic and orthopedic surgeons, similar to our responder demographic, suggesting our smaller subset of responses might

be representative of the whole. According to AAHS, a majority of its members are “academic” hand surgeons, so our results might not adequately reflect the preferences of community hand surgeons and ultimately might overstate the frequency of more complex treatments. Last, our international response was limited to a few countries. A larger, more broadly distributed response would provide a better understanding of regional preferences, which could shed light on the importance of cultural differences.

Variations in patient insurance status were not queried in this survey but might also affect treatment decisions. More involved, costly, and highly reimbursing procedures might be deemed reasonable options for a small perceived clinical benefit for insured patients.

When multiple digits or the thumb is injured, or there are other concomitant injuries, surgeons may alter their choice of intervention. In mangled extremities, preservation of salvageable functional units takes precedence over aesthetics and likely affects choice of treatment for the amputated fingertips. Similarly, multiple fingertip amputations, even if all at the same level, may be differently regarded than a solitary injury.

Conclusion

For distal fingertip amputations, there is little evidence supporting one approach over another. Without level I comparative data guiding treatment, anecdotal evidence and surgeon personal preferences likely contribute to the large variation noted in this survey. Our study results showed the disparity of fingertip treatment preferences among a cross section of US and international hand surgeons. More important, results underscored the need for a well-designed comparative study to determine the most effective treatments for distal fingertip amputations.

Dr. Miller is Orthopaedic Resident, Thomas Jefferson University Hospital, Philadelphia, Pennsylvania. Dr. Rivlin is Clinical Instructor, Department of Orthopaedic Surgery, Jefferson Medical College, Philadelphia, Pennsylvania. Dr. Kirkpatrick is Associate Clinical Professor of Orthopaedic Surgery, Thomas Jefferson University Hospital, Philadelphia, Pennsylvania. Dr. Abboudi and Dr. Jones are Clinical Instructors, Department of Orthopaedic Surgery, Jefferson Medical College, Philadelphia, Pennsylvania.

Address correspondence to: Andrew J. Miller, MD, 1023 Clinton St, Apartment 303, Philadelphia, PA 19107 (tel, 484-432-8781; fax, 610-527-0142; email, andrewmiller28@gmail.com).

Am J Orthop. 2015;44(9):E331-E339. Copyright Frontline Medical Communications Inc. 2015. All rights reserved.

References

- Conn JM, Annest JL, Ryan GW, Budnitz DS. Non-work-related finger amputations in the United States, 2001-2002. *Ann Emerg Med.* 2005;45(6):630-635.
- Bickel KD, Dosanjh A. Fingertip reconstruction. *J Hand Surg Am.* 2008;33(8):1417-1419.
- Söderberg T, Nyström Å, Hallmans G, Hultén J. Treatment of fingertip amputations with bone exposure. A comparative study between surgical and conservative treatment methods. *Scand J Plast Reconstr Surg.* 1983;17(2):147-152.
- Braun M, Horton RC, Snelling CF. Fingertip amputation: review of 100 digits. *Can J Surg.* 1985;28(1):72-75.
- Sammur D. Fingertip injuries. A review of indications and methods of management. *Curr Orthop.* 2002;16:271-285.
- Mennen U, Wiese A. Fingertip injuries management with semi-occlusive dressing. *J Hand Surg Br.* 1993;18(4):416-422.
- Atasoy E, Ioakimidis E, Kasdan ML, Kutz JE, Kleinert HE. Reconstruction of the amputated fingertip with a triangular volar flap. A new surgical procedure. *J Bone Joint Surg Am.* 1970;52(5):921-926.
- Kutler W. A new method for finger tip amputation. *J Am Med Assoc.* 1947;133(1):29-30.
- Takeishi M, Shinoda A, Sugiyama A, Ui K. Innervated reverse dorsal digital island flap for fingertip reconstruction. *J Hand Surg Am.* 2006;31(7):1094-1099.
- Tuncali D, Barutcu AY, Gokrem S, Terzioglu A, Aslan G. The hatchet flap for reconstruction of fingertip amputations. *Plast Reconstr Surg.* 2006;117(6):1933-1939.
- Teoh LC, Tay SC, Yong FC, Tan SH, Khoo DB. Heterodigital arterialized flaps for large finger wounds: results and indications. *Plast Reconstr Surg.* 2003;111(6):1905-1913.
- Nishikawa H, Smith PJ. The recovery of sensation and function after cross-finger flaps for fingertip injury. *J Hand Surg Br.* 1992;17(1):102-107.
- Rinker B. Fingertip reconstruction with the laterally based thenar flap: indications and long-term functional results. *Hand.* 2006;1(1):2-8.
- Jung MS, Lim YK, Hong YT, Kim HN. Treatment of fingertip amputation in adults by palmar pocketing of the amputated part. *Arch Plast Surg.* 2012;39(4):404-410.
- Venkatramani H, Sabapathy SR. Fingertip replantation: technical considerations and outcome analysis of 24 consecutive fingertip replantations. *Indian J Plast Surg.* 2011;44(2):237-245.
- Chen SY, Wang CH, Fu JP, Chang SC, Chen SG. Composite grafting for traumatic fingertip amputation in adults: technique reinforcement and experience in 31 digits. *J Trauma.* 2011;70(1):148-153.
- van den Berg WB, Vergeer RA, van der Sluis CK, Ten Duis HJ, Werker PM. Comparison of three types of treatment modalities on the outcome of fingertip injuries. *J Trauma Acute Care Surg.* 2012;72(6):1681-1687.
- Wang K, Sears ED, Shauver MJ, Chung KC. A systematic review of outcomes of revision amputation treatment for fingertip amputations. *Hand.* 2013;8(2):139-145.
- Allen MJ. Conservative management of finger tip injuries in adults. *Hand.* 1980;12(3):257-265.
- Chen CT, Wei FC, Chen HC, Chuang CC, Chen HT, Hsu WM. Distal phalanx replantation. *Microsurgery.* 1994;15(1):77-82.
- Kim WK, Lim JH, Han SK. Fingertip replantations: clinical evaluation of 135 digits. *Plast Reconstr Surg.* 1996;98(3):470-476.
- Jazayeri L, Klausner JQ, Chang J. Distal digital replantation. *Plast Reconstr Surg.* 2013;132(5):1207-1217.
- Hattori Y, Doi K, Sakamoto S, Yamasaki H, Wahegaonkar A, Addosooki A. Fingertip replantation. *J Hand Surg Am.* 2007;32(4):548-555.
- Goldner RD, Stevanovic MV, Nunley JA, Urbaniak JR. Digital replantation at the level of the distal interphalangeal joint and the distal phalanx. *J Hand Surg Am.* 1989;14(2 pt 1):214-220.
- Nishi G, Shibata Y, Tago K, Kubota M, Suzuki M. Nail regeneration in digits replanted after amputation through the distal phalanx. *J Hand Surg Am.* 1996;21(2):229-233.
- Yamano Y. Replantation of the amputated distal part of the fingers. *J Hand Surg Am.* 1985;10(2):211-218.
- Jebson PJ, Louis DS, Bagg M. Amputations. In: Wolfe SW, Pederson WC, Hotchkiss RN, Kozin SH, eds. *Green's Operative Hand Surgery.* 6th ed. Philadelphia, PA: Churchill Livingstone; 2010:1885-1927.

This paper will be judged for the Resident Writer's Award.

Appendix. Example of Fingertip Amputation Survey

I. Years in practice since completion of training?

- <5
- 5-15
- 15-30
- >30

II. What is your primary training/current surgical focus?

- Orthopedic surgery
- Plastic surgery
- General surgery
- Other _____

III. How would you describe your practice?

- Full-time academic
- Part-time academic
- Private practice
- Other _____

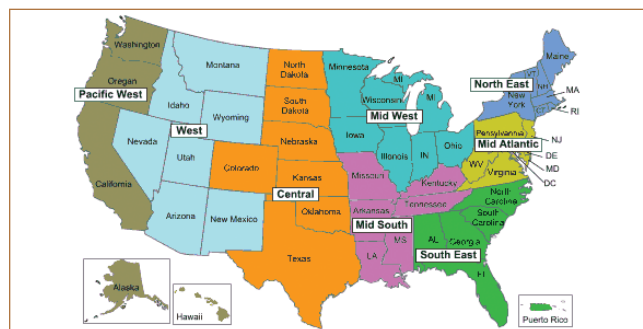
IV. Do you work with hand surgery fellows?

- Not at all
- Less than 50% of your cases
- More than 50% of your cases

V. Do you perform microvascular repair/reconstruction of arteries or veins in your current practice?

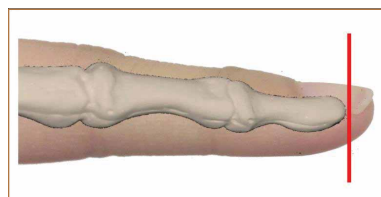
- Not at all
- Less than 3 cases per year
- 3-10 cases per year
- More than 10 cases per year

VI. Where do you practice?



- Northeast (Connecticut, Maine, Massachusetts, New Hampshire, New York, Rhode Island, Vermont)
- Mid-Atlantic (Delaware, District of Columbia, Maryland, New Jersey, Pennsylvania, Virginia, West Virginia)
- Southeast (Alabama, Florida, Georgia, North Carolina, Puerto Rico, South Carolina)
- Midwest (Illinois, Indiana, Iowa, Michigan, Minnesota, Missouri, Ohio, Wisconsin)
- Mid-South (Arkansas, Kentucky, Louisiana, Mississippi, Tennessee)
- Central (Colorado, Kansas, Nebraska, North Dakota, Oklahoma, South Dakota, Texas)
- Intermountain West (Arizona, Idaho, Montana, Nevada, New Mexico, Utah, Wyoming)
- Pacific (Alaska, California, Hawaii, Oregon, Washington)
- Other _____

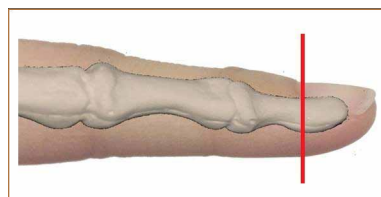
1. A 40-year-old healthy male office worker presents with a long-finger tip amputation 1 hour after a knife laceration. He has a transverse, clean, distal tip amputation at the following level. Surrounding soft tissues are healthy. He does not smoke. He brings the amputated tip, appropriately transported and in good condition.



What is your preferred treatment?

- Wound care, allow to heal by secondary intention
- Autograft skin (split or full-thickness)
- Allograft skin (Integra LifeSciences dermal regeneration template)
- Composite graft using amputated part
- Skeletal shortening with primary closure
- V-Y flap, either volar or lateral (Kutler flap)
- Advancement flap—volar, step, etc
- Cross-finger flap
- Thenar flap
- Pedicle flap, homodigital or other
- Replantation
- Other _____

2. Consider the same patient but with a transverse, clean, distal tip amputation at the following level. The bone is flush with the soft tissues. He brings the amputated tip, appropriately transported and in good condition.



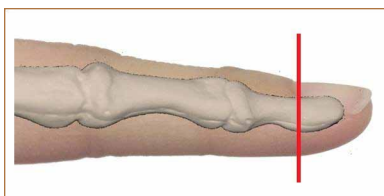
What is your preferred treatment?

- Wound care, allow to heal by secondary intention
- Autograft skin (split or full-thickness)
- Allograft skin (Integra LifeSciences dermal regeneration template)
- Composite graft using amputated part
- Skeletal shortening with primary closure
- V-Y flap, either volar or lateral (Kutler flap)
- Advancement flap—volar, step, etc
- Cross-finger flap
- Thenar flap
- Pedicle flap, homodigital or other
- Replantation
- Other _____

Continued on page E339

Appendix. Example of Fingertip Amputation Survey (continued)

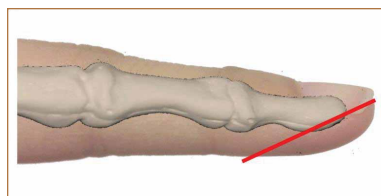
3. Consider the same patient but with the distal phalanx protruding 5 mm beyond the amputation level (without soft-tissue coverage). He brings the amputated tip, appropriately transported and in good condition.



What is your preferred treatment?

- Wound care, allow to heal by secondary intention
- Autograft skin (split or full-thickness)
- Allograft skin (Integra LifeSciences dermal regeneration template)
- Composite graft using amputated part
- Skeletal shortening with primary closure
- V-Y flap, either volar or lateral (Kutler flap)
- Advancement flap—volar, step, etc
- Cross-finger flap
- Thenar flap
- Pedicle flap, homodigital or other
- Replantation
- Other _____

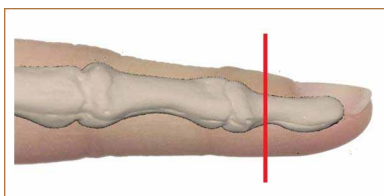
5. Consider the same patient but with a volar oblique amputation as shown below. The periosteum is not violated. He brings the amputated soft tissues, appropriately transported and in good condition.



What is your preferred treatment?

- Wound care, allow to heal by secondary intention
- Autograft skin (split or full-thickness)
- Allograft skin (Integra LifeSciences dermal regeneration template)
- Composite graft using amputated part
- Skeletal shortening with primary closure
- V-Y flap, either volar or lateral (Kutler flap)
- Advancement flap—volar, step, etc
- Cross-finger flap
- Thenar flap
- Pedicle flap, homodigital or other
- Replantation
- Other _____

4. Consider the same patient but with a clean transverse amputation at the level shown below. The bone is flush with the soft tissues. He brings the amputated tip, appropriately transported and in good condition.



What is your preferred treatment?

- Wound care, allow to heal by secondary intention
- Autograft skin (split or full-thickness)
- Allograft skin (Integra LifeSciences dermal regeneration template)
- Composite graft using amputated part
- Skeletal shortening with primary closure
- V-Y flap, either volar or lateral (Kutler flap)
- Advancement flap—volar, step, etc
- Cross-finger flap
- Thenar flap
- Pedicle flap, homodigital or other
- Replantation
- Other _____