

Technique of Open Reduction and Internal Fixation of Comminuted Proximal Humerus Fractures With Allograft Femoral Head Metaphyseal Reconstruction

Stephen A. Parada, MD, Amun Makani, MD, Monica J. Stadecker, BS, and Jon J. P. Warner, MD

Abstract

Proximal humerus fractures are common injuries that can require operative treatment. Different operative techniques are available, but the hallmark of fixation for 3- and 4-part fractures is a locking-plate-and-screw construct. Despite advances in this technology, obtaining anatomical reduction and fracture union can be difficult, and complications (eg, need for revision) are not uncommon.

These issues can be addressed by augmenting the fixation with an endosteally placed fibular allograft. Although biomechanical and clinical results have been good, the technique can lead to difficulties in future revision to arthroplasty, a common consequence of failed open reduction and internal fixation.

The technique described, an alternative to placing a long endosteal bone graft, uses a trapezoidal, individually sized pedestal of allograft femoral head to facilitate the reduction and healing of the humeral head and tuberosity fragments in a displaced 3- or 4-part fracture of the proximal humerus. It can be easily incorporated with any plate-and-screw construct and does not necessitate placing more than 1 cm of bone into the humeral intramedullary canal, limiting the negative effects on any future revision to arthroplasty.

Proximal humerus fractures are exceedingly common and account for almost 5% of all fractures. As osteoporosis is a risk factor for these fractures, their incidence rises with patient age.¹

In 1970, Neer² described these type of fractures and classified them as having 2, 3, or 4 parts based on the amount of angulation and displacement of the humeral head and the greater and lesser tuberosities with respect to the shaft.

Three- and 4-part proximal humerus fractures can be

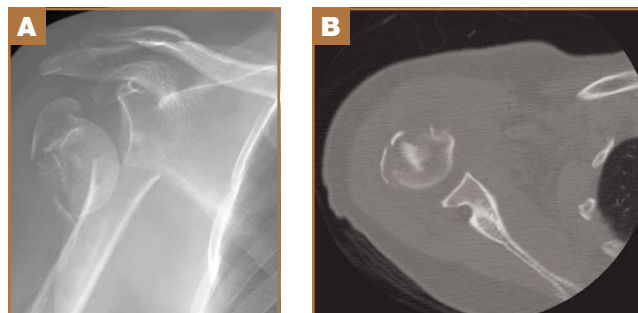
treated either nonoperatively, or surgically with closed reduction and percutaneous fixation, intramedullary fixation, open reduction and internal fixation (ORIF), or arthroplasty. There remains controversy over the best treatment, but a key component of any surgical treatment is anatomical reduction, stable fixation, and then healing of the tuberosities. A current common form of treatment is augmentation with an allograft fibula placed in the medullary canal. Although not formally reported, anecdotal evidence demonstrates that revision to arthroplasty is very difficult in the setting of an ingrown graft in the medullary canal of the humerus.

In this article, we present a novel technique of using allograft femoral head to reconstruct the metaphysis in ORIF of comminuted proximal humerus fractures.

Technique

Presented in **Figure 1** are preoperative images of a representative displaced 4-part proximal humerus fracture treated surgically using the technique described here. General anesthesia is used. After intubation on the operating table, the patient is placed in the beach-chair position with about 75° of hip flexion. All bony prominences are padded, and the head and trunk are well

Figure 1. (A) Preoperative anteroposterior radiograph shows comminuted proximal humerus fracture with wide displacement of humeral neck. (B) Axial computed tomography shows comminution of greater tuberosity.



Authors' Disclosure Statement: The authors report no actual or potential conflict of interest in relation to this article.

secured. A pneumatic arm positioner is used to alleviate the need for an assistant to manipulate the arm. An image intensifier is used before preparing to verify that appropriate images of the proximal humerus can be obtained. Once adequate images are confirmed, the floor can be marked at the position of the fluoroscopic unit's wheels to allow easy reproduction of images once the arm is prepared and draped. The intensifier is then removed from the field, the shoulder is prepared and draped in usual fashion, and prophylactic antibiotics are administered.

A deltopectoral incision is used, and sharp dissection is made through the subcutaneous tissue to raise full-thickness subcutaneous flaps on each side. The deltopectoral interval is sharply dissected while protecting the cephalic vein. Subdeltoid adhesions are then released. Palpation of the axillary nerve in the quadrilateral space to identify its location is helpful to avoid injury during the procedure.

The fracture is then identified, and No. 5 permanent suture

is placed through the posterior and superior rotator cuff and through the subscapularis insertion (Figure 2). The tuberosities are freed from the humeral head sharply. A blunt elevator is then used to gently elevate the humeral head upward, with care taken to avoid comminuting the metaphyseal bone while levering. Reduction is achieved by manipulating the sutures and levering the head with the elevator while placing the arm in extension and posterior translation. Fluoroscopic images are used to verify correct anatomical alignment. Generally, the metaphysis demonstrates comminution and impaction, with poor bone quality necessitating use of bone graft.

A frozen allograft femoral head is then obtained and split into 2 equal pieces using a saw (Figures 3–5). One piece is fashioned with a saw and a burr into a trapezoid such that the proximal portion is wider, and the distal, tapered portion is sized to fit the canal. The broad, proximal portion of the graft will serve as a pedestal to reduce the head to the shaft. Measur-

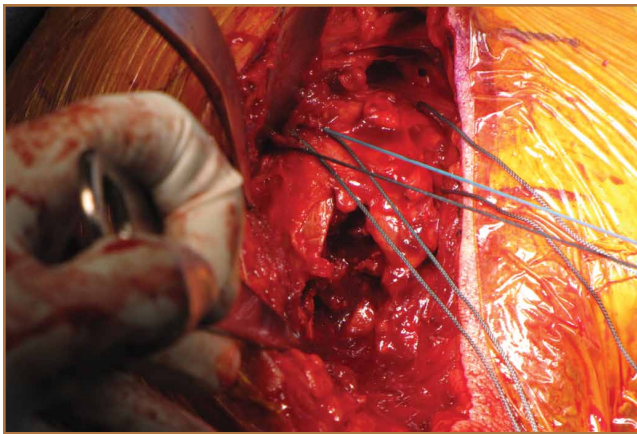


Figure 2. Intraoperative view of right shoulder in beach-chair position. No. 5 sutures are placed in distal rotator cuff to control tuberosity fragments.

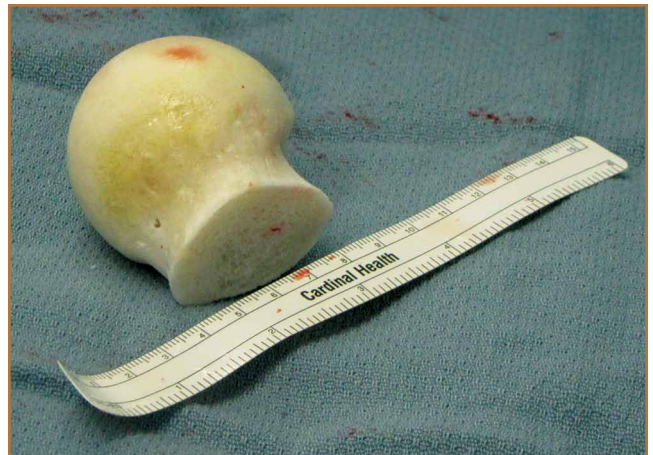

Figure 3. Entire allograft femoral head on back table before preparation.

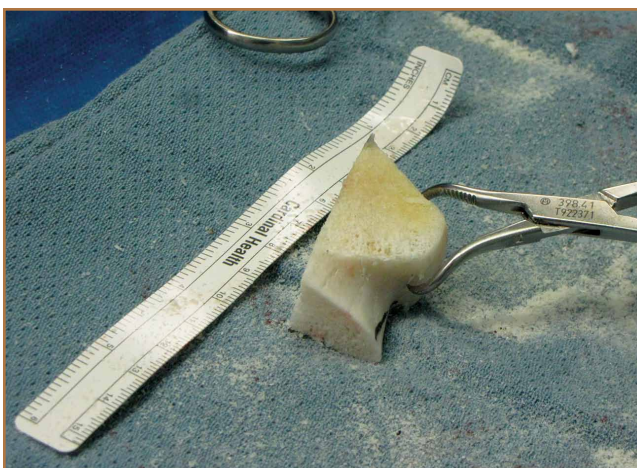


Figure 4. Oscillating saw is used to cut piece of femoral head into slightly larger than desired length and width to match corresponding anatomy.

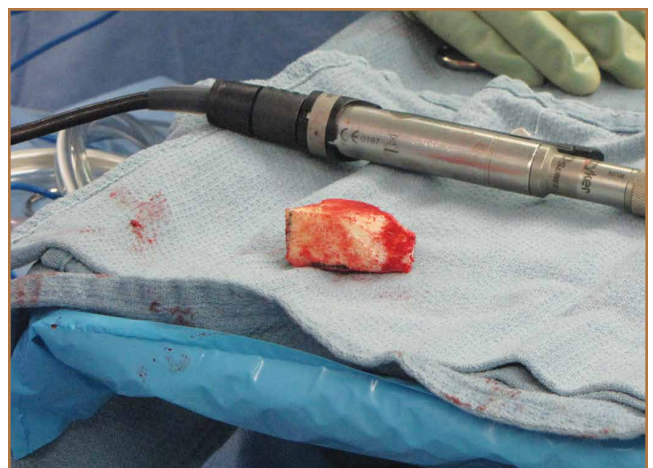

Figure 5. Allograft femoral head is fashioned with saw and burr into trapezoidal piece that is broader laterally and proximally and tapers distally to fit intramedullary canal.

ing the internal diameter of the humeral canal can be useful in estimating the necessary dimensions of the distal portion of the allograft. The graft often needs several small adjustments that necessitate attempting to place it in the intramedullary canal and then trimming as necessary to ensure proper fit distally within the shaft. For this reason, it is beneficial to perform the graft preparation near the surgical field. Once completed, the distal portion is then impacted into the humeral canal (**Figure 6**). Because of this impaction, there is no possibility for subsidence or pistoning of the graft within the canal, which can occur with a fibular graft. The humeral head is reduced onto the shaft with the already placed sutures; this is achieved by abducting the shoulder. The image intensifier is then used to confirm appropriate alignment and positioning of the fragments, making sure that both neck–shaft angle and medial calcar alignment have been restored (**Figures 7, 8**).

An appropriately sized proximal humerus plate is then selected based on the location of the fracture line. We have used standard lateral proximal humerus locking plates as well as laterality-specific anterolateral proximal humerus plates and found that both are suitable for incorporation of the screws through the graft and into the head. The plate is positioned on the humerus, and a guide pin is placed by hand through the proximal-most hole so that the appropriate height of the plate can be verified on fluoroscopy. The first screw is then a nonlocking bicortical screw placed through the oval hole in the shaft of the plate to allow further fine manipulation of the plate more proximally or distally as needed. The final height is confirmed, and the screw is firmly tightened (**Figure 9**). The locking-screw guide is fixed to the proximal portion of the plate, and 2 locking screws are then placed into the head. The arm is then rotated to an anteroposterior view by placing the arm in external rotation

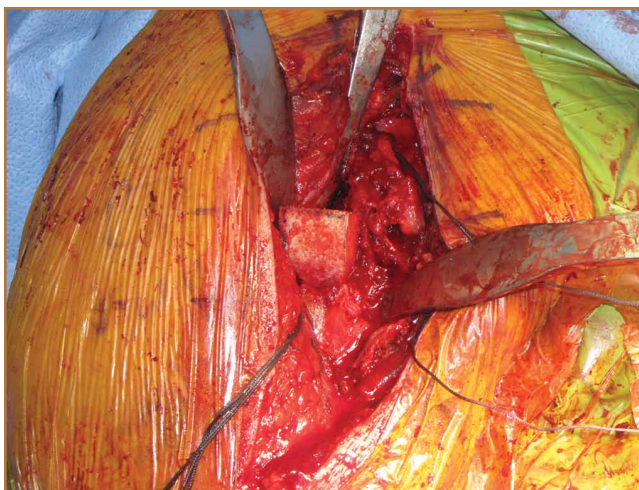

Figure 6. Allograft is impacted into intramedullary canal and into place.

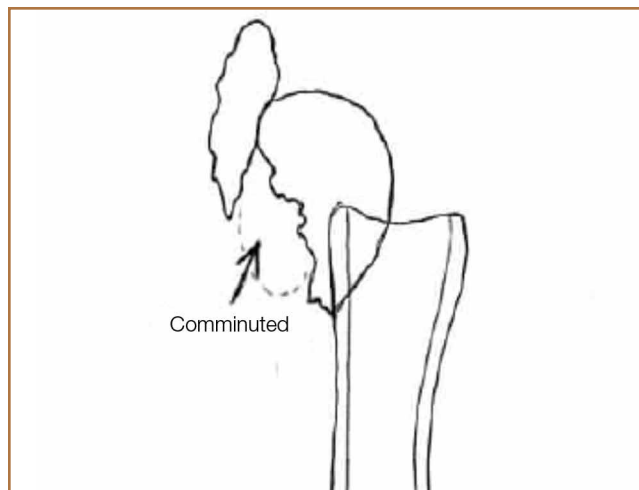


Figure 7. Sketch of anatomy of proximal humerus fracture shows metaphysis bone loss caused by comminution and impaction.

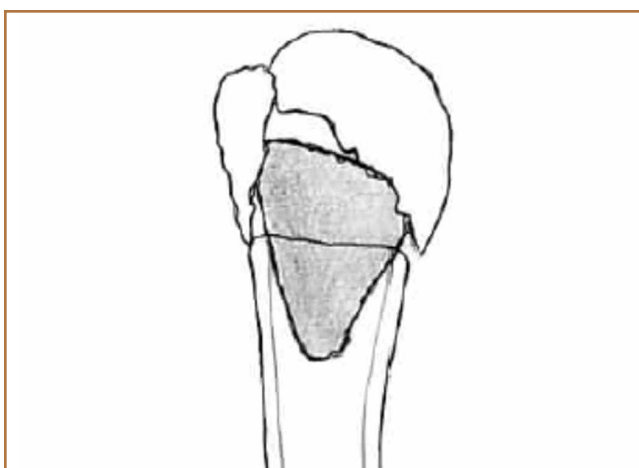


Figure 8. Sketch shows impaction of allograft femoral head (shaded segment) into medullary canal with greater tuberosity and humeral head fragment reduced.

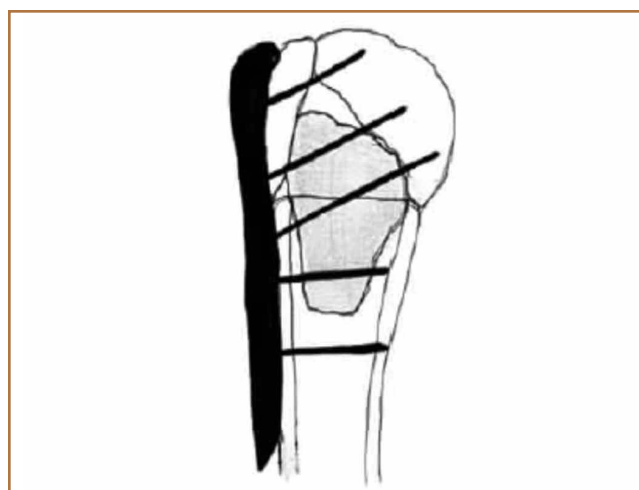


Figure 9. Sketch shows final construct with lateral plate and screws placed.

and neutral flexion and is then abducted and internally rotated to recreate a lateral view to perform final verification of the position of the plate on orthogonal images. If the surgeon is satisfied with the position of the plate, another nonlocking screw is placed distally, and then the proximal holes are used to place locking screws as needed. If the surgeon is not satisfied, the 2 proximal screws can be removed and the plate repositioned.

After each screw is placed, fluoroscopy is used to ensure there has been no breach of the articular surface. The number of proximal screws placed depends on fracture configuration and surgeon preference.

The sutures through the rotator cuff are then fixed to the plate, securing the tuberosities. Final intraoperative radiographs are used to confirm reduction, alignment, and final position of hardware (Figure 10). After copious irrigation, a surgical drain is placed as needed, and the wound is closed in layered fashion. Three years after surgery, follow-up ex-

amination revealed no radiographic change in alignment, no necrosis, and no varus collapse (Figure 11), and the patient was pain-free during activities.

Discussion

Surgical treatment of comminuted proximal humerus fractures usually consists of some type of plate fixation with screw fixation of the shaft, screws or smooth pegs to support the chondral surfaces, and screw fixation or suture cerclage of the tuberosities.

Fixed-angle locking-plate-and-screw constructs increased the biomechanical stability and pullout strength of proximal humerus plates.^{3,4} Nevertheless, avascular necrosis, malunion, and nonunion are still known complications of proximal humerus fractures, especially those with comminution, with up to 14% of patients still experiencing loss of fixation.⁵

For this reason, several authors have proposed using allograft bone and/or augmentation with calcium-containing cement to supplement fixation and provide an endosteal form of support for the head and tuberosities to decrease the risk for varus collapse. Osteobiologics (eg, calcium phosphate or sulfate cement) have been shown to decrease the risk for loss of reduction of proximal humerus fractures and decrease the risk for intra-articular screw penetration.^{6,7} Many calcium phosphate cements are commercially available. Cost and availability are 2 reasons that these supplements are not more widely used. Cancellous chips have also been used to aid in the reduction of proximal humerus fractures.⁸ No randomized study has been conducted to show a clinical advantage of this technique, though retrospective studies have shown that it is not as advantageous as using calcium phosphate cement with respect to loss of reduction or screw penetration.⁶ Certainly, cancellous chips are easily available in most hospitals and are less expensive than some alternatives. A recent review of these techniques in osteoporotic proximal humerus fractures found no clear indication for using one of these supplements over another.⁹

However, some fracture patterns require a structural graft to reduce the tuberosities and head component. Although described more than 30 years ago as a treatment for nonunions with an intramedullary “peg” of iliac crest graft,¹⁰ the graft most commonly reported today is allograft fibula.¹¹⁻¹⁵ This technique consists of preparing the humeral shaft and often the fractured head segment with reaming to create a channel to receive the graft. Even with use of a small fibula, it is often time-consuming to use a saw, rasp, or burr to size the fibular segment to fit the medullary canal of the humerus. Once in place, the graft provides a strut on which the head fragment can be reduced and around which the tuberosities can be reduced. Although this technique is successful clinically and is biomechanically superior to plate-only constructs,^{16,17} concerns remain.

One such concern is keeping this graft in routine supply at most hospitals. Supply and pricing from vendors can differ significantly between hospitals, and a surgeon may need to request grafts in advance, which makes their use nonviable in a trauma case. Certain grafts are often kept in routine supply based on their overall utilization. At our institution, allograft femoral heads meet this criterion and are routinely stocked.

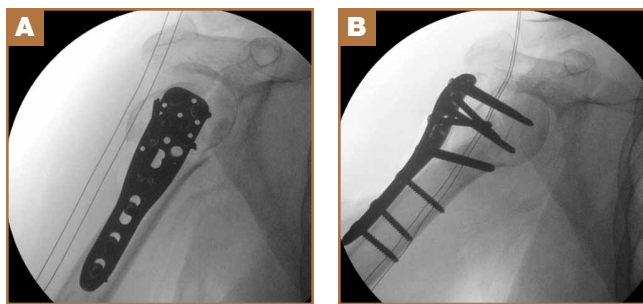


Figure 10. Intraoperative fluoroscopy shows alignment in (A) lateral plane and (B) coronal plane.

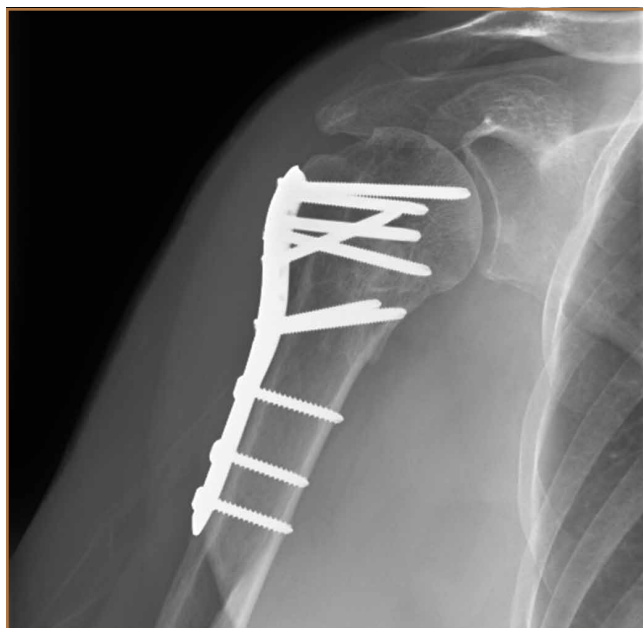

Figure 11. Anteroposterior radiograph 3.5 years after surgery shows graft incorporation and fracture union with no signs of hardware failure, avascular necrosis, or varus collapse.

Of more importance are the ramifications of these procedures for future revision surgeries. The need for arthroplasty revision is common after ORIF of a proximal humerus fracture.¹⁸

Arthroplasty revision is an already challenging procedure that becomes more complex with the need to remove 6 to 8 cm of ingrown endosteal bone from a shell of outer osteoporotic cortical bone. Our experience with these complex revisions provided the impetus to search for an alternate graft type that still provides a strut for reducing the head and tuberosities but limits the amount of endosteal bone that would need to be removed in arthroplasty revision in order to place a stemmed component into the humeral canal.

Some currently available arthroplasty fracture systems modify the previous anatomy of the stem to provide a more anatomical platform to reduce the tuberosities to a broader metaphyseal construct that incorporates bone grafting to assist with healing.

Because of these concerns and factors, we adapted our technique to create an individual-specific pedestal with allograft femoral head that can be anatomically matched to each patient. This provides a strut to reduce the head and tuberosity fragments but still limits the amount of allograft bone needed to seat into the existing canal. The geometry of the allograft can also be customized to the fracture, with most 3- and 4-part fractures needing a trapezoidal strut that resembles the metaphyseal portion of a fracture-specific shoulder arthroplasty implant.

We have used this technique for comminuted 3- and 4-part fractures of the proximal humerus in 14 cases with at least 2-year follow-up and in several more cases that have not reached 2-year follow-up. All cases have gone on to radiographic union; none have had to be revised either with revision ORIF or to an arthroplasty. Formal measurements of final postoperative range of motion have not been tabulated in all cases, as some cases have been lost to follow-up after radiographic union was achieved. Medium- and long-term results are not yet available, but no short-term complications have been noted.

Disadvantages of this technique are that, while an individualized graft is created, proper shaping still takes time, and a moderate amount of the femoral head is not used. However, we have found that, if a graft is inadvertently undersized, there is still ample femoral head remaining to create another sized graft. Other disadvantages are the added cost and the (rare) risk of disease transmission, which come with use of any allograft, but the technique is used instead of another type of allograft, so these disadvantages are largely equivalent. At our hospital, differences in cost and availability between femoral head or fibular allografts are negligible.

This procedure, which is easily performed in a short amount of time, allows a stable base of bone graft to be used as an aid in the anatomical reduction of proximal humerus fractures, without the need for reaming and preparation of the medullary canal and without further increasing the difficulty associated with a future revision procedure.

MAJ Parada, MD, is Chief, Shoulder Surgery, and Associate Program Director, Orthopaedic Residency, Dwight D. Eisenhower Army

Medical Center, Fort Gordon, Georgia; and Assistant Professor of Surgery, Uniformed Services University of the Health Sciences, Bethesda, Maryland. Dr. Makani is Fellow in Sports Medicine and Clinical Fellow in Orthopaedic Surgery, Harvard Medical School, Massachusetts General Hospital, Boston, Massachusetts. Ms. Stadecker is Research Assistant, Brigham and Women's Hospital, Boston, Massachusetts. Dr. Warner is Chief of Massachusetts General Hospital Shoulder Service and Professor of Orthopaedic Surgery, Harvard Medical School, Massachusetts General Hospital, Boston, Massachusetts.

Acknowledgment: We thank Lauren E. Burton, BS, for her medical illustrations.

Address correspondence to: MAJ Stephen A. Parada, MD, 300 W Hospital Rd, Fort Gordon, GA 30905 (tel, 706-787-6158; fax, 706-787-2901; email, stephen.a.parada@gmail.com).

Am J Orthop. 2015;44(10):471-475. Copyright Frontline Medical Communications Inc. 2015. All rights reserved.

References

- Barrett JA, Baron JA, Karagas MR, Beach ML. Fracture risk in the U.S. Medicare population. *J Clin Epidemiol.* 1999;52(3):243-249.
- Neer CS 2nd. Displaced proximal humeral fractures. I. Classification and evaluation. *J Bone Joint Surg Am.* 1970;52(6):1077-1089.
- Liew AS, Johnson JA, Patterson SD, King GJ, Chess DG. Effect of screw placement on fixation in the humeral head. *J Shoulder Elbow Surg.* 2000;9(5):423-426.
- Weinstein DM, Bratton DR, Ciccone WJ 2nd, Elias JJ. Locking plates improve torsional resistance in the stabilization of three-part proximal humeral fractures. *J Shoulder Elbow Surg.* 2006;15(2):239-243.
- Agudelo J, Schurmann M, Stahel P, et al. Analysis of efficacy and failure in proximal humerus fractures treated with locking plates. *J Orthop Trauma.* 2007;21(10):676-681.
- Egol KA, Sugi MT, Ong CC, Montero N, Davidovitch R, Zuckerman JD. Fracture site augmentation with calcium phosphate cement reduces screw penetration after open reduction-internal fixation of proximal humeral fractures. *J Shoulder Elbow Surg.* 2012;21(6):741-748.
- Gratl G, Knobe M, Stoffel M, Prescher A, Dirrachs T, Pape HC. Biomechanical evaluation of locking plate fixation of proximal humeral fractures augmented with calcium phosphate cement. *J Orthop Trauma.* 2013;27(7):399-404.
- Ong CC, Kwon YW, Walsh M, Davidovitch R, Zuckerman JD, Egol KA. Outcomes of open reduction and internal fixation of proximal humerus fractures managed with locking plates. *Am J Orthop.* 2012;41(9):407-412.
- Namdari S, Voleti PB, Mehta S. Evaluation of the osteoporotic proximal humeral fracture and strategies for structural augmentation during surgical treatment. *J Shoulder Elbow Surg.* 2012;21(12):1787-1795.
- Scheck M. Surgical treatment of nonunions of the surgical neck of the humerus. *Clin Orthop Relat Res.* 1982;(167):255-259.
- Hettrich CM, Neviasser A, Beamer BS, Paul O, Helfet DL, Lorich DG. Locked plating of the proximal humerus using an endosteal implant. *J Orthop Trauma.* 2012;26(4):212-215.
- Neviasser AS, Hettrich CM, Beamer BS, Dines JS, Lorich DG. Endosteal strut augment reduces complications associated with proximal humeral locking plates. *Clin Orthop Relat Res.* 2011;469(12):3300-3306.
- Gardner MJ, Boraiah S, Helfet DL, Lorich DG. Indirect medial reduction and strut support of proximal humerus fractures using an endosteal implant. *J Orthop Trauma.* 2008;22(3):195-200.
- Matassi F, Angeloni R, Carulli C, et al. Locking plate and fibular allograft augmentation in unstable fractures of proximal humerus. *Injury.* 2012;43(11):1939-1942.
- Little MT, Berkes MB, Schottel PC, et al. The impact of preoperative coronal plane deformity on proximal humerus fixation with endosteal augmentation. *J Orthop Trauma.* 2014;28(6):338-347.
- Mathison C, Chaudhary R, Beaupre L, Reynolds M, Adeeb S, Bouliane M. Biomechanical analysis of proximal humeral fixation using locking plate fixation with an intramedullary fibular allograft. *Clin Biomech.* 2010;25(7):642-646.
- Chow RM, Begum F, Beaupre LA, Carey JP, Adeeb S, Bouliane MJ. Proximal humeral fracture fixation: locking plate construct +/- intramedullary fibular allograft. *J Shoulder Elbow Surg.* 2012;21(7):894-901.
- Jost B, Spross C, Grehn H, Gerber C. Locking plate fixation of fractures of the proximal humerus: analysis of complications, revision strategies and outcome. *J Shoulder Elbow Surg.* 2013;22(4):542-549.