

Magnetic Resonance Imaging of Complications of Anterior Cruciate Ligament Reconstruction

Etan Dayan, MD, Alex Maderazo, MD, MBA, and Darren Fitzpatrick, MD

Abstract

The incidence of anterior cruciate ligament reconstruction (ACL-R) has increased in recent years. ACL-R plays an important role in the prevention of secondary osteoarthritis from resultant joint instability. Magnetic resonance imaging is the preferred modality in the evaluation of ACL-R complications. Complications after ACL-R may be broadly characterized as those resulting in decreased range of motion (arthrofibrosis, impingement) and resulting in increased laxity (graft disruption). Other miscellaneous complications that do not fall into these categories will also be discussed in this article.

Magnetic resonance imaging (MRI) is the preferred modality in the evaluation of complications of anterior cruciate ligament reconstruction (ACL-R).¹⁻³ ACL-R complications may be broadly characterized as those resulting in decreased range of motion (ROM), eg, arthrofibrosis and impingement, and those resulting in increased laxity, ie, graft disruption.⁴ Short tau inversion recovery (STIR) sequences best minimize artifact related to field inhomogeneity in the presence of metal-containing fixation devices. Patients with contraindications to MRI may undergo high-resolution computed tomographic arthrography of the knee for evaluation of postoperative graft abnormalities.¹

Arthrofibrosis refers to focal or diffuse synovial scar tissue, which may limit ROM. Preoperative irritation, preoperative limited ROM, and reconstruction within 4 weeks of trauma may all play a role in the development of arthrofibrosis.^{5,6} The focal form, *cyclops lesion*, named for its arthroscopic appearance, has been reported in 1% to 10% of patients with ACL-R.¹ On MRI, focal arthrofibrosis may be seen as a focal or diffuse intermediate signal lesion in the anterior intercondylar notch extending linearly along the intercondylar roof¹ (Figure 1).

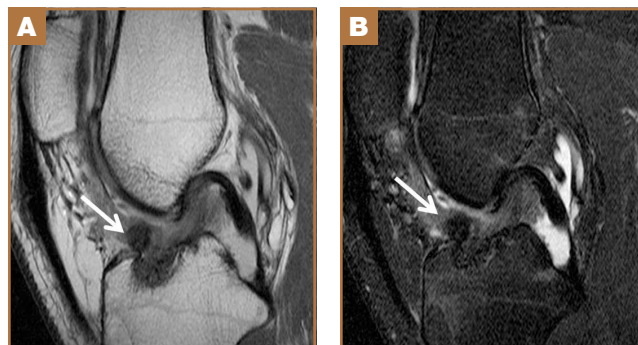
MRI can be used to accurately determine the position of the femoral and tibial tunnels. Correct femoral tunnel position results in isometry of the graft during full ROM of the knee. Graft impingement can occur when the tibial tunnel is placed

too far anteriorly such that the graft contacts the roof of the intercondylar notch before the knee is able to fully extend.⁷ A tibial tunnel placed anterior to the intersection of the Blumensaat line and the tibia is at higher risk for impingement.^{1,4} Impingement may be accompanied by signal change in the graft on intermediate-weighted and fluid-sensitive sequences. The signal abnormality is usually focal and persists longer than the expected signal changes related to revascularization of immature grafts within the first year (Figure 2). If left untreated, impingement may progress to graft rupture.⁴

Complete graft rupture is diagnosed on the basis of discontinuity of the graft fibers. MRI findings include fluid-filled defect or absence of intact graft fibers. Other reliable signs include large joint effusion, anterior tibial translation, pivot-shift-type marrow edema pattern, and horizontal orientation, laxity, or resorption of the graft fibers.^{1,8,9} The diagnosis of partial graft rupture may be challenging, as there are several other causes of increased graft signal, including revascularization (within 12 months after procedure), signal heterogeneity between individual bundles of hamstring grafts, and focal signal changes related to impingement (Figures 3, 4).

Fluid within the tunnels is a normal finding after surgery and typically resolves within the first 18 months.¹ Cyst formation within the tibial tunnel is an uncommon complication

Figure 1. (A) Intermediate-weighted and (B) sagittal T2-weighted fat-saturated magnetic resonance imaging shows ovoid focus of intermediate signal within anterior aspect of intercondylar notch representing focal arthrofibrosis (white arrow).



Authors' Disclosure Statement: The authors report no actual or potential conflict of interest in relation to this article.

of ACL-R and may be incidental to or present with clinical symptoms caused by extension into the pretibial soft tissues or expansion of the tunnel (Figure 5). Communication of cyst with joint space is important, as a noncommunicating cyst

requires simple excision without need for bone grafting⁷

Hardware-related complications (eg, loosening of fixation devices) are uncommon but may require revision surgery (Figure 6). Septic arthritis after ACL-R has a cumulative incidence

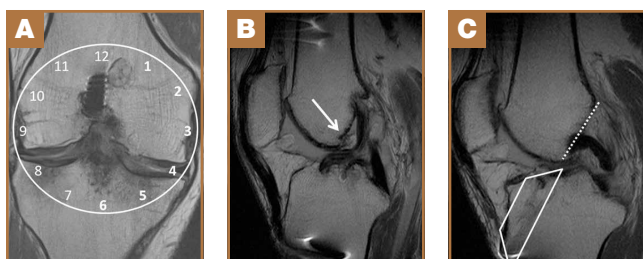


Figure 2. (A) Intermediate-weighted coronal magnetic resonance imaging (MRI) shows vertical (“over-the-top”) placement of femoral tunnel at 12 o’clock. This positioning results in loss of isometry of graft through full range of knee motion. Ideally, femoral tunnel is placed between 1 and 2 o’clock (left knee) or between 10 and 11 o’clock (right knee). (B) Sagittal intermediate-weighted MRI shows large osteophyte (white arrow) projecting posteriorly from inferior intercondylar roof bows and displaces the graft—compatible with graft impingement. (C) Sagittal intermediate-weighted MRI (same patient) shows tibial tunnel (white trapezoid) slightly anterior to Blumensaat line (dotted line). Correct tibial tunnel placement, slightly posterior to intersection of Blumensaat line and tibial cortex, avoids graft impingement.

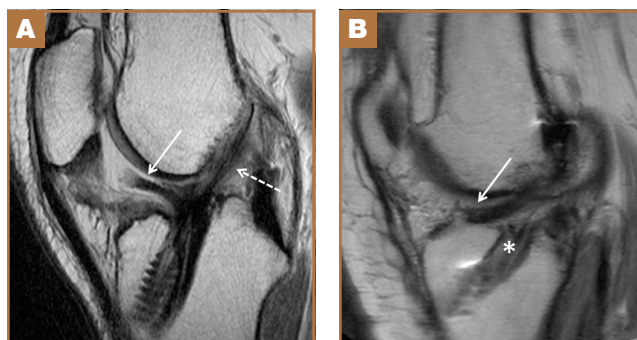


Figure 4. (A) Sagittal intermediate-weighted magnetic resonance imaging (MRI) shows partial tear of double-bundle anterior cruciate ligament graft. Anterior-bundle fibers are proximally avulsed and displaced into anterior aspect of intercondylar notch (solid arrow); posterior-bundle fibers remain in continuity (dashed arrow). (B) Sagittal intermediate-weighted MRI (different patient) shows graft dislodged from tibial tunnel (asterisk) and displaced into joint (arrow).

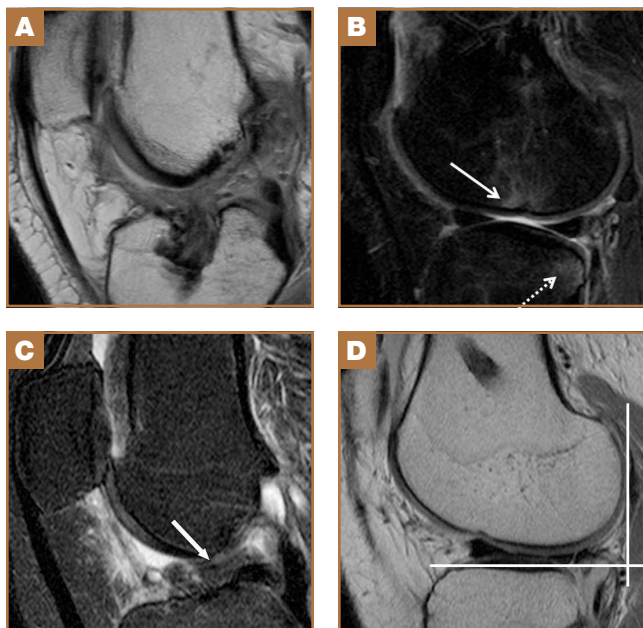


Figure 3. (A) Sagittal intermediate-weighted magnetic resonance imaging (MRI) shows complete rupture of anterior cruciate ligament (ACL) graft with no discernible intact fibers remaining. (B) Corresponding sagittal fluid-sensitive MRI (same patient) shows anterior lateral femoral condylar impaction fracture (solid arrow) and posterior tibial plateau subchondral contusion (dotted arrow), consistent with recent pivot-shift injury. (C) Sagittal fluid-sensitive and (D) intermediate-weighted MRI shows chronic complete tear of ACL graft with distal stump (white arrow) horizontally oriented within intercondylar notch (in C). Note associated anterior tibial translation (in D).

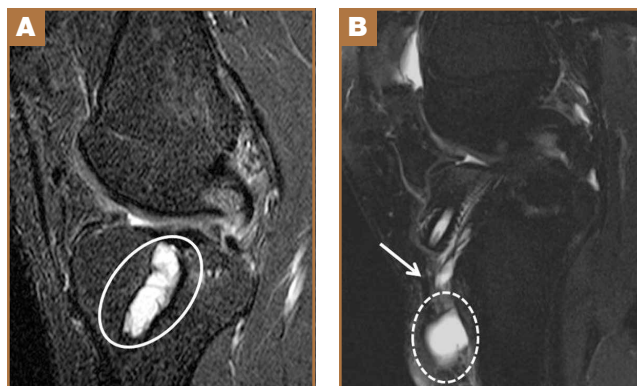


Figure 5. (A) Sagittal fluid-sensitive magnetic resonance imaging (MRI) shows high-signal cysts within tibial tunnel (circle). (B) Sagittal fluid-sensitive MRI (different patient) shows cystic structure anterior to tibial cortex (dashed circle) communicating with intraosseous tibial tunnel cyst (arrow), consistent with ganglion formation.

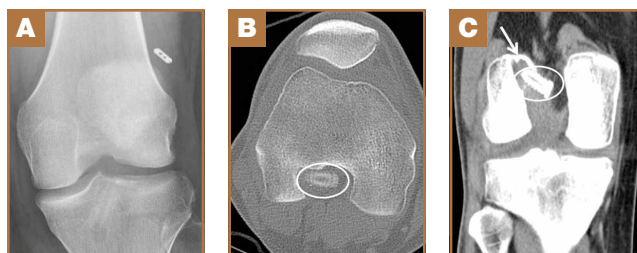


Figure 6. (A) Frontal radiograph shows cortical suspension fixation displaced from lateral femoral cortex. (B) Axial and (C) coronal computed tomography shows dislodged interference screw (circles) and tunnel widening (arrow), reflective of loosening.

of 0.1% to 0.9% and may be difficult to diagnose clinically because of the lack of classic symptoms of a septic joint.¹ Diagnosis requires joint aspiration.

MRI is reliably and accurately used to assess ACL-R complications. The clinical history helps in stratifying complications that result in decreased ROM or increased laxity.

Dr. Dayan is Resident, Dr. Maderazo is Section Chief of Musculoskeletal Imaging, and Dr. Fitzpatrick is Director of Musculoskeletal Procedures, Department of Radiology, Icahn School of Medicine at Mount Sinai, New York, New York.

Address correspondence to: Darren Fitzpatrick, MD, Department of Radiology, Icahn School of Medicine at Mount Sinai, 1 Gustave Levy Pl, New York, NY 10029 (tel, 212-241-6681; email, darren.fitzpatrick.md@gmail.com).

Am J Orthop. 2015;44(12):569-571. Copyright Frontline Medical Communications Inc. 2015. All rights reserved.

References

1. Bencardino JT, Beltran J, Feldman MI, Rose DJ. MR imaging of complica-

- tions of anterior cruciate ligament graft reconstruction. *Radiographics.* 2009;29(7):2115-2126.
2. Recht MP, Kramer J. MR imaging of the postoperative knee: a pictorial essay. *Radiographics.* 2002;22(4):765-774.
3. Papakonstantinou O, Chung CB, Chanchairujira K, Resnick DL. Complications of anterior cruciate ligament reconstruction: MR imaging. *Eur Radiol.* 2003;13(5):1106-1117.
4. Meyers AB, Haims AH, Menn K, Moukaddam H. Imaging of anterior cruciate ligament repair and its complications. *AJR Am J Roentgenol.* 2010;194(2):476-484.
5. Kwok CS, Harrison T, Servant C. The optimal timing for anterior cruciate ligament reconstruction with respect to the risk of postoperative stiffness. *Arthroscopy.* 2013;29(3):556-565.
6. Mayr HO, Weig TG, Plitz W. Arthrofibrosis following ACL reconstruction—reasons and outcome. *Arch Orthop Trauma Surg.* 2004;124(8):518-522.
7. Ghazikhanian V, Beltran J, Nikac V, Feldman M, Bencardino JT. Tibial tunnel and pretibial cysts following ACL graft reconstruction: MR imaging diagnosis. *Skeletal Radiol.* 2012;41(11):1375-1379.
8. Collins MS, Unruh KP, Bond JR, Mandrekar JN. Magnetic resonance imaging of surgically confirmed anterior cruciate ligament graft disruption. *Skeletal Radiol.* 2008;37(3):233-243.
9. Saupé N, White LM, Chiavaras MM, et al. Anterior cruciate ligament reconstruction grafts: MR imaging features at long-term follow-up—correlation with functional and clinical evaluation. *Radiology.* 2008;249(2):581-590.

This paper will be judged for the Resident Writer's Award.

2015 Resident Writer's Award

The 2015 Resident Writer's Award competition is sponsored by DePuy Synthes Institute. Orthopedic residents are invited to submit original studies, review papers, or case reports for publication. Papers published in 2015 will be judged by The American Journal of Orthopedics Editorial Board. Honoraria will be presented to the winners at the 2016 AAOS annual meeting.

\$1,500 for the First-Place Award
\$1,000 for the Second-Place Award
\$500 for the Third-Place Award

To qualify for consideration, papers must have the resident as the first-listed author and must be accepted through the journal's standard blinded-review process.

Papers submitted in 2015 but not published until 2016 will automatically qualify for the 2016 competition.

Manuscripts should be prepared according to our Information for Authors and submitted via our online submission system, Editorial Manager®, at www.editorialmanager.com/AmJOrthop.

Supported by

DePuy Synthes
Institute
advancing education and research