

Total Knee Arthroplasty in Hemophilic Arthropathy

E. Carlos Rodríguez-Merchán, MD, PhD

Abstract

Hemophilic arthropathy of the knee is common among patients with hemophilia and is a major cause of severe joint pain and functional disability requiring total knee arthroplasty (TKA).

We evaluated TKA outcomes and complications with a special focus on prosthetic survival and infection. We retrospectively reviewed the medical records of 74 patients with chronic hemophilic arthropathy of the knee treated with TKA (N = 88) over a 13-year period. The same type of implant was used in all cases. Fourteen patients had 2-stage bilateral TKAs.

Mean patient age was 38.2 years (range, 24-73 years). Fourteen patients were positive for human immunodeficiency virus, and 32 for hepatitis C virus. Mean follow-up was 8 years (range, 1-13 years). The prosthetic survival rate with implant removal for any reason regarded as final endpoint was 92%. Causes of TKA failure were prosthetic joint infection (6.8%) and aseptic loosening (2.2%).

Clinical outcomes of the primary TKAs in this series were good prosthetic survival and excellent pain relief. TKA infection continues to be a major concern for patients with hemophilia relative to patients without hemophilia.

Chronic hemophilic arthropathy, a well-known complication of hemophilia, develops as a long-term consequence of recurrent joint bleeds resulting in synovial hypertrophy (chronic proliferative synovitis) and joint cartilage destruction. Hemophilic arthropathy mostly affects the knees, ankles, and elbows and causes chronic joint pain and functional impairment in relatively young patients who have not received adequate primary prophylactic replacement therapy with factor concentrates from early childhood.¹⁻³

In the late stages of hemophilic arthropathy of the knee, total knee arthroplasty (TKA) provides dramatic joint pain relief, improves knee functional status, and reduces rebleeding into the joint.⁴⁻⁸ TKA performed on a patient with hemophilia was first reported in the mid-1970s.^{9,10} In these cases,

the surgical procedure itself is often complicated by severe fibrosis developing in the joint soft tissues, flexion joint contracture, and poor quality of the joint bone structures. Even though TKA significantly reduces joint pain in patients with chronic hemophilic arthropathy, some authors have achieved only modest functional outcomes and experienced a high rate of complications (infection, prosthetic loosening).¹¹⁻¹³ Data on TKA outcomes are still scarce, and most studies have enrolled a limited number of patients.

We retrospectively evaluated the outcomes of 88 primary TKAs performed on patients with severe hemophilia at a single institution. Clinical outcomes and complications were assessed with a special focus on prosthetic survival and infection.

Patients and Methods

Ninety-one primary TKAs were performed in 77 patients with severe hemophilia A and B (factor VIII [FVIII] and factor IX plasma concentration, <1% each) between January 1, 1999, and December 31, 2011, and the medical records of all these patients were thoroughly reviewed in 2013. The cases of 3 patients who died shortly after surgery were excluded from analysis. Thus, 88 TKAs and 74 patients (74 males) were finally available for evaluation. Fourteen patients underwent bilateral TKAs but none concurrently. The patients provided written informed consent for print and electronic publication of their outcomes.

We recorded demographic data, type and severity of hemophilia, human immunodeficiency virus (HIV) status, hepatitis C virus (HCV) status, and Knee Society Scale (KSS) scores.¹⁴ KSS scores include Knee score (pain, range of motion [ROM], stability) and Function score (walking, stairs), both of which range from 0 (normal knee) to 100 (most affected knee). Prosthetic infection was classified (Segawa and colleagues¹⁵) as early or late, depending on timing of symptom onset (4 weeks after replacement surgery was the threshold used).

Patients received an intravenous bolus infusion of the deficient factor concentrate followed by continuous infusion to reach a plasma factor level of 100% just before surgery and during the first 7 postoperative days and 50% over the next 7 days (Table 1). Patients with a circulating inhibitor (3 overall) received bypassing agents FEIBA (FVIII inhibitor bypassing agent) or rFVIIa (recombinant factor VII activated) (Table 2). Patients were not given any antifibrinolytic treatment or thromboprophylaxis.

Author's Disclosure Statement: The author reports no actual or potential conflict of interest in relation to this article.

Surgery was performed in a standard surgical room. Patients were placed on the operating table in decubitus supinus position. A parapatellar medial incision was made on a bloodless surgical field (achieved with tourniquet ischemia). The prosthesis model used was always the cemented (gentamicin bone cement) NexGen (Zimmer). Patellar resurfacing was done in all cases (Figures 1A–1D). All TKAs were performed by Dr.

Table 1. Plasma Factor Trough Levels and Duration of Administration in Patients With Hemophilia A and B Without Inhibitors Undergoing Total Knee Arthroplasty

Hemophilia Type	Level (IU dL ⁻¹)	Duration, d
Hemophilia A		
Preoperative	80-100	—
Postoperative	60-80	1-3
	40-60	4-6
	30-50	7-14
Hemophilia B		
Preoperative	60-80	—
Postoperative	40-60	1-3
	30-50	4-6
	20-40	7-14

Table 2. Dosage and Duration of Factor VIII Inhibitor Bypassing Agent (FEIBA) and Recombinant FVII Activated (rFVIIa) for Total Knee Arthroplasty

Bypassing Agent	Period		
	Preoperative	Days 1–5	Days 6–14
FEIBA	75-100 U/kg	75-100 U/kg q8-12h	75-100 U/kg q12h
rFVIIa	120 µg/kg	Day 1: 90-120 µg/kg q2 Day 2: q3h Days 3-5: q4h	90-120 µg/kg q6h

Rodríguez-Merchán. Intravenous antibiotic prophylaxis was administered at anesthetic induction and during the first 48 hours after surgery (3 further doses). Active exercises were started on postoperative day 1. Joint load aided with 2 crutches was allowed starting on postoperative day 2.

Mean patient age was 38.2 years (range, 24-73 years). Of the 74 patients, 55 had a diagnosis of severe hemophilia A, and 19 had a diagnosis of severe hemophilia B. During the follow-up period, 23 patients died (mean time, 6.4 years; range, 4-9 years). Causes of death were acquired immune deficiency syndrome (AIDS), liver cirrhosis, and intracranial bleeding. Mean follow-up for the full series of patients was 8 years (range, 1-13 years).

Descriptive statistical analysis was performed with SPSS Windows Version 18.0. Prosthetic failure was regarded as implant removal for any reason. Student t test was used to compare continuous variables, and either χ^2 test or Fisher exact test was used to compare categorical variables. $P < .05$ (2-sided) was considered significant.

Results

Prosthetic survival rates with implant removal for any reason regarded as final endpoint was 92%. Causes of failure were prosthetic infection (6 cases, 6.8%) and loosening (2 cases, 2.2%). Of the 6 prosthetic infections, 5 were regarded as late and 1 as early. Late infections were successfully sorted by performing 2-stage revision TKA with the Constrained Condylar Knee (Zimmer). Acute infections were managed by open joint débridement and polyethylene exchange. Both cases of aseptic loosening of the TKA were successfully managed with 1-stage revision TKA using the same implant model (Figures 2A–2D).

Mean KSS Knee score improved from 79 before surgery to 36 after surgery, and mean KSS Function score improved from 63 to 33. KSS Pain score, which is included in the Knee score, 0 (no pain) to 50 (most severe pain), improved from 47 to 8.

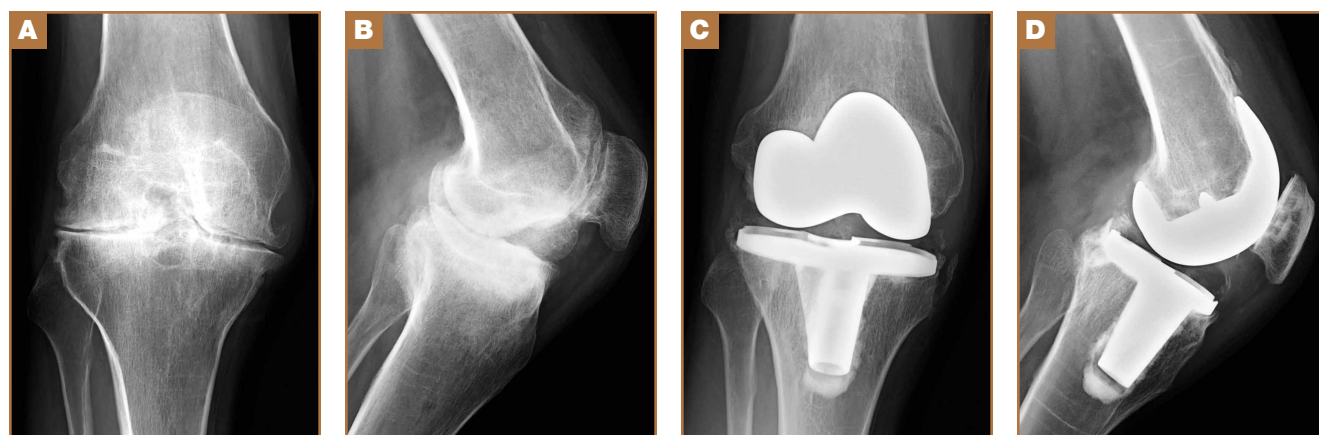


Figure 1. Severe hemophilic arthropathy in 39-year-old hemophilic patient after successful total knee arthroplasty (NexGen, Zimmer) with patellar resurfacing. (A) Preoperative anteroposterior (AP) radiograph, (B) preoperative lateral radiograph, (C) AP radiograph of implanted prosthesis, and (D) lateral radiograph of implanted prosthesis.

Patients receiving inhibitors and patients who were HIV- or HCV-positive did not have poorer outcomes relative to those of patients not receiving inhibitors and patients who were HIV- or HCV-negative. Patients with liver cirrhosis had a lower prosthetic survival rate and lower Knee scores.

Discussion

The prosthetic survival rate found in this study compares well with other reported rates for patients with hemophilia and other bleeding disorders. However, evidence regarding long-term prosthesis survival in TKAs performed for patients with hemophilia is limited. Table 3 summarizes the main reported series of patients with hemophilia with 10-year prosthetic survival rates, number of TKAs performed, and mean follow-up period; in all these series, implant removal for any reason was regarded as the final endpoint.^{5-8,16,17} Mean follow-up in our study was 8 years. Clinical outcomes of TKA in patients with severe hemophilia and related disorders are expected to be inferior to those achieved in patients without a bleeding condition. The overall 10-year prosthetic survival rate for cemented TKA implants, as reported by the Norwegian Arthroplasty Register, was on the order of 93%.¹⁸ Mean age of our patients at time of surgery was only 38.2 years. TKAs performed in younger patients without a bleeding disorder have been associated with shorter implant survival times relative to those of elderly patients.¹⁹ Thus, Diduch and colleagues²⁰ reported a prosthetic survival rate of 87% at 18 years in 108 TKAs performed on patients under age 55 years. Lonner and colleagues²¹ reported a better implant survival rate (90% at 8 years) in a series of patients under age 40 years (32 TKAs). In a study by Duffy and colleagues,²² the implant survival rate was 85% at 15 years in patients under age 55 years (74 TKAs). The results from our retrospective case assessment are quite similar to the overall prosthetic survival rates reported for TKAs performed on patients without hemophilia.

Rates of periprosthetic infection after primary TKA in patients with hemophilia and other bleeding conditions are much higher (up to 11%), with a mean infection rate of 6.2% (range, 1% to 11%), consistent with the rate found in our series of patients (6.8%)^{7,16,17,23,24} (Table 4). This rate is much higher than that reported after primary TKA in patients without he-

Table 3. Long-Term Prosthetic Survival Rates for Total Knee Arthroplasties (TKAs) Performed in Patients With Hemophilia

Study	10-Year Survival Rate, %	TKAs, N	Mean Follow-Up, y
Silva & Luck ⁵	83	90	7.8
Wang et al ⁶	83	40	11.8
Chevalier et al ⁷	88	72	7.8
Zingg et al ⁸	86	43	8.6
Goddard et al ¹⁶	89	70	9.2
Westberg et al ¹⁷	92	107	11.2

Table 4. Infection Rates for Total Knee Arthroplasties (TKAs) Performed in Patients With Hemophilia, 2008–2015

Study	Year	TKAs, N	Infection Rate, %
Chiang et al ²³	2008	35	11.4
Solimeno et al ²⁴	2009	116	8
Goddard et al ¹⁶	2010	70	1.4
Chevalier et al ⁷	2013	72	4.1
Westberg et al ¹⁷	2014	107	6.5
Present report	2015	88	6.8

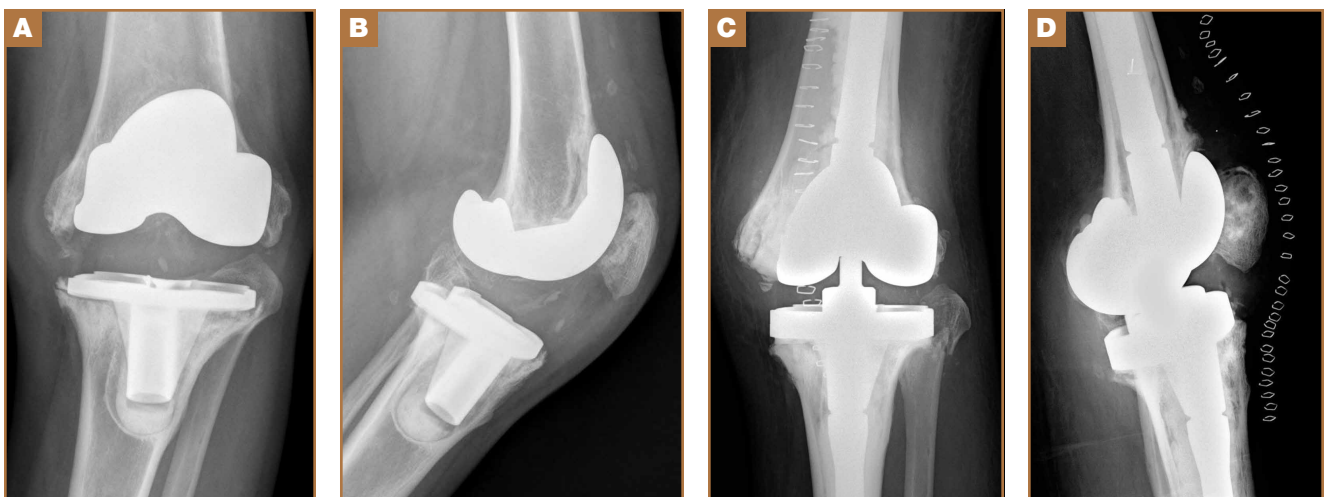


Figure 2. Aseptic prosthetic loosening in hemophilic patient who underwent total knee arthroplasty (TKA) (NexGen, Zimmer) with patellar resurfacing 13 years earlier. One-stage revision TKA (Constrained Condylar Knee, Zimmer): (A) Preoperative anteroposterior (AP) radiograph, (B) preoperative lateral radiograph, (C) AP radiograph after revision surgery, and (D) lateral radiograph of revision prosthesis.

mophilia but is similar to some rates reported for patients with hemophilia. In our experience, most periprosthetic infections (5/6) were sorted as late.

Late infection is a major concern after TKA in patients with hemophilia, and various factors have been hypothesized as contributing to the high prevalence. An important factor is the high rate of HIV-positive patients among patients with hemophilia—which acts as a strong predisposing factor because of the often low CD4 counts and associated immune deficiency,²⁵ but different reports have provided conflicting results in this respect.^{5,6,12} We found no relationship between HIV status and risk for periprosthetic infection, but conclusions are limited by the low number of HIV-positive patients in our series (14/74, 18.9%). Our patients' late periprosthetic infections were diagnosed several years after TKA, suggesting hematogenous spread of infection. Most of these patients either were on regular prophylactic factor infusions or were being treated on demand, which might entail a risk for contamination of infusions by skin bacteria from the puncture site. Therefore, having an aseptic technique for administering coagulation factor concentrates is of paramount importance for patients with hemophilia and a knee implant.

Another important complication of TKA surgery is aseptic loosening of the prosthesis. Aseptic loosening occurred in 2.2% of our patients, but higher rates have been reported elsewhere.^{11,26} Rates of this complication increase over follow-up, and some authors have linked this complication to TKA polyethylene wear.²⁷ Development of a reactive and destructive bone–cement interface and microhemorrhages into such interface might be implicated in the higher rate of loosening observed among patients with hemophilia.²⁸

In the present study, preoperative and postoperative functional outcomes differed significantly. A modest postoperative total ROM of 69° to 79° has been reported by several authors.^{5,6} Postoperative ROM may vary—may be slightly increased, remain unchanged, or may even be reduced.^{4,23,26} Even though little improvement in total ROM is achieved after TKA, many authors have reported reduced flexion contracture and hence an easier gait. However, along with functional improvement, dramatic pain relief after TKA is perhaps the most remarkable aspect, and it has a strong effect on patient satisfaction after surgery.^{5,7,8,18,23}

Our study had 2 main limitations. First, it was a retrospective case series evaluation with the usual issues of potential inaccuracy of medical records and information bias. Second, the study did not include a control group.

Conclusion

The primary TKAs performed in our patients with hemophilia have had a good prosthetic survival rate. Even though such a result is slightly inferior to results in patients without hemophilia, our prosthetic survival rate is not significantly different from the rates reported in other, younger patient subsets. Late periprosthetic infections are a major concern, and taking precautions to avoid hematogenous spread of infections during factor concentrate infusions is strongly encouraged.

Dr. Rodríguez-Merchán is Consultant Orthopaedic Surgeon, Department of Orthopaedic Surgery, La Paz University Hospital-IdiPaz, Madrid, Spain.

Acknowledgments: For their important contributions, the author thanks hematologists V. Jiménez-Yuste, M.T. Álvarez-Román, and M. Martín-Salces; assistant surgeons P. Gómez-Cardero and A. Martínez-Lloreda; and physician H. De la Corte-Rodríguez of the Department of Physical Medicine and Rehabilitation, La Paz University Hospital-IdiPaz.

Address correspondence to: E. Carlos Rodríguez-Merchán, MD, PhD, Department of Orthopaedic Surgery, La Paz University Hospital-IdiPaz, Paseo de la Castellana 261, 28049 Madrid, Spain (tel, 34-606712724; fax, 34-91-5712871; email, ecrmerchan@gmx.es).

Am J Orthop. 2015;44(12):E503-E507. Copyright Frontline Medical Communications Inc. 2015. All rights reserved.

References

1. Arnold WD, Hilgartner MW. Hemophilic arthropathy. Current concepts of pathogenesis and management. *J Bone Joint Surg Am.* 1977;59(3):287-305.
2. Rodríguez-Merchán EC. Common orthopaedic problems in haemophilia. *Haemophilia.* 1999;5(suppl 1):53-60.
3. Steen Carlsson K, Höjgård S, Glomstein A, et al. On-demand vs. prophylactic treatment for severe haemophilia in Norway and Sweden: differences in treatment characteristics and outcome. *Haemophilia.* 2003;9(5):555-566.
4. Teigland JC, Tjønnfjord GE, Evensen SA, Charania B. Knee arthroplasty in hemophilia. 5-12 year follow-up of 15 patients. *Acta Orthop Scand.* 1993;64(2):153-156.
5. Silva M, Luck JV Jr. Long-term results of primary total knee replacement in patients with hemophilia. *J Bone Joint Surg Am.* 2005;87(1):85-91.
6. Wang K, Street A, Dowrick A, Liew S. Clinical outcomes and patient satisfaction following total joint replacement in haemophilia—23-year experience in knees, hips and elbows. *Haemophilia.* 2012;18(1):86-93.
7. Chevalier Y, Dargaud Y, Lienhart A, Chamouard V, Negrier C. Seventy-two total knee arthroplasties performed in patients with haemophilia using continuous infusion. *Vox Sang.* 2013;104(2):135-143.
8. Zingg PO, Fucentese SF, Lutz W, Brand B, Mamisch N, Koch PP. Haemophilic knee arthropathy: long-term outcome after total knee replacement. *Knee Surg Sports Traumatol Arthrosc.* 2012;20(12):2465-2470.
9. Kjaersgaard-Andersen P, Christiansen SE, Ingerslev J, Sneppen O. Total knee arthroplasty in classic hemophilia. *Clin Orthop Relat Res.* 1990;(256):137-146.
10. Cohen I, Heim M, Martinowitz U, Chechick A. Orthopaedic outcome of total knee replacement in haemophilia A. *Haemophilia.* 2000;6(2):104-109.
11. Fehily M, Fleming P, O'Shea E, Smith O, Smyth H. Total knee arthroplasty in patients with severe haemophilia. *Int Orthop.* 2002;26(2):89-91.
12. Legroux-Gérot I, Strouk G, Parquet A, Goodemand J, Gougeon F, Duquesnoy B. Total knee arthroplasty in hemophilic arthropathy. *Joint Bone Spine.* 2003;70(1):22-32.
13. Sheth DS, Oldfield D, Ambrose C, Clyburn T. Total knee arthroplasty in hemophilic arthropathy. *J Arthroplasty.* 2004;19(1):56-60.
14. Insall JN, Dorr LD, Scott RD, Scott WN. Rationale of the Knee Society clinical rating system. *Clin Orthop Relat Res.* 1989;(248):13-14.
15. Segawa H, Tsukayama DT, Kyle RF, Becker DA, Gustilo RB. Infection after total knee arthroplasty. A retrospective study of the treatment of eighty-one infections. *J Bone Joint Surg Am.* 1999;81(10):1434-1445.
16. Goddard NJ, Mann HA, Lee CA. Total knee replacement in patients with end-stage haemophilic arthropathy. 25-year results. *J Bone Joint Surg Br.* 2010;92(8):1085-1089.
17. Westberg M, Paus AC, Holme PA, Tjønnfjord GE. Haemophilic arthropathy: long-term outcomes in 107 primary total knee arthroplasties. *Knee.* 2014;21(1):147-150.
18. Lygre SH, Espehaug B, Havelin LI, Volset SE, Furnes O. Failure of total knee arthroplasty with or without patella resurfacing. A study from the Norwegian Arthroplasty Register with 0-15 years of follow-up. *Acta Orthop.* 2011;82(3):282-292.
19. Post M, Telfer MC. Surgery in hemophilic patients. *J Bone Joint Surg Am.* 1975;57(8):1136-1145.
20. Diduch DR, Insall JN, Scott WN, Scuderi GR, Font-Rodríguez D. Total knee replacement in young, active patients. Long-term follow-up and functional outcome. *J Bone Joint Surg Am.* 1997;79(4):575-582.
21. Lonner JH, Hershman S, Mont M, Lotke PA. Total knee arthroplasty in

- patients 40 years of age and younger with osteoarthritis. *Clin Orthop Relat Res*. 2000;(380):85-90.
22. Duffy GP, Crowder AR, Trousdale RR, Berry DJ. Cemented total knee arthroplasty using a modern prosthesis in young patients with osteoarthritis. *J Arthroplasty*. 2007;22(6 suppl 2):67-70.
 23. Chiang CC, Chen PQ, Shen MC, Tsai W. Total knee arthroplasty for severe haemophilic arthropathy: long-term experience in Taiwan. *Haemophilia*. 2008;14(4):828-834.
 24. Solimeno LP, Mancuso ME, Pasta G, Santagostino E, Perfetto S, Mannucci PM. Factors influencing the long-term outcome of primary total knee replacement in haemophiliacs: a review of 116 procedures at a single institution. *Br J Haematol*. 2009;145(2):227-234.
 25. Jämsen E, Varonen M, Huhtala H, et al. Incidence of prosthetic joint infections after primary knee arthroplasty. *J Arthroplasty*. 2010;25(1):87-92.
 26. Ragni MV, Crossett LS, Herndon JH. Postoperative infection following orthopaedic surgery in human immunodeficiency virus-infected hemophiliacs with CD4 counts $\leq 200/\text{mm}^3$. *J Arthroplasty*. 1995;10(6):716-721.
 27. Hicks JL, Ribbans WJ, Buzzard B, et al. Infected joint replacements in HIV-positive patients with haemophilia. *J Bone Joint Surg Br*. 2001;83(7):1050-1054.
 28. Figgie MP, Goldberg VM, Figgie HE 3rd, Heiple KG, Sobel M. Total knee arthroplasty for the treatment of chronic hemophilic arthropathy. *Clin Orthop Relat Res*. 1989;(248):98-107.