

# Valgus Extension Overload in Baseball Players

Franklin E. Paulino, Diego C. Villacis, MD, and Christopher S. Ahmad, MD

## Abstract

Repetitive throwing, such as in baseball pitching, applies massive stress on the elbow. This can often lead to a predictable constellation of elbow injuries, such as valgus extension overload syndrome (VEO). The following review of VEO provides an understanding of relevant anatomy, explanation of pathomechanics, key aspects to clinical evaluation, effective treatment options, and indications for surgery. In addition, we provide the senior author's (CSA) preferred arthroscopic technique for cases of VEO refractory to conservative management.

The supraphysiological demands imposed on the elbow of a throwing athlete result in predictable patterns of injury. This is especially true of baseball pitchers. Knowledge of elbow anatomy, as well as the biomechanics of throwing, assist in making diagnostic and therapeutic decisions and also influence surgical technique when surgery is required. During the late cocking and early acceleration phases of throwing, valgus torque can reach 65 Nm with angular velocities of the forearm reaching 5000°/sec, which is considered the fastest recorded human movement.<sup>1</sup> The valgus torque and rapid extension synergistically create 3 major forces placed on the elbow. The first is a tensile stress along the medial aspect of elbow affecting the ulnar collateral ligament (UCL), flexor pronator mass, and medial epicondyle. Secondly, compression forces affect the lateral aspect of the elbow at the radiocapitellar joint. Finally, a shearing stress occurs in the posterior compartment at the posterior medial tip of the olecranon and the olecranon fossa.

These forces generated on the elbow result in predictable pathology. The recurring tensile

forces applied on the medial aspect on the elbow can compromise the integrity of the UCL. It is well known that injury to the UCL leads to valgus instability. Individuals with valgus instability who continue to throw may trigger and/or aggravate injury in the posterior and lateral components of the elbow. Lateral compression forces can often reach 500 N, resulting in radiocapitellar overload syndrome, which occurs in combination with medial ligament instability and valgus extension overload.<sup>2</sup> Radiocapitellar compression may cause chondral or osteochondral fracture with resulting intra-articular loose bodies. This compression also contributes to the etiology of osteochondritis dissecans (OCD) in skeletally immature athletes. In the posterior elbow, throwing forcefully and repeatedly pushes the olecranon into the olecranon fossa. Shear stress on the medial olecranon tip and fossa, due to combined valgus and extension forces, lead to the development of osteophytes. This collection of injuries in the medial, lateral, and posterior aspects of the elbow is known as "valgus extension overload syndrome" or VEO. Symptoms in VEO can be the result of chondral lesions, loose bodies, and marginal exostosis.<sup>3</sup>

The aim of this review is to provide understanding regarding both the relevant anatomy and pathomechanics of VEO, key aspects to clinical evaluation, and effective treatment options.

## Functional Anatomy

A functional comprehension of elbow anatomy and biomechanics is essential to understanding the constellation of injuries in VEO. The osseous anatomy of the elbow permits a variety of movements. These include flexion-extension and pronation-supination, which are mediated by the ulnohumeral and radiocapitellar articulations. While in full extension, the elbow has a normal valgus carrying angle of 11° to 16°. It is important to know that 50% of the elbow's stability is attributed to the configuration of the bones.<sup>4,6</sup> This is especially true in varus stress while the elbow is in full extension. The soft

**Authors' Disclosure Statement:** The authors report no actual or potential conflict of interest in relation to this article.

tissues, including muscle and ligaments such as the UCL, lateral UCL, and radial UCL complexes, provide the remaining elbow stability.<sup>4,6</sup>

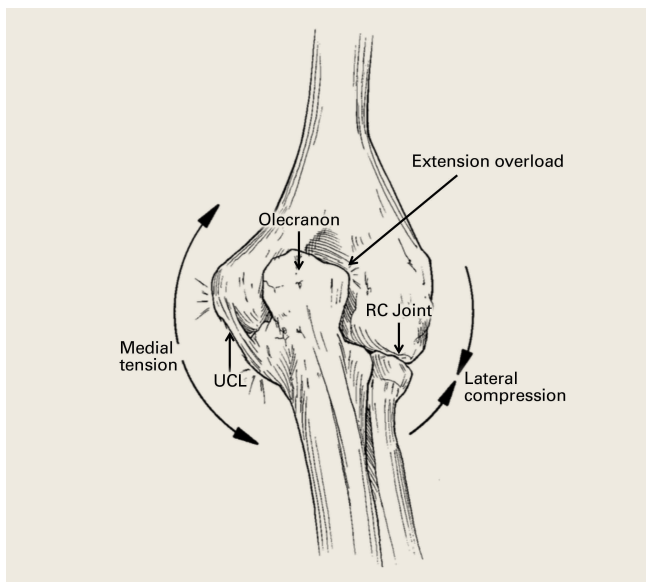
The UCL complex is composed of 3 main segments known as the anterior, posterior, and oblique bundles (transverse ligament). Collectively, these bundles are responsible for providing medial elbow stability. However, each of these bundles contributes to medial elbow stability in its own way. The first and arguably the most important bundle is the anterior bundle; its most important function is providing stability against valgus stress.<sup>4,5,7</sup> It is composed of parallel fibers inserting on the medial coronoid process.<sup>4,5,7</sup> Furthermore, its eccentric location with respect to the axis of elbow allows it to provide stability throughout the full range of elbow motion.<sup>6</sup> The anterior bundle can be further divided into individual anterior and posterior bands that have reciprocal functionality.<sup>5,8,9</sup> The anterior band acts as the chief restraint to valgus stress up to 90° of flexion.<sup>9</sup> Any flexion beyond 90° renders the anterior band's role secondary in resisting valgus stress.<sup>9</sup> The posterior band's function in resisting valgus stress is most important between 60° and full flexion, while having a secondary role in lesser degrees of flexion.<sup>8,9</sup> Notably, the posterior band is isometric and is more important in the overhead-throwing athlete due to the fact its primary role in resisting valgus stress occurs at higher degrees of flexion.<sup>10</sup>

The remaining posterior and oblique bundles of the UCL complex have lesser roles in maintaining elbow stability. The posterior bundle of the UCL complex is fan-shaped, originates from the medial epicondyle, and inserts onto the medial margin of the semi-lunar notch. It is more slender and frailer than the anterior bundle. This is reflected in its functionality, as it plays a secondary role in elbow stability during elbow flexion beyond 90°.<sup>4,5,8</sup> In contrast to the anterior and posterior bundles, the oblique bundle, also known as the transverse ligament, does not cross the elbow joint. It is a thickening of the caudal most aspect of the joint capsule, which extends from the medial olecranon to the inferior medial coronoid process and as a result functions in expanding the greater sigmoid notch.<sup>6</sup>

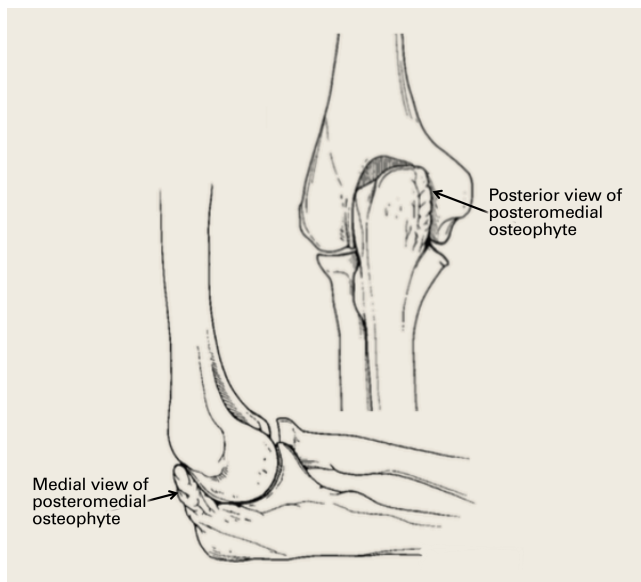
The musculotendinous components of the elbow are essential to providing dynamic functional resistance to valgus stress.<sup>11</sup> These components are flexor-pronator musculature that originate from the medial epicondyle. Listed proximally to distally, the flexor-pronator muscles include pronator teres, flexor carpi radialis (FCR), palmaris longus, flexor digitorum superficialis, and the flexor carpi ulnaris (FCU).

### Pathomechanics

Once familiarized with the relevant function anatomy, it is crucial to understand the mechanics of throwing in order to understand the pathomechan-



**Figure 1.** Medial tension overload that occurs with repetitive valgus stress at the elbow, resulting in attenuation of the ulnar collateral ligament (UCL), compression of the radiocapitellar (RC) joint laterally, and shear within the posterior compartment.



**Figure 2.** Posteromedial osteophytes within the olecranon fossa associated with valgus extension overload.

ics of VEO. The action of overhead throwing has been divided into 6 phases.<sup>6,12-16</sup> Phase 4, acceleration, is the most relevant when discussing forces on elbow, since the majority of forces are generated during this state. Phase 4 represents a rapid acceleration of the upper extremity with a large forward-directed force on the arm generated by the shoulder muscles. Additionally, there is internal rotation and adduction of the humerus with rapid elbow extension terminating with ball release. The elbow accelerates up to 600,000°/sec<sup>2</sup> in a miniscule time frame of 40 to 50 milliseconds.<sup>1,5</sup> Immense valgus forces are exerted on the medial aspect of the elbow. The anterior bundle of the UCL bears the majority of the force, with the flexor pronator mass enabling the transmission.<sup>11</sup> The majority of injuries occur during stage 4 as a result of the stress load on the medial elbow structures like the UCL. The proceeding phases 5 (deceleration), and 6 (follow-through) involve eventual dissipation of excess kinetic energy as the elbow completely extends. The deceleration during phase 5 is rapid and powerful, occurring at about 500,000°/sec<sup>2</sup> in the short span of 50 milliseconds.<sup>1,6,12-16</sup> High-velocity throwing, such as baseball pitching, generates forces in the elbow that are opposed by the articular, ligamentous, and muscular portions of the arm. The ulnohumeral articulation stabilizes motion of the arm from 0° to 20° of flexion and beyond 120° of flexion. Static and dynamic soft tissues maintain stability during the remaining of 100° arc of motion.

During deceleration, the elbow undergoes terminal extension resulting in the posteromedial olecranon contacting the trochlea and the olecranon fossa with subsequent dissipation of the combined valgus force and angular moment (**Figure 1**). This dissipation of force creates pathologic shear and compressive forces in the posterior elbow. Poor muscular control and the traumatic abutment that occurs in the posterior compartment may further add to the pathologic forces. Reactive bone formation is induced by the repetitive compression and shear, resulting in osteophytes on the posteromedial tip of the olecranon (**Figure 2**). Consequent “kissing lesions” of chondromalacia may occur in the olecranon fossa and posteromedial trochlea. The subsequent development of loose bodies may also occur. The presence of osteophytes and/or loose bodies may result in posteromedial impingement (PMI).

The association between PMI of the olecranon and valgus instability has been elucidated in both

clinical and biomechanical investigations.<sup>17,18,19,20</sup> Conway<sup>18</sup> identified tip exostosis in 24% of lateral radiographs of 135 asymptomatic professional pitchers. Approximately one-fifth (21%) of these pitchers had >1.0 mm increased relative valgus laxity on stress radiographs. Roughly one-third (34%) of players with exostosis had >1.0 mm of increased relative valgus laxity, compared to 16% of players without exostosis formation. These results provide evidence for a probable association between PMI and valgus laxity. In biomechanical research, Ahmad and colleagues<sup>17</sup> studied the effect of partial and full thickness UCL injuries on contact forces of the posterior elbow. Posteromedial compartments of cadaver specimens were subjected to physiologic valgus stresses while placed on pressure-sensitive film. Contact area and pressure between posteromedial trochlea and olecranon were altered in the setting of UCL insufficiency, helping explain how posteromedial osteophyte formation occurs.

Additional biomechanical studies have also investigated the posteromedial olecranon's role in functioning as a stabilizing buttress to medial tensile forces. Treating PMI with aggressive bone removal may increase valgus instability as well as strain on the UCL, leading to UCL injury following olecranon resection.<sup>19,20</sup> Kamineni and colleagues<sup>19</sup> investigated strain on anterior bundle of UCL as a function of increasing applied torque and posteromedial resections of the olecranon. This investigation was done utilizing an electromagnetic tracking placed in cadaver elbows. A nonuniform change in strain was found at 3 mm of resection during flexion and valgus testing. This nonuniform change implied that removal of posteromedial olecranon beyond 3 mm made the UCL more vulnerable to injury. Follow-up investigations looked at kinematic effects of increasing valgus and varus torques and sequential posteromedial olecranon resections.<sup>20</sup> Valgus angulation of the elbow increased with all resection levels but no critical amount of olecranon resection was identified. The consensus in the literature indicates that posteromedial articulation of the elbow is a significant stabilizer to valgus stress.<sup>17-22</sup> Thus, normal bone should be preserved and only osteophytes should be removed during treatment.

In addition, VEO may lead to injury in the lateral compartment as well. After attenuation and insufficiency of the UCL due to repetitive stress, excessive force transmission to the lateral aspect of the elbow occurs. Compressive and rotatory

forces escalate within the radiocapitellar joint, causing synovitis and osteochondral lesions.<sup>3,23</sup> These osteochondral lesions include osteochondritis dissecans and osteochondral fractures that may fragment and become loose bodies.

## Evaluation of VEO

### History

Patients will typically have a history of repetitive throwing or other repetitive overhead activity. VEO is most common in baseball pitchers but may also occur in other sports, such as tennis, football, lacrosse, gymnastics, and javelin throwing. In baseball pitchers, clinical presentation is often preceded by a decrease in pitch velocity, control, and early fatigability. It presents with elbow pain localized to the posteromedial aspect of olecranon after release of the ball, when the elbow reaches terminal extension. Patients also report limited extension, due to impinging posterior osteophytes. Also, locking and catching caused by loose bodies and chondromalacia may be present. VEO may also occur in combination with concomitant valgus instability, as well as in a patient with a prior history of valgus instability. Flexor pronator injury, ulnar neuritis, and subluxation may also be present in a patient with VEO.

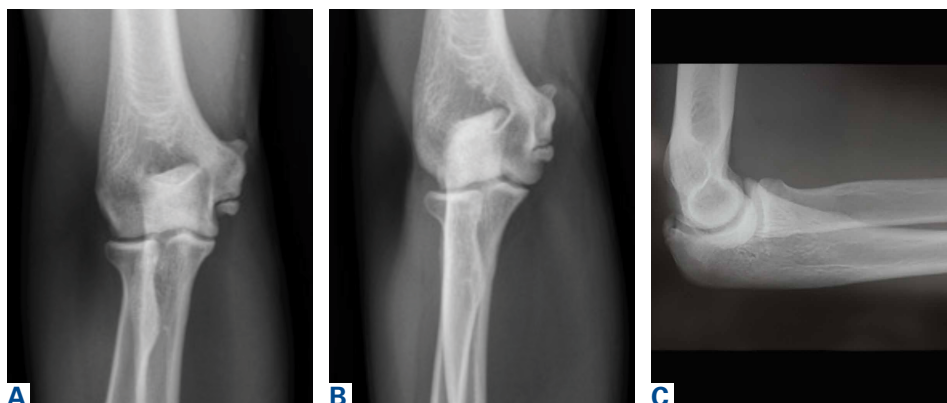
### Physical Examination

VEO may occur in an isolated fashion or with concomitant pathology. Therefore, a comprehensive physical examination includes evaluating the entire kinetic chain of throwing and a focused examination covering VEO and associated valgus instability. Patients may exhibit crepitus and tenderness over the posteromedial olecranon and a loss of extension with a firm end point. The extension impingement test should be performed where the elbow is snapped into terminal extension. This typically elicits pain in the posterior compartment in a patient with VEO. The arm bar test involves positioning the patient's shoulder at 90° of forward flexion, full internal rotation, with the patient's hand placed on the examiner's shoulder.<sup>24</sup> The examiner pulls down on the olecranon, simulating forced extension; pain is indicative of a positive test. It is important to note if there are signs of

ulnar neuritis or subluxing ulnar nerve, especially if planning to utilize medial portals during arthroscopic treatment.

Examination maneuvers for valgus instability should also be conducted during evaluation of VEO. The physical examination for valgus instability in the elbow is ideally performed with the patient seated. Secure the patient's wrist between the examiner's forearm and trunk, and flex the patient's elbow between 20° and 30° to unlock the olecranon from its fossa. Proceed to apply valgus stress. This stresses the anterior band of the anterior bundle of the UCL.<sup>6,25,26</sup> Palpate the UCL from the medial epicondyle to the proximal ulna as valgus stress is applied. Occasionally, valgus laxity can be appreciated when compared to contralateral side. The milking maneuver is a helpful test to determine UCL injury. Pull on the patient's thumb while the forearm is supinated, shoulder extended, and the elbow flexed beyond 90°. The milking maneuver exerts valgus stress on a flexed elbow. A patient with an injured UCL will experience the subjective feeling of apprehension and instability, with medial elbow pain.

The most sensitive test is the moving valgus stress test. This is performed with the patient in the upright position and the shoulder abducted 90°. Starting with the arm in full flexion, the examiner applies a constant valgus torque to the elbow and then rapidly extends the elbow. Reproduction of pain during range of motion from 120° to 70° represents UCL injury, while pain with extension beyond 70° represents chondral injury to the ulnohumeral joint. Be aware that the absence of increased pain with wrist flexion, along with pain localized slightly posterior to the common flexor origin, differentiates a UCL injury from flexor-prona-



**Figure 3.** (A) Anterior posterior, (B) oblique, and (C) lateral radiographs demonstrating posteromedial olecranon osteophytes and calcification of the ulnar collateral ligament.

tor muscle injury.<sup>6,26,27</sup> Examine range of motion in affected and unaffected elbows. Loss of terminal extension may be present, along with secondary to flexion contracture due to repeated attempts at healing and stabilization.<sup>25</sup>

## Imaging

Imaging is essential to the accurate diagnosis of VEO and related conditions. Anterior posterior (AP), lateral, and oblique radiographs of elbow (**Figures 3A-3C**) may show posteromedial olecranon osteophytes and/or loose bodies. Calcification of ligaments or other soft tissues may also be seen. An AP radiograph with 140° of external rotation may best visualize osteophytes on posteromedial olecranon.<sup>18</sup> A computed tomography scan with 2-dimensional sagittal and coronal reconstruction and 3-dimensional surface rendering (**Figures 4A, 4B**) may best demonstrate morphological abnormalities, loose bodies, and osteophytes. Magnetic resonance imaging (MRI) is essential for assessment of soft tissues and chondral injuries. MRI may detect UCL compromise, synovial plicae, bone edema, olecranon, or stress fractures.

## Treatment

### Nonoperative Treatment

Treatment consists of both nonoperative and operative modalities. Nonoperative treatment methods are first line in treating VEO. Patients should modify their physical activity and rest from throwing activities. Nonsteroid anti-inflammatory drugs are appropriate to treat pain along with intra-articular corticosteroid injections of the elbow. A wide assessment of pitching mechanics should be performed in an attempt to correct errors in throwing technique and address muscular imbalances. After cessation of the resting period, the patient may

initiate a progressive throwing program supervised by an experienced therapist and trainer. A plan for returning to competition should be made upon completion of the throwing program.

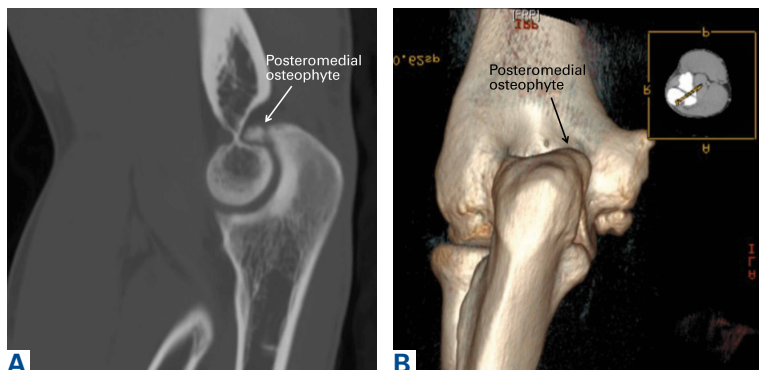
### Operative Treatment

Surgical treatment is reserved for patients who fail nonoperative treatment. These patients have persistent symptoms of posteromedial impingement and desire to return to pre-injury level of performance. Posteromedial decompression is not recommended when provocative physical examination maneuvers are negative, regardless of presence of olecranon osteophytes on imaging. Osteophytes are an asymptomatic finding typically seen in professional baseball players and do not warrant surgical treatment.<sup>18,28</sup> UCL compromise is a relative contraindication to olecranon debridement as UCL injury could become symptomatic following surgery. Surgical options in the appropriate patient to decompress posterior compartment include arthroscopic olecranon debridement or limited incision arthrotomy. Excessive resection of posteromedial osteophytes must be avoided. Arthroscopy has limited morbidity and allows for complete diagnostic assessment. UCL reconstruction should also be considered in combination with posteromedial debridement when the UCL is torn. More challenging indications for UCL reconstruction occur when the UCL is partially torn or torn and asymptomatic. Isolated posteromedial decompression in this setting risks future development of UCL symptoms that would then need to be addressed.

### Surgical Technique

As previously mentioned, elbow arthroscopy or limited excision arthrotomy are the preferred operative methods for decompression of the posterior compartment and thus treatment of VEO. Anesthesia and patient positioning should be selected based on the surgeon's preference. The patient should be positioned supine, prone, or in lateral decubitus. When a UCL reconstruction is expected, supine position is advantageous to avoid repositioning after completing the arthroscopic portion of the procedure. However, arthroscopy can be performed in the lateral position with subsequent repositioning, repeat prepping, and draping for UCL reconstruction (**Figures 5A, 5B**).

Prepare for elbow arthroscopy by distending the elbow joint with normal saline to aid in protection of neurovascular structures and simplify the



**Figure 4.** (A) Sagittal computed tomography scan and (B) 3-dimensional coronal reconstruction demonstrating an osteophyte on the posteromedial aspect of the olecranon.

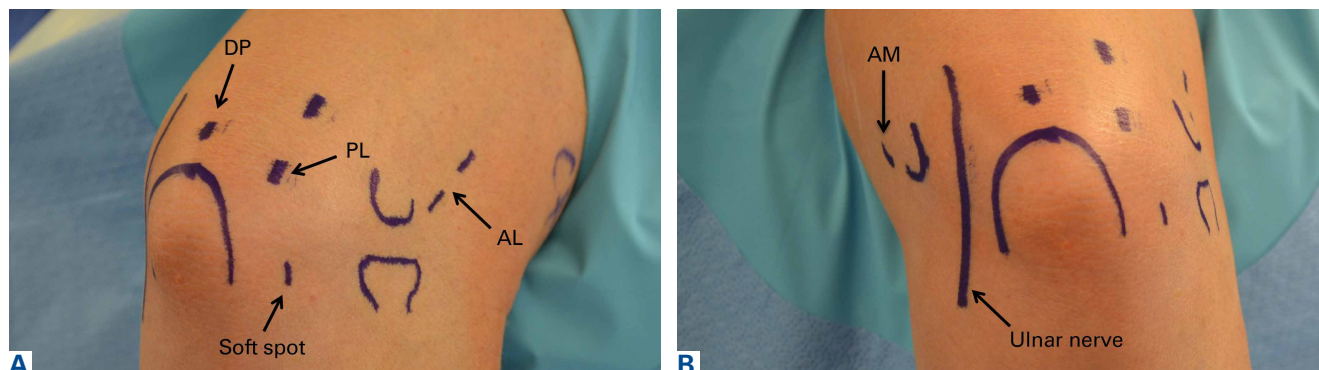


insertion of the scope trocar. Perform diagnostic anterior arthroscopy via the proximal anteromedial portal. Assess for presence of loose bodies and osteochondral lesions of the radiocapitellar joint, as well as osteophytes of the coronoid tip and fossa. Utilizing a spinal needle under direct visualization establish a proximal lateral portal with adequate view of the anterior compartment. Proceed to visualize the medial compartment and assess for UCL injury. Apply valgus stress while in 70° of flexion. Visualize the coronoid process and look for medial trochlea gapping of 3 mm or greater, which indicates UCL insufficiency.<sup>30</sup>

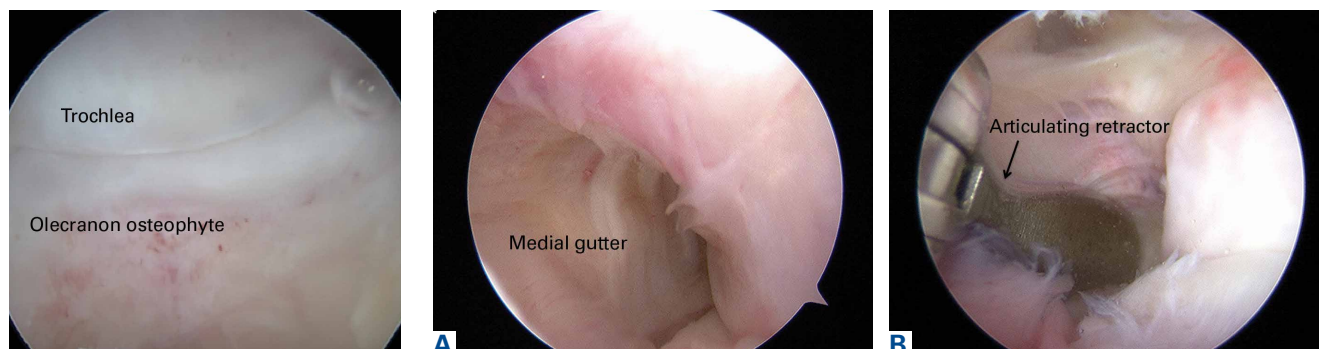
Establish the posterolateral port for visualization of the posterior compartment. A posterior portal is established through the triceps tendon. Proceed to shave and ablate synovitis in order to create an adequate working space. Inspect the posteromedial olecranon, looking for any osteophytes or chondromalacia in the area (**Figure 6**). Examine the posterior radiocapitellar joint, looking specifically for loose bodies. The presence of loose bodies may require creating an extra mid lateral portal

for removal. The ulnar nerve is located superficial to the elbow capsule and can be damaged by instruments utilized in the posteromedial gutter. As a precaution, be sure to remove suction attached to shaver. Place a curved articulating retractor in an accessory posterolateral portal to assist in protecting the ulnar nerve by retracting the capsule away from the surgical field (**Figures 7A, 7B**).

The osteophyte may be encased in soft tissue. Using a combination of ablation devices and shavers, the osteophyte can be exposed. The olecranon osteophyte can be removed with a small osteotome located at the border of the osteophyte and the normal olecranon. A motorized shaver or burr may also be introduced through the direct posterior portal or the posterolateral portal to complete the contouring of the olecranon (**Figures 8A, 8B**). Intraoperative lateral radiographs may be obtained for guidance in adequate bone removal and to ensure no bone debris is left in the soft tissues. It is critical that only pathologic osteophyte is removed and that normal olecranon is not compromised. This prevents an increase in UCL strain during

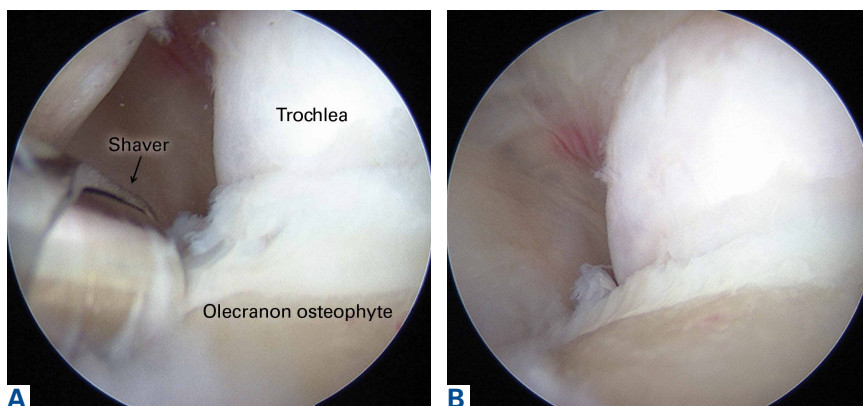


**Figure 5.** External skin markings for portal placement on the (A) medial and (B) lateral sides of the elbow. Abbreviations: AL, anterolateral; AM, anteromedial; DP, direct posterior; PL, posterolateral.



**Figure 6.** Diagnostic posterior arthroscopy demonstrating an olecranon osteophyte on the posteromedial aspect of the olecranon.

**Figure 7.** (A) Location of the ulnar nerve superficial to the capsule in the medial gutter with (B) placement of an articulating retractor to protect the ulnar nerve when working on the posteromedial aspect of the olecranon.



**Figure 8.** (A) Removal of the olecranon osteophyte with a shaver, (B) creating a well-contoured olecranon tip after completion of resection.

valgus loading.<sup>19</sup> However, in some non-throwing athletes, more aggressive debridement can be performed due to a smaller risk of UCL injury after posterior decompression.

Often, with the presence of osteophytes on the olecranon, there may be associated chondromalacia of the trochlea. These kissing lesions must be addressed after debridement of osteophytes. Loose flaps or frayed edges are carefully debrided and for any significant lesion the edges are contoured to a stable rim using shavers and curettes. Once altered to a well-shouldered lesion, microfracture is performed. Anterograde drilling of the lesion with perforations separated by 2 to 3 mm allow for the release of marrow elements and induction of a fibrocartilage healing response.

For an isolated posteromedial decompression, early rehabilitation begins with simple elbow flexion and extension exercises. It is important to restore flexor-pronator strength. Six weeks postoperatively, a progressive throwing program that includes plyometric exercises, neuromuscular training, and endurance exercises can be initiated. Patients can typically return to competition 3 to 4 months after surgery, if they have successfully regained preoperative range of motion, preoperative strength in the elbow, and there is no pain or tenderness on stress testing or palpation.

## Outcomes

### Safety and Advances in Arthroscopy

A clearer understanding of portal placement and proximity to neurovasculature in conjunction with advances in equipment have allowed for continual improvements in elbow arthroscopy techniques. There is plenty of literature indicating that arthroscopic posteromedial decompression is a

safe, reliable, effective procedure, with a high rate of patient satisfaction.<sup>22,30-34</sup> Andrews and Carson<sup>30</sup> published one of the earliest investigations indicating the effectiveness of elbow arthroscopy utilizing objective and subjective outcome scores. They found that preoperative scores indicating patient satisfaction increased from 50% to 83%. Patients who underwent only loose body removal had the best outcomes. Andrews and Timmerman<sup>31</sup> later evaluated the results of 72 professional baseball players who underwent either arthroscopic or open elbow surgery. They found that posteromedial olecranon osteophytes and intraarticular loose bodies were the most

common diagnoses, present in 65% and 54% of players, respectively. In addition, a 41% reoperation rate was reported after posteromedial olecranon resection, along with 25% a rate of valgus instability necessitating UCL reconstruction. Andrews and Timmerman<sup>31</sup> propose that the incidence of UCL injuries is underestimated and that UCL pathology must be treated prior to treating its secondary effects. Recently, Reddy and colleagues<sup>32</sup> reviewed the results of 187 arthroscopic procedures. Posterior impingement, loose bodies, and osteoarthritis were the most common problems, occurring in 51%, 31%, and 22% of patients, respectively. Reported results were encouraging, with 87% good to excellent results and 85% of baseball players returning to preinjury levels.

## Conclusion

An understanding of the relevant functional anatomy and the biomechanics of throwing is essential to understanding VEO. Potential concomitant valgus instability and UCL injury must be carefully assessed. Only symptomatic patients who have failed conservative treatment should undergo surgery. It is critical to avoid exacerbating and/or causing valgus instability by surgical excessively removing normal bone from the olecranon. Arthroscopy has been shown to be a safe and effective method to treat refractory cases of VEO.

Mr. Paulino is a Medical Student Research Assistant, Dr. Villacis is Clinical Fellow, Orthopaedic Surgery, and Dr. Ahmad is Professor of Orthopaedic Surgery and Chief of Sports Medicine, Center for Shoulder, Elbow and Sports Medicine, Columbia University Medical Center, New York, New York.

Address correspondence to: Christopher S. Ahmad, MD, Center for Shoulder, Elbow and Sports Medicine, New York Presbyterian/Columbia University Medical Center, 622 West 168th Street, PH-1122, New York, NY 10032 (tel, 212-305-8188; email, csa4@columbia.edu).

*Am J Orthop.* 2016;45(3):144-151. Copyright Frontline Medical Communications Inc. 2016. All rights reserved.

## References

- Pappas AM, Zawacki RM, Sullivan TJ. Biomechanics of baseball pitching. A preliminary report. *Am J Sports Med.* 1985;13(4):216-222.
- Fleisig GS, Barrentine SW, Escamilla RF, Andrews JR. Biomechanics of overhand throwing with implications for injuries. *Sports Med.* 1996;21(6):421-437.
- Wilson FD, Andrews JR, Blackburn TA, McCluskey G. Valgus extension overload in the pitching elbow. *Am J Sports Med.* 1983;11(2):83-88.
- Morrey BF. Applied anatomy and biomechanics of the elbow joint. *Instr Course Lect.* 1986;35:59-68.
- Schwab GH, Bennett JB, Woods GW, Tullos HS. Biomechanics of elbow instability: the role of medial collateral ligament. *Clin Orthop Relat Res.* 1980;146:42-52.
- Jobe FW, Kvitne RS. Elbow instability in the athlete. *Instr Course Lect.* 1991;40:17-23.
- Søjbjerg JO, Ovesen J, Nielsen S. Experimental elbow instability after transection of the medial collateral ligament. *Clin Orthop Relat Res.* 1987;218:186-190.
- Regan WD, Korinek SL, Morrey BF, An KN. Biomechanical study of ligaments around the elbow joint. *Clin Orthop Relat Res.* 1991;271:170-179.
- Callaway GH, Field LD, Deng XH, et al. Biomechanical evaluation of the medial collateral ligament of the elbow. *J Bone Joint Surg Am.* 1997;79(8):1223-1231.
- Chen FS, Rokito AS, Jobe FW. Medial elbow problems in the overhead-throwing athlete. *J Am Acad Orthop Surg.* 2001;9(2):99-113.
- Davidson PA, Pink M, Perry J, Jobe FW. Functional anatomy of the flexor pronator muscle group in relation to the medial collateral ligament of the elbow. *Am J Sports Med.* 1995;23(2):245-250.
- Jobe FW, Moynes DR, Tibone JE, Perry J. An EMG analysis of the shoulder in pitching. A second report. *Am J Sports Med.* 1984;12(3):218-220.
- Hamilton CD, Glousman RE, Jobe FW, Brault J, Pink M, Perry J. Dynamic stability of the elbow: electromyographic analysis of the flexor pronator group and the extensor group in pitchers with valgus instability. *J Shoulder Elbow Surg.* 1996;5(5):347-354.
- Glousman RE, Barron J, Jobe FW, Perry J, Pink M. An electromyographic analysis of the elbow in normal and injured pitchers with medial collateral ligament insufficiency. *Am J Sports Med.* 1992;20(3):311-317.
- DiGiovine NM, Jobe FW, Pink M, Perry J. An electromyographic analysis of the upper extremity in pitching. *J Shoulder Elbow Surg.* 1992;1(1):15-25.
- Sisto DJ, Jobe FW, Moynes DR, Antonelli DJ. An electromyographic analysis of the elbow in pitching. *Am J Sports Med.* 1987;15(3):260-263.
- Ahmad CS, Park MC, Elattrache NS. Elbow medial ulnar collateral ligament insufficiency alters posteromedial olecranon contact. *Am J Sports Med.* 2004;32(7):1607-1612.
- Ahmad CS, Conway J. Elbow arthroscopy: beginners to advanced: valgus extension overload. In: Egol, ed. *Instructional Course Lectures*; vol 60. Rosemont, IL: American Academy of Orthopaedic Surgeons; submitted 2009.
- Kamineni S, ElAttrache NS, O'Driscoll SW, et al. Medial collateral ligament strain with partial posteromedial olecranon resection. A biomechanical study. *J Bone Joint Surg Am.* 2004;86-A(11):2424-2430.
- Kamineni S, Hirahara H, Pomianowski S, et al. Partial posteromedial olecranon resection: a kinematic study. *J Bone Joint Surg Am.* 2003;85-A(6):1005-1011.
- Morrey BF, An KN. Articular and ligamentous contributions to the stability of the elbow joint. *Am J Sports Med.* 1983;11(5):315-319.
- O'Driscoll SW, Morrey BF. Arthroscopy of the elbow. Diagnostic and therapeutic benefits and hazards. *J Bone Joint Surg Am.* 1992;74(1):84-94.
- Miller CD, Savoie FH 3rd. Valgus extension injuries of the elbow in the throwing athlete. *J Am Acad Orthop Surg.* 1994;2(5):261-269.
- O'Driscoll SW. Valgus extension overload and plica. In: Levine WN, ed. *The Athlete's Elbow.* Rosemont, IL: American Academy of Orthopaedic Surgeons; 2008:71-83.
- Boatright JR, D'Alessandro DF. Nerve entrapment syndromes at the elbow. In Jobe FW, Pink MM, Glousman RE, Kvitne RE, Zemel NP, eds. *Operative Techniques in Upper Extremity Sports Injuries.* St. Louis, MO: Mosby-Year Book; 1996: 518-537.
- Conway JE, Jobe FW, Glousman RE, Pink M. Medial instability of the elbow in throwing athletes. Treatment by repair or reconstruction of the ulnar collateral ligament. *J Bone Joint Surg Am.* 1992;74(1):67-83.
- Jobe FW, Stark H, Lombardo SJ. Reconstruction of the ulnar collateral ligament in athletes. *J Bone Joint Surg Am.* 1986;68(8):1158-1163.
- Kooima CL, Anderson K, Craig JV, Teeter DM, van Holsbeeck M. Evidence of subclinical medial collateral ligament injury and posteromedial impingement in professional baseball players. *Am J Sports Med.* 2004;32(7):1602-1606.
- Field LD, Altchek DW. Evaluation of the arthroscopic valgus instability test of the elbow. *Am J Sports Med.* 1996;24(2):177-181.
- Andrews JR, Carson WG. Arthroscopy of the elbow. *Arthroscopy.* 1985;1(2):97-107.
- Andrews JR, Timmerman LA. Outcome of elbow surgery in professional baseball players. *Am J Sports Med.* 1995;23(4):407-413.
- Reddy AS, Kvitne RE, Yocum LA, Elattrache NS, Glousman RE, Jobe FW. Arthroscopy of the elbow: a long-term clinical review. *Arthroscopy.* 2000;16(6):588-594.
- Rosenwasser MP, Steinmann S. Elbow arthroscopy in the treatment of posterior olecranon impingement. Paper presented at: AANA Annual Meeting; 1991; San Diego, CA.
- Wilson FD, Andrews JR, Blackburn TA, McCluskey G. Valgus extension overload in the pitching elbow. *Am J Sports Med.* 1983;11(2):83-88.