

[Edit Article](#)

# Snapping Biceps Femoris Tendon

Publish date: July 17, 2018

Authors:

MAJ Justin J. Ernat, MD MAJ Joseph W. Galvin, DO

Author Affiliation | **Disclosures**

**Author's Disclosure Statement:** The authors report no actual or potential conflict of interest in relation to this article. The views, opinions, and items discussed are those of the authors and do not reflect the work of the United States Government.

Dr. Ernat and Dr. Galvin are Orthopedic Surgeons, Blanchfield Army Community Hospital, Fort Campbell, Kentucky.

Address correspondence to: MAJ Justin J. Ernat, MD, Blanchfield Army Community Hospital, 650 Joel Dr., Fort Campbell, KY 42223 (tel, 815-252-9486; email, [Justin.ernat@gmail.com](mailto:Justin.ernat@gmail.com)).

*Am J Orthop.* 2018;47(7). Copyright Frontline Medical Communications Inc. 2018. All rights reserved.

---

## Take-Home Points

- Snapping biceps femoris is a rare, but debilitating condition.
- Understanding the pathology from an anatomical perspective is key.
- For bone abnormalities, correct the bony pathology to relieve the snapping.
- For soft tissue abnormalities, both excisional and reconstructive approaches can be utilized.
- Preservation of normal anatomy, when possible, can help expedite recovery.

Snapping in the knee is not as common as in other joints, such as the hip or ankle. The snapping sensation can occur from several pathologies, including the following: lateral meniscal tears, iliotibial band syndrome, proximal tibiofibular instability, snapping popliteus, peroneal nerve compression/neuritis, lateral discoid meniscus, rheumatoid nodules, plicae, congenital snapping knee, exostoses, or previous trauma.<sup>1,2</sup> A detailed history must be provided, and physical examination and appropriate imaging must be performed to narrow down the differential diagnosis and prescribe the appropriate course of treatment for snapping.

Snapping biceps femoris syndrome is a rare cause of knee snapping. This condition has been described in various case reports.<sup>2-13</sup> The reasons for a snapping biceps femoris can vary, and the treating provider must be ready to accommodate and treat these causes. The symptoms typically include an audible, and usually visual, lateral snapping distal to the knee joint and over the fibular head. Imaging may reveal bony abnormalities such as fibular exostoses. Magnetic resonance imaging (MRI) can aid in determining any anomalous or abnormal insertions of the biceps femoris tendon. The snapping can be debilitating, particularly in athletes or patients with high-demand

occupations, and surgical intervention is often warranted.

We present a case of an active-duty military service member with symptomatic unilateral snapping biceps femoris and review the literature for treatment of this condition. Surgical release allowed the patient a quick and unrestricted return to full mission capabilities.

The patient provided written informed consent for print and electronic publication of this case report.

## Case Report

A 23-year-old active-duty soldier presented to the orthopedic clinic with several months of noticeable snapping and pain over the lateral knee with attempted running and deep squatting activities, resulting in difficulty to perform his army duties. The patient reported no history of antecedent trauma. No locking of the knee or paresthesia distally into the leg or foot was observed.

The physical examination revealed a palpable and observable snapping of the long head of the biceps tendon over the fibular head with squatting beyond 90° in the left knee. (**Video 1**). The patient presented with full strength and no instability or joint line pain throughout the knee. Application of a posterior-to-anterior directed force over the biceps femoris proximal to the insertion allowed the patient to perform a deep squat without snapping. The radiographs demonstrated no abnormal fibular morphology (**Figures 1A, 1B**). Axial MRI images demonstrated an anomalous slip of the tendon inserting on the anterolateral aspect of the proximal tibia in addition to the normal insertion on the posterolateral and lateral edge of the fibular head (**Figure 2**) as described by Terry and LaPrade.<sup>14</sup>

A conservative treatment with physical therapy, activity modification, and a Cho-Pat knee strap (to provide a posterior-to-anterior buttress and to prevent snapping) was attempted for 4 weeks. However, the patient could not tolerate the strap, and the activity restraints prevented him from performing his job as an active-duty soldier. Given the failure of conservative treatment, operative intervention was elected.

Upon exploration of the biceps femoris insertion, the accessory anterolateral tibial insertion was readily identified (**Figure 3**). Notably, the expected normal lateral edge insertion was thickened and extended beyond the lateral edge, distal, and anterior on to the fibular head (**Figure 4, Video 2**). The anterolateral tibial band was released first. However, the snapping remained evident. The thickened anterior fibular accessory band was then released back to its normal, lateral edge, and at this point, no further snapping was observed with deep flexion of the knee (**Video 3**). Inspection of the remaining posterolateral and lateral edge insertion demonstrated a healthy, 1-cm thick tendinous insertion. The accessory slips were completely excised, and the incision was closed without any additional repair or re-insertion (**Figure 5**). The patient presented no complications postoperatively. He was allowed to bear weight as tolerated and was limited to stretching and gravity resistance training for 4 weeks. At 1 month, the patient was released to progress back to full activity (**Video 4**). By 8 weeks postoperative, he remained free of snapping and resumed his regular running routine and military duties without restriction or pain.

## Discussion

Release of the anomalous bands with no further repair or re-insertion of the biceps femoris allowed this active-duty soldier to resume full running and duty-related activities in <2 months. In this particular patient, given his anatomy, the treatment was successful. The literature indicates that optimal results and surgical approach depend upon the pathological anatomy encountered.

Date and colleagues<sup>4</sup> described a similar anatomical anomaly as with our patient, whom after the release of tibial insertion, snapping was still observed, thus requiring the release of anterior fibular insertion. They noted the necessity of suturing the accessory limbs onto the periosteum of the fibular head to achieve a stable biceps femoris.

In other cases, abnormal bony anatomy of the fibula has been shown to cause snapping. Vavalle and Capozzi<sup>5</sup> described a case of snapping biceps in a marathon runner, who needed partial resection of the fibular head to eliminate snapping. The runner made a full return to the sport. Fung and colleagues<sup>2</sup> described a similar approach to a 17-year-old cyclist; however, this patient presented exostoses of the bilateral fibular heads. The exostoses were bilaterally excised, and the snapping ceased. Kristensen and colleagues<sup>13</sup> described a patient with an anomalous tibial insertion. Rather than releasing the tibial insertion, a partial resection of the fibular head allowed for cessation of snapping.

Other authors advocate the detachment and anatomic re-insertion of the biceps femoris into the fibular head. Bernhardson and LaPrade<sup>6</sup> reported a series of 3 patients requiring this approach with excellent results. Bansal and colleagues<sup>8</sup> were the first to describe a soccer player with an isolated injury to the knee as a traumatic cause for a snapping biceps femoris. After failure of conservative treatment attempts, exploration and re-insertion through a bone tunnel allowed for return to the sport. Hernandez and colleagues<sup>11</sup> and Lokiec and colleagues<sup>12</sup> both described the reproduction of the normal biceps femoris anatomy through re-insertion procedures after identifying patients with abnormal anatomical insertions as causes for snapping.

## Conclusion

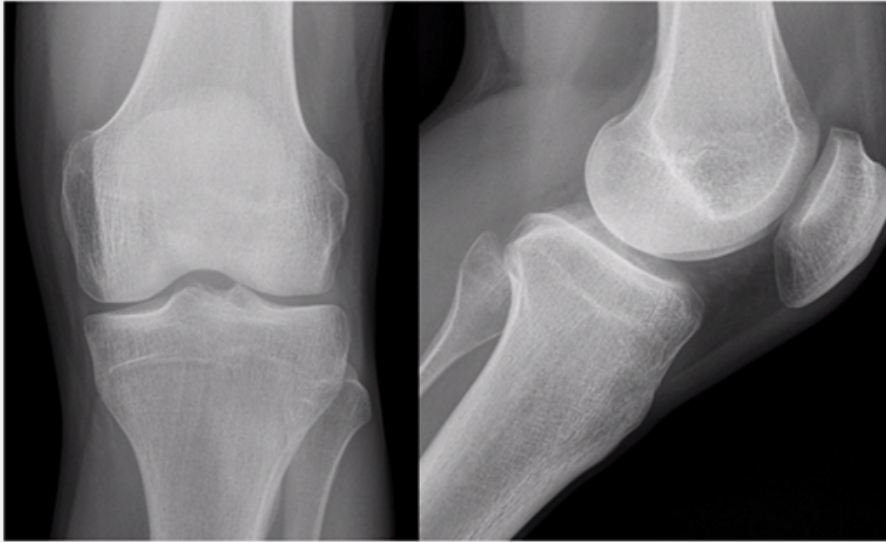
We presented a case of an active military service member with a unilateral snapping biceps femoris tendon due to an anomalous distal insertion on both the proximal tibia and anterior fibular head. The release of abnormal insertions and maintenance of his normal anatomical insertion allowed for a quick and effective return to running and duty at full capacity. Although other surgical approaches have been described to include partial fibular head resection or anatomical re-insertion, we believe that the approach to this rare condition should be anatomy-based as the causes of snapping can significantly vary. We believe that if the normal posterolateral and lateral edge insertions of the biceps femoris are intact, removal of the abnormal anatomy without any repair or reconstruction can safely lead to successful surgical outcomes.

## Key Info

## Figures/Tables

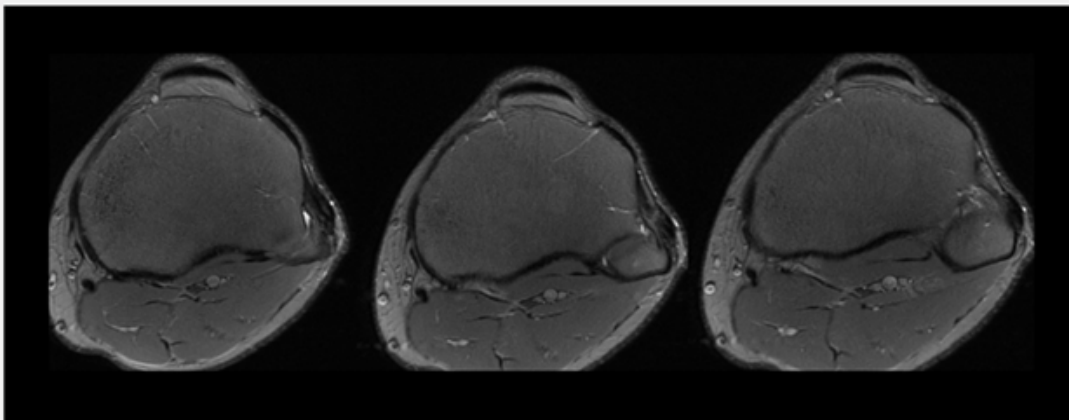
Figures / Tables:

[ernat0718\\_f1.jpg](#)



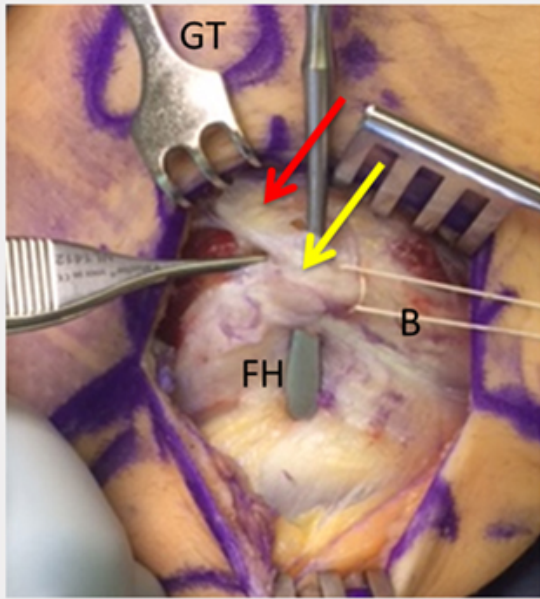
**Figure 1.** (A, B) No fibular head abnormalities on radiographs of the affected knee.

[ernat0718\\_f2.jpg](#)



**Figure 2.** Sequential proton-density fat-suppression magnetic resonance imaging sequences demonstrating anomalous anterior fibular and anterolateral proximal tibial biceps femoris insertions.

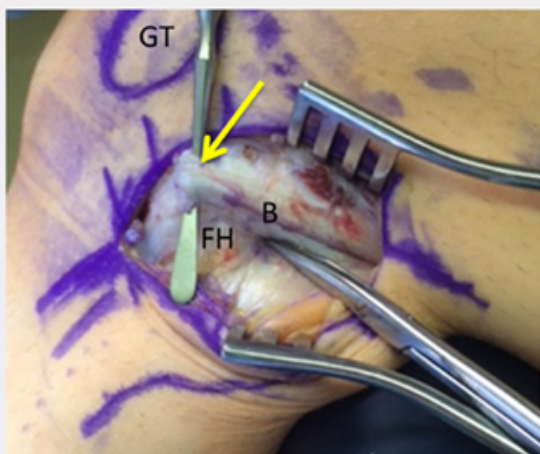
[ernat0718\\_f3.jpg](#)



**Figure 3.** The red arrow points to the anomalous tibial insertion. The yellow arrow points to the anomalous anterior fibular head insertion.

Abbreviations: B, biceps femoris; FH, fibular head; GT, Gerdy's tubercle.

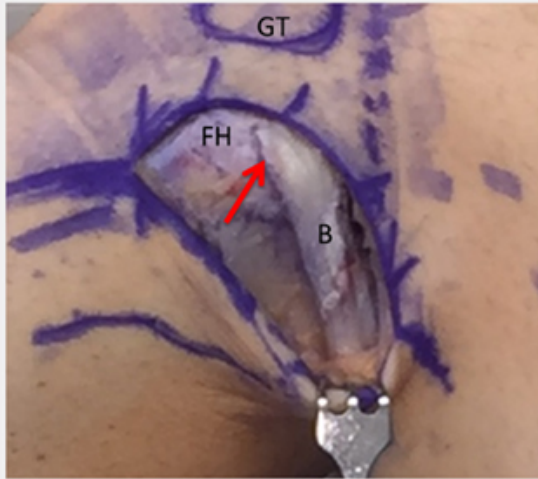
[ernat0718\\_f4.jpg](#)



**Figure 4.** The yellow arrow represents the anomalous insertion on the anterior fibula after the tibial insertion has been released. The tenotomy scissor is abutting the posterior aspect of the fibular styloid.

Abbreviations: B, biceps femoris; FH, fibular head; GT, Gerdy's tubercle.

ernat0718\_f5.jpg



**Figure 5.** The red arrow represents the natural lateral edge insertion of the biceps femoris tendon.  
Abbreviations: B, biceps femoris; FH, fibular head; GT, Gerdy's tubercle.

## References

### References

#### References

1. Barker JU, Strauss EJ, Lodha S, Bach BR Jr. Extra-articular mimickers of lateral meniscal tears. *Sports Health*. 2011;3(1):82-88.
2. Fung DA, Frey S, Markbreiter L. Bilateral symptomatic snapping biceps femoris tendon due to fibular exostosis. *J Knee Surg*. 2008;21(1):55-57.
3. Mirchandani M, Gandhi P, Cai P. Poster 175 bilateral symptomatic snapping knee from biceps femoris tendon subluxation-an atypical cause of bilateral knee pain: a case report. *PM R*. 2016;8(9S):S218-S219.
4. Date H, Hayakawa K, Yamada H. Snapping knee due to the biceps femoris tendon treated with repositioning of the anomalous tibial insertion. *Knee Surg Sports Traumatol Arthrosc*. 2012;20(8):1581-1583.
5. Vavalle G, Capozzi M. Symptomatic snapping knee from biceps femoris tendon subluxation: an unusual case of lateral pain in a marathon runner. *J Orthop Traumatol*. 2010;11(4):263-266.
6. Bernhardson AS, LaPrade RF. Snapping biceps femoris tendon treated with an anatomic repair. *Knee Surg Sports Traumatol Arthrosc*. 2010;18(8):1110-1112.



7. Guillin R, Mendoza-Ruiz JJ, Moser T, Ropars M, Duvauferrier R, Cardinal E. Snapping biceps femoris tendon: a dynamic real-time sonographic evaluation. *J Clin Ultrasound*. 2010;38(8):435-437.
8. Bansal R, Taylor C, Pimpalnerkar AL. Snapping knee: an unusual biceps femoris tendon injury. *Knee*. 2005;12(6):458-460.
9. Bagchi K, Grelsamer RP. Partial fibular head resection for bilateral snapping biceps femoris tendon. *Orthopedics*. 2003;26(11):1147-1149.
10. Kissenberth MJ, Wilckens JH. The snapping biceps femoris tendon. *Am J Knee Surg*. 2000;13(1):25-28.
11. Hernandez JA, Rius M, Noonan KJ. Snapping knee from anomalous biceps femoris tendon insertion: a case report. *Iowa Orthop J*. 1996;16:161-163.
12. Lokiec F, Velkes S, Schindler A, Pritsch M. The snapping biceps femoris syndrome. *Clin Orthop Relat Res*. 1992;(283):205-206.
13. Kristensen G, Nielsen K, Blyme PJ. Snapping knee from biceps femoris tendon. A case report. *Acta Orthop Scand*. 1989;60(5):621.
14. Terry GC, LaPrade RF. The biceps femoris muscle complex at the knee. Its anatomy and injury patterns associated with acute anterolateral-anteromedial rotator instability. *Am J Sports Med*. 1996;24:2-8.

## Multimedia

## Product Guide

### Product Guide

- [STRATAFIX™ Symmetric PDS™ Plus Knotless Tissue Control Device](#)
- [STRATAFIX™ Spiral Knotless Tissue Control Device](#)
- [BioComposite SwiveLock Anchor](#)
- [BioComposite SwiveLock C, with White/Black TigerTape™ Loop](#)

×

×

## Citation

MAJ Justin J. Ernat, MD MAJ Joseph W. Galvin, DO . Snapping Biceps Femoris Tendon. Am J Orthop.  
Publish date: July 17, 2018

MAJ Justin J. Ernat,  
MD