

[Edit Article](#)

The Aberrant Anterior Tibial Artery and its Surgical Risk

Publish date: July 20, 2018

Authors:

Yohan Jang, DO Khoa Nguyen, DO Saenz Rocky, DO

Author Affiliation | **Disclosures**

Authors' Disclosure Statement: The authors report no actual or potential conflict of interest in relation to this article.

Dr. Jang is an Orthopedic Trauma Fellow, Indiana University Health Methodist Hospital, School of Medicine, Indianapolis, Indiana. Dr. Nguyen is an Orthopaedic Joint Reconstruction Surgeon, Burlington County Orthopaedic Specialist, Mt. Laurel, New Jersey. Dr. Saenz is Director of Magnetic Resonance Imaging, Department of Radiology, Beaumont Health Botsford Hospital Affiliated Michigan State University, Farmington Hills, Michigan. Dr. Jang and Dr. Nguyen were residents at the time the article was written.

Address correspondence to: Yohan Jang, DO, Indiana University Health Methodist Hospital, Orthopaedic Surgery Trauma and Sports Medicine, 1801 N Senate Blvd, Suite 535, Indianapolis, IN 46202 (tel, 517-303-7467; email, jangyoha@msu.edu).

Am J Orthop. 2018;47(7). Copyright Frontline Medical Communications Inc. 2018. All rights reserved.

Take-Home Points

- Surgeon must understand and be aware of aberrant vascular anatomy around the knee.
- Careful evaluation of advance imaging for aberrant vascular anatomy is required in surgeries around the knee.
- When aberrant vascular anatomy is recognized, appropriate preoperative planning is required.

Most non-traumatic injuries to the popliteal artery are iatrogenic and may occur during total knee replacement,¹⁻⁸ high tibial osteotomy,^{2,3,5-7} anterior cruciate ligament reconstruction,^{2,6} posterior cruciate ligament reconstruction,^{2,6,9,10} and arthroscopic meniscectomy.^{2,6,9} Despite the rare occurrence of complications involving the popliteal artery during such procedures, results of vessel injuries can be devastating and may also lead to malpractice litigation. Anatomic variations of the distal popliteal artery and its significance in surgery have been well documented in the literature.^{2-6,8,11} However, due to lack of awareness, this issue is often unintentionally disregarded. We present the case of an aberrant anterior tibial artery that was found during the review of a magnetic resonance imaging study. The patient was provided written informed consent for print and electronic publication of this case report.

Case

A 61-year-old woman presented with a history of right knee pain from osteoarthritis that had rapidly progressed over 1 week secondary to a fall. The patient had no history of previous knee surgery. After careful evaluation of her right knee pain, treatment options were discussed. The patient agreed to proceed with total knee arthroplasty (TKA). During preoperative planning, the patient's previous magnetic resonance imaging (MRI) was reviewed. The MRI study revealed an aberrant anterior tibial artery. The popliteal artery bifurcated at the level of the knee joint (**Figures 1A-1C**). After the bifurcation, the anterior tibial artery coursed anteriorly to the tibioperoneal trunk. The anterior tibial artery is seen just anterior to the popliteus muscle and just posterior to the tibial plateau cortex (**Figure 2**). Intraoperatively, an oscillating saw was utilized for the tibial cut. Care was taken not to penetrate the posterior cortex. An osteotome was used to elevate the tibial cut and hinge it open, and with a small mallet, finish the tibial cut. The patient had a successful TKA without complication.

Discussion

Emerging from the adductor hiatus (Hunter's canal), the normal course of the popliteal artery is a position slightly lateral in the intercondylar fossa. It courses obliquely and posteriorly to the popliteus then bifurcates into the anterior tibial artery and the tibioperoneal trunk at the inferior border of the popliteus. The tibioperoneal trunk bifurcates into both the posterior tibial artery and the peroneal artery at the proximal tibia well below the knee joint.

There are many reported cases of popliteal artery variations.^{2,3,6,7,9,11-13} Variations in the popliteal artery are consequences of persistent embryonic vessels from primitive segments of the artery or abnormal fusions among them.¹⁴ According to Kim and colleagues,¹¹ variations can be classified by the modified Lippert's system. This system has 3 categories with 3 subtypes (**Table**). Variations are not uncommon and occur in 7.4% to 12% of the population.^{2,4,5,7,13} Of these variations, type IIA, a high bifurcation of the anterior tibial artery, arising at or above the knee joint from the popliteal artery is the most significant. Forty-two percent of these vessels course anterior to the popliteus and make direct contact with the cortex of the posterior tibia.⁴ It is also the most frequent variant type reported in 1.2% to 6% of the population.^{3,7,11-13}

Injury to the popliteal artery during an orthopedic procedure is believed to be under reported⁶ but is considered a rare complication. The incidence of popliteal artery injury in TKA is thought to be 0.03% to 0.2%.^{1,2,5,7,8} Vessel injury in both high tibial osteotomy and arthroscopic surgeries (lateral meniscal repair) have also been reported.^{5,6,8,10} Despite the rare occurrence of this complication, it may have devastating outcomes. The injury can be repaired with vascular grafting depending on its severity; however, it could also lead to compartment syndrome, loss of function, chronic ulcers, and necrosis of the affected limb resulting in below the knee amputation. The current consensus is that the popliteal artery moves posteriorly away from the tibia when the knee is in 90° of flexion,⁵ which is the standard position for many orthopedic knee surgeries. This position limits the risk of injuring the vessel. However, Metzdorf and colleagues,⁴ Smith and colleagues,⁶ and Zaidi and colleagues⁸ suggested that the vessel not be displaced posteriorly with flexion. These studies reported that the behavior of the popliteal artery varied among individuals since in some cases it had moved closer to the tibia in flexion when compared with extension.

Regardless of the behavior of the artery, it is protected by the popliteus muscle in most orthopedic knee surgeries since the majority course posterior to the muscle. However, in cases of Lippert's type IIA variation, it not only loses protection as it courses beneath the popliteus but also is extremely vulnerable from the close relationship to

the posterior tibial cortex. Klecker and colleagues² described the aberrant artery locations related to common orthopedic procedures, which demonstrated its close proximity to various surgical plane levels. The position of the aberrant artery is approximately 1 to 1.5 cm distal to the posterior tibial joint line, just posterior to the posterior capsule, and close to the posterior cruciate ligament insertion site where the transverse tibial cut is made during TKA. This location also corresponds to the position for an inlay block and the tibial tunnel for posterior cruciate ligament reconstruction. A transverse cut for a high tibial osteotomy is approximately 1.5 to 2.5 cm distal to the posterior tibial joint line; the aberrant artery appeared directly posterior to the tibial cortex. These relationships were equivalent findings in this case. Such relationships of the aberrant anterior tibial artery to both the posterior tibial cortex and the posterior capsule increase the risk of vessel (anterior tibial artery) injury intraoperatively. The risk further increases in a revision of total knee replacement. This is secondary to limited flexibility of the vessel from scar formation which requires a more distal incision.^{1,4}

Conclusion

Vascular injuries in knee surgeries are rare and often overlooked. Despite their low occurrence rate, outcomes of these injuries have grave consequences not only regarding medical but also legal matters. Variations in the popliteal artery are not uncommon and could potentially contribute to risks of vessel injury. Of these variations, the high originating anterior tibial artery poses a special risk. However, due to the low occurrence rate of these injuries, screening the general population may not be cost-effective. Since many patients already have obtained necessary imaging (preferably MRI), a careful review of these images along with preoperative planning and special care during surgery is recommended to identify popliteal artery variants and avoid iatrogenic vascular injury.

This paper will be judged for the Resident Writer's Award.

Key Info

Figures/Tables

Figures / Tables:

[jang0718_f1.jpg](#)

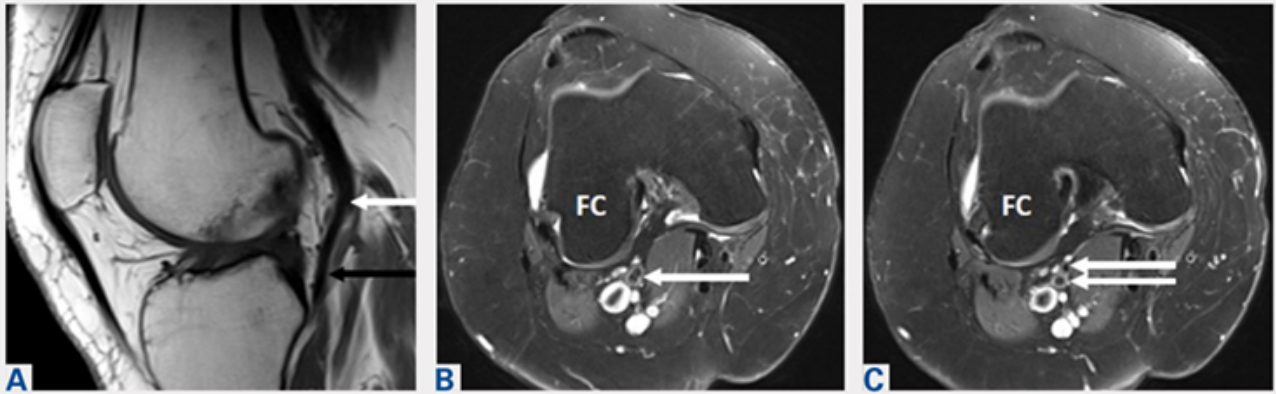


Figure 1. Sagittal T1 magnetic resonance imaging demonstrates (A) a normal flow void (black signal) of the popliteal artery which is bifurcating at the knee joint (white arrow). Notice that the anterior tibial artery is located just posterior to the posterior cruciate ligament (black arrow). (B, C) Axial proton density, fat saturation images are obtained through the upper knee joint showing the bifurcation of the popliteal artery (arrows) at the level of the femoral condyles (FC). The anterior vessel is the anterior tibial artery, and the posterior vessel is the tibioperoneal trunk.

[jang0718_f2.jpg](#)

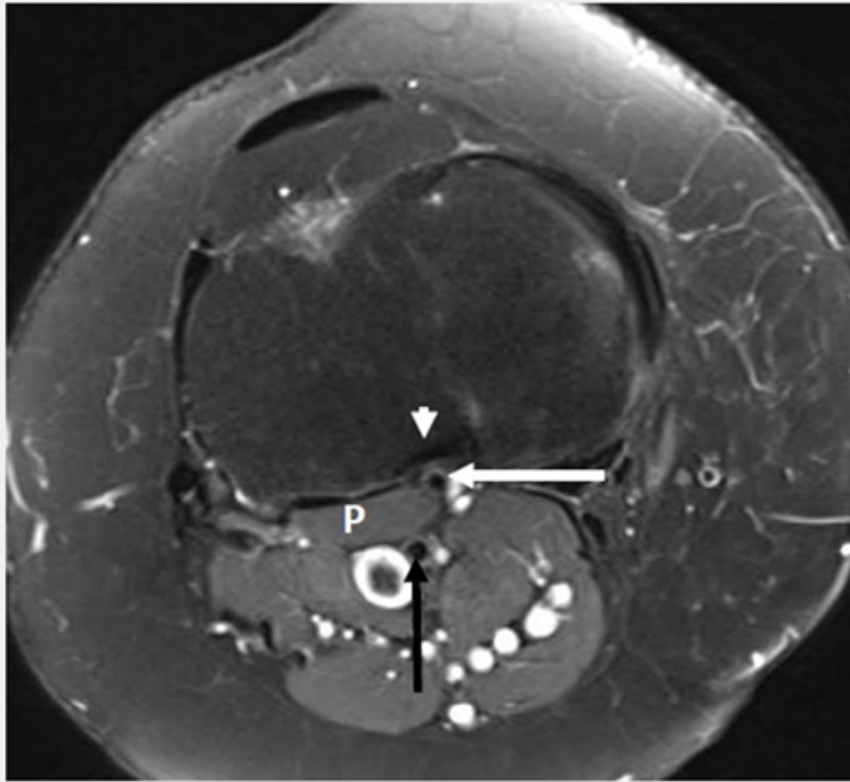


Figure 2. Axial proton density, fat saturation image shows the anterior tibial artery to be located anterior to the popliteus muscle (P) and just posterior to the tibial plateau cortex (white arrow). Also, note that the anterior tibial artery is just posterior to the fibers of the posterior cruciate ligament (arrowhead). The tibioperoneal trunk (black arrow) is seen adjacent to the popliteal vein.

Table. Modified Lippert’s System¹¹

Category (Subtype)	
I	Normal level of popliteal arterial branching
IA	Usual pattern
IB	Trifurcation- No true tibioperoneal trunk
IC	Anterior tibioperoneal trunk- Posterior tibial artery is first branch
II	High division of popliteal artery
IIA	Anterior tibial artery arises at or above the knee joint
IIB	Posterior tibial artery arises at or above the knee joint
IIC	Peroneal artery arises at or above the knee joint
III	Hypoplastic or aplastic branching with altered distal supply
IIIA	Hypoplastic-aplastic posterior tibial artery
IIIB	Hypoplastic-aplastic anterior tibial artery
IIIC	Hypoplastic-aplastic posterior and anterior tibial artery

References

References

References

1. Abdel Karim MM, Anbar A, Keenan J. Position of the popliteal artery in revision total knee arthroplasty. *Arch Orthop Trauma Surg.* 2012;132(6):861-865. doi:10.1007/s00402-012-1479-6.
2. Klecker RJ, Winalski CS, Aliabadi P, Minas T. The aberrant anterior tibial artery, magnetic resonance appearance, prevalence, and surgical implication. *Am J Sports Medicine.* 2008;36:720-727.
3. Kropman RHJ, Kiela G, Moll FL, Vries JPM. Variations in anatomy of the popliteal artery and its side branches. *Vasc Endovascular Surg.* 2011;45:536-540.
4. Metzdorf A, Jakob RP, Petropoulos P, Middleton R. Arterial injury during revision total knee replacement. A case report. *Knee Surg Sports Traumatol Arthrosc.* 1999;7:246-248.
5. Shetty AA, Tindall AJ, Qureshi F, Divekar M, Fernando KWK. The Effect of knee flexion on the popliteal artery and its surgical significance. *J Bone Joint Surg Br.* 2003;85:218-222.
6. Smith PN, Gelinis J, Kennedy K, Thain L, Rorabeck CH, Bourne B. Popliteal vessels in knee surgery; a magnetic resonance imaging study. *Clin Orthop Rel Res.* 1999;367:158-164
7. Tindall AJ, Shetty AA, James KD, Middleton A, Fernando KWK. Prevalence and surgical significance of a high-origin anterior tibial artery. *J Orthop Surg.* 2006;14:13-16.
8. Zaidi SHA, Cobb AG, Bentley G. Danger to the popliteal artery in high tibial osteotomy. *J Bone Joint Surg Br.* 1995;77:384-386.
9. Keser S, Savranlar A, Bayar A, Ulukent SC, Ozer T, Tuncay I. Anatomic localization of the popliteal artery at the level of the knee joint: a magnetic resonance imaging study. *Arthroscopy.* 2006;22:656-659.
10. Makino A, Costa-Paz M, Aponte-Tinao L, Ayerza MA, Muscolo L. Popliteal artery laceration during arthroscopic posterior cruciate ligament reconstruction. *Arthroscopy.* 2005;21(11):1396.
11. Kim D, Orron DE, Skillman JJ. Surgical significance of popliteal arterial variants, a unified angiographic classification. *Ann Surg.* 1989;210:776-781.
12. Day CP, Orme R. Popliteal artery branching patterns-an angiographic study. *Clin Radiol.* 2006;61:696-699.
13. Kil SW, Jung GS. Anatomical variations of the popliteal artery and its tibial branches: Analysis in 1242 extremities. *Cardiovasc Intervent Radiol.* 2009;32:233-240.
14. Senior HD. The development of the arteries of the human lower extremity. *Am J Anat.* 1919;25:55-94.

Multimedia

Product Guide

Product Guide

- [STRATAFIX™ Symmetric PDS™ Plus Knotless Tissue Control Device](#)
- [STRATAFIX™ Spiral Knotless Tissue Control Device](#)
- [BioComposite SwiveLock Anchor](#)
- [BioComposite SwiveLock C, with White/Black TigerTape™ Loop](#)

×

×

Citation

Yohan Jang, DO Khoa Nguyen, DO Saenz Rocky, DO . The Aberrant Anterior Tibial Artery and its Surgical Risk.
Am J Orthop.

Publish date: July 20, 2018

Yohan Jang, DO