

Successful Nonoperative Management of HAGL (Humeral Avulsion of Glenohumeral Ligament) Lesion With Concurrent Axillary Nerve Injury in an Active-Duty US Navy SEAL

Justin J. Ernat, MD, Craig R. Bottoni, MD, and Douglas J. Rowles, MD

Abstract

Humeral avulsion of the glenohumeral ligament (HAGL) is a lesion that has been recognized as a cause of recurrent shoulder instability. To our knowledge there are no reports of successful return to full function in young, competitive athletes or return to manual labor following nonoperative management of a HAGL lesion. A 26-year-old Navy SEAL was diagnosed with a HAGL injury, and associated traction injury of the axillary nerve as well as a partial tear of the rotator cuff. Operative intervention was recommended; however, due to issues with training and with inability to properly rehab with the axillary nerve injury, surgical plans were delayed. Interestingly, the patient demonstrated both clinical and radiographic magnetic resonance imaging healing of his lesion over an 18-month period. At 18 months the patient had returned to full active duty without pain or instability as a Navy SEAL.

The humeral avulsion of glenohumeral ligament (HAGL) lesion has been recognized as a cause of recurrent shoulder instability. In 1942, Nicola¹ was the first to describe this lesion, in a small case series of avulsions of the anterior band of the inferior glenohumeral ligament from the humeral neck secondary to a dislocation injury. In 1988, Bach and colleagues² described it in 2

patients with recurrent anterior dislocations. Wolf and colleagues³ were the first to apply the term HAGL to the injury, in 1995.

HAGL lesion incidence ranges from 1% to 9%, but many authors think the lesion is underdiagnosed.³⁻⁵ It occurs in isolation or in combination with other injuries, and it is commonly identified on recurrence of instability. Bui-Mansfield and colleagues⁶ found that 11% of patients with a diagnosis of HAGL lesion previously had surgery on the same shoulder, whereas for 62% the lesion was associated with other, concurrent lesions, including labral tears (18, 25%), rotator cuff tears (16, 23%), and Hill-Sachs deformities (12, 17%).

Most young athletes who undergo nonoperative therapy for a HAGL lesion continue to experience pain and/or instability that then requires surgical intervention.⁴ To our knowledge, there are no reports of return to full function in young competitive athletes or return to manual labor after nonoperative management of a HAGL lesion.

In this article, we report the case of a US Navy SEAL who sustained a traction injury causing an axillary nerve injury and a HAGL lesion. Successful nonoperative management allowed him to return to full duty. The patient provided written informed consent for print and electronic publication of this case report.

Case Report

An otherwise healthy 26-year-old Navy SEAL presented with pain and significant weakness in the right (dominant) upper extremity after an injury in a training exercise. The shoulder sustained a traction injury when the man's fast-moving marine attack

Authors' Disclosure Statement: The authors report no actual or potential conflict of interest in relation to this article. The views expressed in this article are those of the authors and do not reflect the official policy or position of the US Department of the Army, US Department of Defense, or US Government.

craft was in a collision and he was trying not to be thrown off. He reported having a sense of dislocation yet never required a reduction.

Physical examination revealed severe weakness with shoulder abduction, external rotation, and forward flexion; inability to contract the deltoid muscle; and complete numbness along the cutaneous distribution of the axillary nerve. On neurovascular examination, the right upper extremity was otherwise intact. The patient had complete passive range of motion (ROM) with apprehension in abduction with external rotation along with anterior laxity and normal posterior stability.

Standard shoulder radiographs showed no bony abnormalities and a concentrically reduced glenohumeral joint. Magnetic resonance imaging (MRI), reviewed by a staff musculoskeletal radiologist and a sports fellowship-trained orthopedic surgeon, showed a greater tuberosity contusion, a partial tear of the infraspinatus, and a HAGL lesion (**Figure 1**).

The patient was counseled toward surgical intervention to prevent symptoms of recurrent instability. A detailed discussion ensued about whether to proceed with surgery immediately or to pursue temporary nonoperative treatment to allow for assessment and return of deltoid function. Patient and surgeon decided to delay operative intervention because of concerns about the patient's ability to effectively rehabilitate while still having a compromised axillary nerve after surgery. The recommendation was to delay initial electromyographic (EMG) and nerve conduction velocity testing at least 4 weeks to allow for completion of Wallerian degeneration and more accurate assessment of the axillary nerve.⁷ Physical therapy for gentle ROM (excluding external rotation) and isometric rotator cuff exercises were initiated.

Five weeks after injury, the patient left the area to attend a 2-month nonphysical training course and continued rehabilitation and orthopedic follow-up at another military medical facility. Six weeks after injury, initial EMG testing revealed the expected axillary neuropraxia. In addition, some marginal improvement in ROM was noted, but deltoid function was still very limited.

Ten weeks after injury, clinical inspection revealed deltoid wasting. Active shoulder ROM was limited, and deltoid strength was 3/5, though the patient was able to perform a standard push-up without difficulty and showed no sign of laxity or apprehension on shoulder examination. Repeat EMG testing revealed axillary nerve denervation with no sign of regeneration. Twelve weeks after

injury, MRA showed reorganization and partial healing of the HAGL lesion relative to the prior study (**Figure 2**).

On the patient's return from training, 15 weeks after injury, he had improved active ROM and 4+/5 deltoid strength. Axillary nerve sensation was still decreased but markedly improved. Physical examination revealed no significant shoulder laxity or apprehension, and the patient denied feelings of instability. Activities were advanced to include an organized strengthening program.

Six months after injury, the patient was cleared to return to his unit with only mild physical restriction. Function continued to steadily improve. After 9 months, he was cleared for full, unrestricted

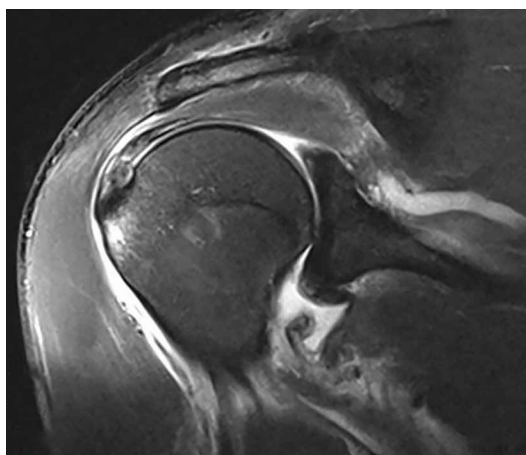


Figure 1. Coronal T2-weighted fast spin-echo magnetic resonance imaging with fat suppression shows humeral avulsion of glenohumeral ligament lesion at 5 o'clock position, partial tearing of infraspinatus, and greater tuberosity contusion.

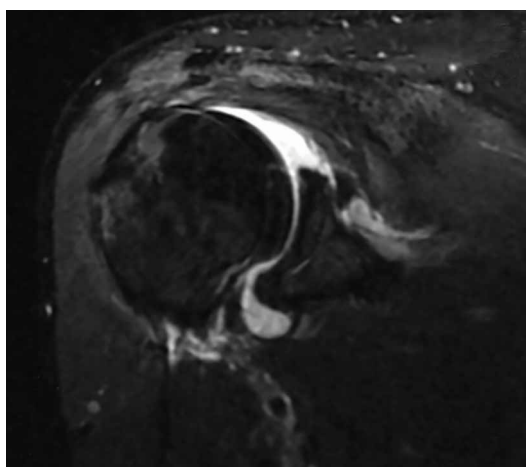


Figure 2. Twelve weeks after injury, coronal T2-weighted magnetic resonance arthrography shows partial reorganization of humeral avulsion of glenohumeral ligament lesion.

ed duty. Although he still demonstrated slight asymmetric weakness in the right deltoid with continued muscular atrophy, examination findings were otherwise normal, and he was back to full activities without significant symptoms.

Eleven months after injury, MRI showed healing of the HAGL lesion (**Figure 3**). At 17 months, EMG testing revealed significant interval improvement in axillary motor unit potentials but still about a 50% decrement compared with the noninjured side. The patient denied any motor or sensory deficits and any instability events since his injury. He continued with full function as an active-duty Navy SEAL.

Discussion

Nonoperative management has been used for injuries to the inferior glenohumeral ligament complex when there is no humeral detachment but generally has been reserved for low-demand patients and patients who cannot tolerate surgical intervention.⁴ Detached lesions may initially be managed nonoperatively with physical therapy and rehabilitation, but the rate of recurrent instability after nonoperative management of a known HAGL lesion remains unknown.⁴ Most active young people are expected to have persistent pain and/or instability and require surgical intervention. Both arthroscopic and open methods have been used successfully.^{3,8-15} Persistent instability is often the primary complaint leading to a diagnosis of a HAGL lesion.⁴ The patient in this case report neither demonstrated nor reported any instability event after his 6-month period of nonoperative management, despite his young age and elite physical requirements.

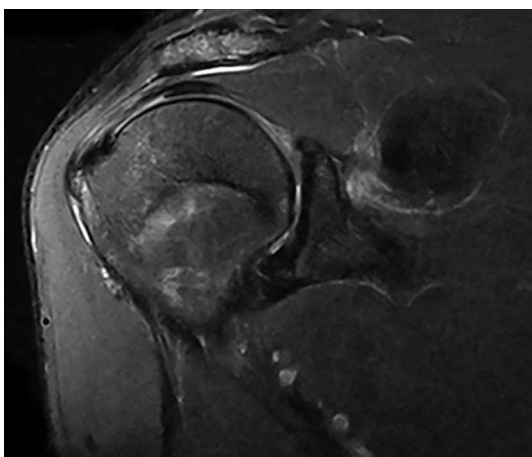


Figure 3. Eleven months after injury, coronal T2-weighted fast spin-echo magnetic resonance imaging with fat suppression shows scarring and resolution of humeral avulsion of glenohumeral ligament lesion.

To our knowledge, there are no reports of successful nonoperative management of a known symptomatic HAGL lesion in a high-demand athlete. Although we do not routinely recommend nonoperative treatment for cases such as the one reported here, the decision to delay this Navy SEAL's surgical management was made out of concern about potential complications of postoperative rehabilitation given the concurrent axillary nerve injury.

With anterior shoulder dislocations, multiple concomitant shoulder injuries, including a HAGL lesion, are not uncommon.^{6,16} With HAGL lesions, associated rotator cuff injuries occur at a rate as high as 23%.⁶ Our patient had a concurrent partial rotator cuff tear but also an axillary nerve traction injury. To our knowledge, the literature has not described axillary nerve injury specifically in association with a HAGL lesion, though it is well documented and maintained as a possible concurrent injury with anterior shoulder instability events.¹⁷ Robinson and colleagues¹⁶ found a 5.8% incidence of a clinically apparent neurologic deficit after traumatic anterior shoulder dislocation in 3633 dislocations, about 75% of which were isolated axillary nerve injuries. They also reported a 25.7% rate of rotator cuff tear or greater tuberosity fracture, either of which significantly increased the likelihood of a neurologic deficit in their study.

When nerve continuity remains, functional recovery occurs after 3 to 6 months, or within weeks in some cases.¹⁸⁻²⁰ Nerve injuries in continuity but with persistent, severe clinical deficits may require surgical exploration with subsequent neurolysis and/or repair.¹⁹⁻²¹ Our patient showed gradual axillary nerve recovery from a clinical standpoint. By 6 months after injury, despite continued muscle atrophy and decreased axillary nerve sensation, he had returned to full duty as a Navy SEAL. By 17 months, atrophy was markedly improved, and strength and ROM had subjectively returned, despite there being significant conduction amplitude losses, up to 50% of the contralateral side, on EMG testing.

This case represents a scenario in which likely initial surgical management was precluded by a concomitant injury, and the patient had a serendipitous outcome. It is possible the axillary neuropraxia and subsequent temporary deltoid dysfunction provided a unique environment that was conducive to the healing of the HAGL lesion. With classic Bankart lesions, many surgeons prefer to use aggressive early surgical treatment in first-time dislocators, especially elite athletes, in an attempt to avoid recurrent instability.²²⁻²⁶ However, some

have suggested that initial immobilization after acute injury may lead to successful nonoperative management.²⁷ Perhaps our case report raises the question as to whether a prolonged period of initial immobilization can prove successful in management of a HAGL lesion. Prospective studies comparing early surgical and nonoperative treatment of these challenging lesions are warranted.

We have reported a case of successful nonoperative management of a HAGL lesion in an active-duty Navy SEAL with concomitant shoulder injuries. This case could suggest that a trial of initial nonoperative management should be considered for injuries that involve a HAGL lesion when there are concerns about the patient's ability to complete functional rehabilitation because of the combined injuries of the shoulder.

Dr. Ernat is a Resident and Dr. Bottoni is a Staff Orthopedic Sports Surgeon, Department of Orthopedic Surgery, Tripler Army Medical Center, Honolulu, Hawaii. Dr. Rowles is a Staff Orthopedic Sports Surgeon, University of Oklahoma, Oklahoma City, Oklahoma.

Address correspondence to: Justin J. Ernat, MD, Department of Orthopedic Surgery, Tripler Army Medical Center, 1 Jarrett White Rd, Honolulu, HI 96859 (tel, 815-252-9486; fax, 808-433-1554; email, justin.ernat@gmail.com).

Am J Orthop. 2016;45(5):E236-E239. Copyright Frontline Medical Communications Inc. 2016. All rights reserved.

References

- Nicola T. Anterior dislocation of the shoulder: the role of the articular capsule. *J Bone Joint Surg.* 1942;25:614-616.
- Bach BR, Warren RF, Fronck J. Disruption of the lateral capsule of the shoulder. A cause of recurrent dislocation. *J Bone Joint Surg Br.* 1988;70(2):274-276.
- Wolf EM, Cheng JC, Dickson K. Humeral avulsion of glenohumeral ligaments as a cause of anterior shoulder instability. *Arthroscopy.* 1995;11(5):600-607.
- George MS, Khazzam M, Kuhn JE. Humeral avulsion of glenohumeral ligaments. *J Am Acad Orthop Surg.* 2011;19(3):127-133.
- Tirman PF, Steinbach LS, Feller JF, Stauffer AE. Humeral avulsion of the anterior shoulder stabilizing structures after anterior shoulder dislocation: demonstration by MRI and MR arthrography. *Skeletal Radiol.* 1996;25(8):743-748.
- Bui-Mansfield LT, Banks KP, Taylor DC. Humeral avulsion of the glenohumeral ligaments: the HAGL lesion. *Am J Sports Med.* 2007;35(11):1960-1966.
- Dumitru D, Zwarts MJ. Needle electromyography. In: Dumitru D, Amato AA, Zwarts MJ, eds. *Electrodiagnostic Medicine.* 3rd ed. Philadelphia, PA: Hanley & Belfus; 2005:257-292.
- Parameswaran AD, Provencher MT, Bach BR Jr, Verma N, Romeo AA. Humeral avulsion of the glenohumeral ligament. Injury pattern and arthroscopic repair techniques. *Orthopedics.* 2008;31(8):773-779.
- Kon Y, Shiozaki H, Sugaya H. Arthroscopic repair of a humeral avulsion of the glenohumeral ligament lesion. *Arthroscopy.* 2005;21(5):632.
- Bokor DJ, Conboy VB, Olson C. Anterior instability of the glenohumeral joint with humeral avulsion of the glenohumeral ligament: a review of 41 cases. *J Bone Joint Surg Br.* 1999;81(1):93-96.
- Field LD, Bokor DJ, Savoie FH 3rd. Humeral and glenoid detachment of the anterior inferior glenohumeral ligament: a cause of anterior shoulder instability. *J Shoulder Elbow Surg.* 1997;6(1):6-10.
- Arciero RA, Mazzocca AD. Mini-open repair technique of HAGL (humeral avulsion of the glenohumeral ligament) lesion. *Arthroscopy.* 2005;21(9):1152.
- Bhatia DN, DeBeer JF, van Rooyen KS. The "subscapularis-sparing" approach: a new mini-open technique to repair a humeral avulsion of the glenohumeral ligament lesion. *Arthroscopy.* 2009;25(6):686-690.
- Huberty D, Burkhart S. Arthroscopic repair of anterior humeral avulsion of the glenohumeral ligaments. *Tech Shoulder Elbow Surg.* 2006;7(4):186-190.
- Richards DP, Burkhart SS. Arthroscopic humeral avulsion of the glenohumeral ligaments (HAGL) repair. *Arthroscopy.* 2004;20(suppl 2):134-141.
- Robinson CM, Shur N, Sharpe T, Ray A, Murray IR. Injuries associated with traumatic anterior glenohumeral dislocations. *J Bone Joint Surg Am.* 2012;94(1):18-26.
- Visser CP, Coene LN, Brand R, Tavy DL. The incidence of nerve injury in anterior dislocation of the shoulder and its influence on functional recovery. A prospective clinical and EMG study. *J Bone Joint Surg Br.* 1999;81(4):679-685.
- Gumina S, Bertino A, Di Giorgio G, Postacchini F. Injury of the axillary nerve subsequent to recurrence of shoulder dislocation. Clinical and electromyographic study. *Chir Organi Mov.* 2005;90(2):153-158.
- Perlmutter GS. Axillary nerve injury. *Clin Orthop Relat Res.* 1999;(368):28-36.
- Saragaglia D, Picard F, Le Bredonchel T, Moncenis C, Sardo M, Tourne Y. Acute anterior instability of the shoulder: short- and mid-term outcome after conservative treatment [in French]. *Rev Chir Orthop Reparatrice Appar Mot.* 2001;87(3):215-220.
- Kline DG, Kim DH. Axillary nerve repair in 99 patients with 101 stretch injuries. *J Neurosurg.* 2003;99(4):630-636.
- Kralinger FS, Golser K, Wischatta R, Wambacher M, Sperner G. Predicting recurrence after primary anterior shoulder dislocation. *Am J Sports Med.* 2002;30(1):116-120.
- Bottoni CR, Wilckens JH, DeBerardino TM, et al. A prospective, randomized evaluation of arthroscopic stabilization versus nonoperative treatment in patients with acute, traumatic, first-time shoulder dislocations. *Am J Sports Med.* 2002;30(4):576-580.
- Handoll HH, Almayyah MA, Rangan A. Surgical versus non-surgical treatment for acute anterior shoulder dislocation. *Cochrane Database Syst Rev.* 2004;(1):CD004325.
- Jakobsen BW, Johannsen HV, Suder P, Sojbjerg JO. Primary repair versus conservative treatment of first-time traumatic anterior dislocation of the shoulder: a randomized study with 10-year follow-up. *Arthroscopy.* 2007;23(2):118-123.
- Kirkley A, Griffin S, Richards C, Miniaci A, Mohtadi N. Prospective randomized clinical trial comparing the effectiveness of immediate arthroscopic stabilization versus immobilization and rehabilitation in first traumatic anterior dislocations of the shoulder. *Arthroscopy.* 1999;15(5):507-514.
- Paterson WH, Throckmorton TW, Koester M, Azar FM, Kuhn JE. Position and duration of immobilization after primary anterior shoulder dislocation: a systematic review and meta-analysis of the literature. *J Bone Joint Surg Am.* 2010;92(18):2924-2933.

This paper will be judged for the Resident Writer's Award.