

Total Hip Arthroplasty After Proximal Femoral Osteotomy: A Technique That Can Be Used to Address Presence of a Retained Intracortical Plate

Carlos A. Uquillas, MD, James P. Ward, MD, and Joseph D. Zuckerman, MD

Abstract

Total hip arthroplasty (THA) can be challenging in the setting of internal fixation devices previously placed in the proximal femur. When these devices are used in adolescent patients, endosteal hypertrophy can lead to significant bony overgrowth. Removal of these implants can result in significant cortical defects that may compromise the results of THA.

This article describes a technique that can be used when a plate applied to the lateral femoral cortex has become “intracortical” as a result of extensive bony overgrowth. In using this technique to avoid plate removal, the surgeon eliminates the need for more extensive procedures aimed at compensating for deficiency of the femoral cortex in the area of plate removal.

Total hip arthroplasty (THA) is an effective treatment for advanced hip arthritis from a variety of causes, including osteoarthritis, inflammatory arthritis, posttraumatic arthritis, and sequelae of developmental disorders. It is not uncommon to perform THA in the presence of a previous proximal femoral osteotomy that may have been performed for slipped capital femoral epiphysis (SCFE), Legg-Calvé-Perthes disease, or developmental dysplasia of the hip, among other conditions. These osteotomies are commonly combined with internal fixation, a plate-and-screw device. These patients are at risk for developing degenerative arthritis at an earlier age than patients with other types of arthritis and subsequently may undergo

THA at a younger age.¹⁻³ Presence of a plate can pose a technical challenge during THA surgery. THA performed after intertrochanteric osteotomy has higher rates of perioperative and postoperative complications.⁴ Ferguson and colleagues⁴ noted difficulty during hardware removal in 24% of cases. Among the complications encountered were broken hardware, stripped screws, greater trochanteric fracture, stress risers from previous screw holes, canal narrowing from endosteal hypertrophy around hardware, and lateral cortical deficiency after removal of the side plate. As intertrochanteric osteotomies are often performed in patients who have yet to reach skeletal maturity, cortical hypertrophy can lead to complete coverage of the side plate and an “intracortical” position.

This article reports on 2 THA cases in which a technique was used to avoid intracortical plate removal and the resulting problems of lateral cortical deficiency. During each THA, the plate was left in place to avoid compromise of the lateral femoral cortex. The patients provided written informed consent for print and electronic publication of these case reports.

Case Reports

Case 1

An adolescent with bilateral SCFE was treated first with internal fixation of the right hip and subsequently with left proximal femoral osteotomy with internal fixation. He did well until age 31 years, when he developed progressively worsening pain about the left hip. Clinical findings and imaging studies were consistent with advanced degenerative arthritis of the left hip. Radiographs showed a sliding hip screw in place, with proximal femoral deformity consisting of femoral neck shortening and posterior angulation (**Figures 1A, 1B**). Preoperative Harris Hip Score was 54.5.

Authors' Disclosure Statement: The authors report no actual or potential conflict of interest in relation to this article.

Case 2

A 51-year-old woman presented with a history of right hip problems dating back to age 13 years, when she sustained a fracture of the right hip and was treated with internal fixation. At age 15 years, she underwent proximal femoral osteotomy to correct residual deformity. She did well until age 45 years, when she developed worsening hip symptoms. Clinical findings and imaging studies were consistent with advanced degenerative arthritis of the right hip. Radiographs showed a fixed-angle blade plate in the proximal femur, with significant proximal femoral deformity (**Figures 1C, 1D**). Preoperative Harris Hip Score was 53.6.

Surgical Technique

In both cases, a standard series of radiographs was obtained—an anteroposterior (AP) radiograph of the pelvis and AP and cross-table lateral radiographs of the operative hip (Figure 1). Computed tomography (CT) with a metal-artifact-reducing technique may be useful in determining amount of cortical bone remaining under the plate. CT showed limited lateral cortex beneath the side plate and bony overgrowth covering the side plate. Preoperative templating was performed using previously described techniques.⁵

During THA, before removing any portion of any retained hardware, the surgeon should perform 3 important actions: Dislocate the hip, perform all appropriate capsular releases, and reduce the hip. Dislocating the hip before hardware removal significantly decreases the risk for fracture caused by stress risers, as the force required for dislocation is much more controlled because of the capsular releases. After hardware removal, the hip can be easily redislocated, and the femoral neck osteotomy can be performed.

When plate and screws are in an intracortical position, the screws can be removed only after removing the small shell of cortical bone covering them. The amount of bone to be removed is minimal. After the screws are removed, the plate remains in place. A motorized device with a metal-cutting attachment is used to transect the construct at the junction of the plate and barrel (case 1) or at the bend of a fixed-angle device (case 2). Laparotomy sponges are placed around the proximal femur to minimize the amount of soft tissue that could be exposed to metal shavings. Copious irrigation is used throughout this part of the procedure. Osteotomes are used to elevate the proximal portion of the plate and the barrel, preserving the distal portion of the plate on the

lateral cortex of the femoral shaft.

After the head is removed, the rest of the THA can be performed using standard press-fit insertion technique (**Figures 2A-2D**). Care must be taken to ensure that the distal aspect of the femoral stem bypasses the most distal screw hole by at least 2 cortical diameters in order to reduce the risk for periprosthetic fracture.

By 2-year follow-up, both patients had regained excellent range of motion, ambulation, and overall function. Postoperative Harris Hip Scores were

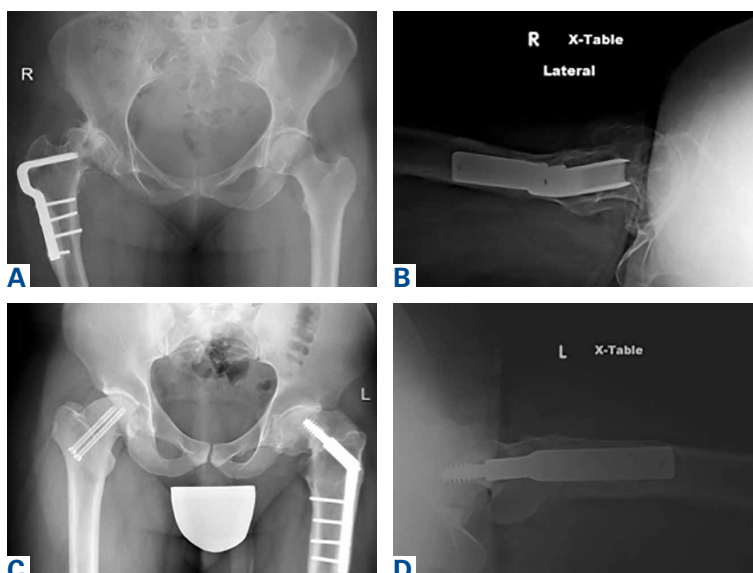


Figure 1. Preoperative (A) case 1 anteroposterior radiograph of pelvis, (B) case 1 cross-table lateral radiograph of left hip, (C) case 2 anteroposterior radiograph of pelvis, and (D) case 2 cross-table lateral radiograph of right hip.

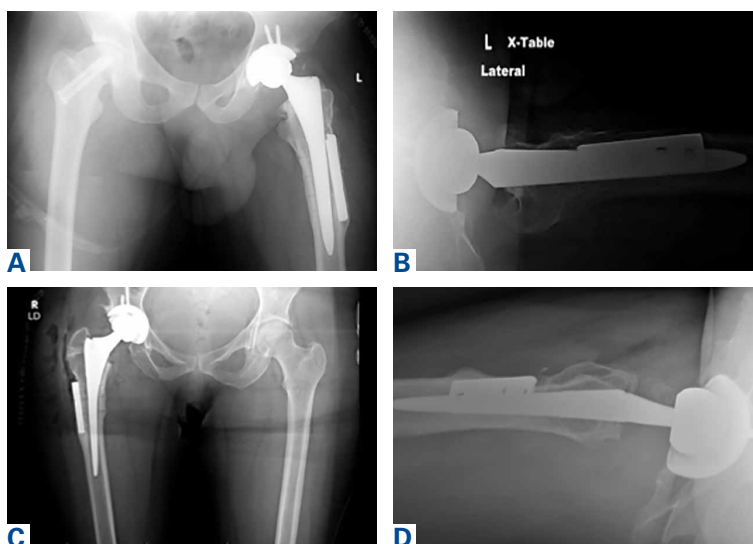


Figure 2. Postoperative (A) case 1 anteroposterior radiograph of pelvis, (B) case 1 cross-table lateral radiograph of left hip, (C) case 2 anteroposterior radiograph of pelvis, and (D) case 2 cross-table lateral radiograph of right hip.

86.6 and 83.8, respectively. There were no radiographic signs of complications.

Discussion

THA can be challenging in the setting of previously placed internal fixation devices, particularly devices inserted during a patient's adolescence, as significant bony overgrowth can occur. The standard approach has been to remove the internal fixation device and then perform the THA. In most cases, and particularly when the internal fixation device is in an intracortical position, the result is significant compromise of bone. This article describes a technique in which a portion of the hardware is retained to avoid compromise of the lateral femoral cortex, thereby allowing insertion of a noncemented femoral component.

THA is the most effective procedure for reducing hip pain and disability in the setting of degenerative changes.⁶ Patients with SCFE, Legg-Calvé-Perthes disease, or developmental dysplasia of the hip generally are younger at the time they may be sufficiently symptomatic to consider THA.^{7,8} Many have had previous surgery using internal fixation devices. THAs after previous osteotomies with internal fixation devices are more technically demanding, require more operative time, are subject to more blood loss, and have a higher rate of complications, including femoral fracture. Ferguson and colleagues⁴ and Boos and colleagues⁹ found these surgeries were more difficult 33.8% and 36.8% of the time, respectively. For these reasons, some authors have recommended removing the internal fixation device as soon as the osteotomy is healed.⁴ However, this has not become the standard of care, and surgeons continue to perform THAs in the presence of a previous osteotomy with an internal fixation device in place.

The technique described in this article was used successfully in 2 cases. In each case, leaving the intracortical plate in place avoided compromise of the lateral femoral cortex and allowed insertion of a noncemented femoral component without complication. Of course, with the screw holes representing stress risers, careful insertion of the femoral component was required. Retaining the intracortical plate allowed it to function as part of the lateral femoral cortex, thereby maintaining the structural integrity of the femoral canal. As has been described for the 2 cases, a blade plate and plate and barrel were converted to a limited intracortical plate by removing the proximal portion of the plates—a modification that could be applied to

other types of internal fixation devices that extend into the femoral neck as long as appropriate cutting tools are available.

Conclusion

THA in the setting of a retained internal fixation device is relatively common. This article describes a technique that can be used when a plate applied to the lateral femoral cortex has become intracortical as a result of extensive bony overgrowth. In using this technique to avoid plate removal, the surgeon eliminates the need for more extensive procedures aimed at compensating for deficiency of the femoral cortex in the area of plate removal. Although only 2 cases are presented here, this technique potentially can be used more broadly in these specific clinical situations.

Dr. Uquillas is a Surgeon, Kerlan Jobe Orthopaedic Clinic, Los Angeles, California. He was Chief Resident, Hospital for Joint Disease, Langone Medical Center, New York University, New York, New York at the time this article was written. Dr. Ward is a Surgeon and Dr. Zuckerman is Professor and Chairman, Department of Orthopaedic Surgery, Hospital for Joint Diseases, Langone Medical Center, New York University, New York, New York.

Address correspondence to: Carlos A. Uquillas, MD, Kerlan Jobe Orthopaedic Clinic, 6801 Park Terrace, Suite 500, Los Angeles, CA 90045 (tel, 240-620-2018; fax, 212-598-6581; email, carlos.uquillas@gmail.com).

Am J Orthop. 2016;45(4):E224-E226. Copyright Frontline Medical Communications Inc. 2016. All rights reserved.

References

- Engesaeter LB, Engesaeter IO, Fenstad AM, et al. Low revision rate after total hip arthroplasty in patients with pediatric hip diseases. *Acta Orthop.* 2012;83(5):436-441.
- Froberg L, Christensen F, Pedersen NW, Overgaard S. The need for total hip arthroplasty in Perthes disease: a long-term study. *Clin Orthop Relat Res.* 2011;469(4):1134-1140.
- Furnes O, Lie SA, Espehaug B, Vollset SE, Engesaeter LB, Havelin LI. Hip disease and the prognosis of total hip replacements. A review of 53,698 primary total hip replacements reported to the Norwegian Arthroplasty Register 1987-99. *J Bone Joint Surg Br.* 2001;83(4):579-586.
- Ferguson GM, Cabanela ME, Ilstrup DM. Total hip arthroplasty after failed intertrochanteric osteotomy. *J Bone Joint Surg Br.* 1994;76(2):252-257.
- Scheerlinck T. Primary hip arthroplasty templating on standard radiographs. A stepwise approach. *Acta Orthop Belg.* 2010;76(4):432-442.
- Wroblewski BM, Siney PD. Charnley low-friction arthroplasty of the hip. Long-term results. *Clin Orthop Relat Res.* 1993;(292):191-201.
- Chandler HP, Reineck FT, Wixson RL, McCarthy JC. Total hip replacement in patients younger than thirty years old. A five-year follow-up study. *J Bone Joint Surg Am.* 1981;63(9):1426-1434.
- Dorr LD, Luckett M, Conaty JP. Total hip arthroplasties in patients younger than 45 years. A nine- to ten-year follow-up study. *Clin Orthop Relat Res.* 1990;(260):215-219.
- Boos N, Krushell R, Ganz R, Müller ME. Total hip arthroplasty after previous proximal femoral osteotomy. *J Bone Joint Surg Br.* 1997;79(2):247-253.