

# Subungual Exostosis

James D. Russell, MD; Kurt Nance, BS; Julia R. Nunley, MD; Ian A. Maher, MD

## PRACTICE POINTS

- Subungual exostosis is a benign tumor that is most common on the hallux.
- Plain radiographs can identify an exostosis and should be part of the initial workup of any subungual tumor.
- Surgical excision is an effective and well-tolerated treatment of subungual exostosis.

*Subungual exostosis is an uncommon bony tumor of the distal phalanx most often seen on the hallux. Although this lesion is completely benign, it must be distinguished from a number of other subungual tumors, both benign and malignant. Radiography of the digit is a noninvasive test that should be part of the initial workup whenever subungual exostosis is in the differential diagnosis. Once identified, surgical removal of the exostosis generally is both effective and well tolerated. We present a case of subungual exostosis that was discovered incidentally during a full-body skin examination. We also review the pertinent clinical and histopathologic findings, diagnosis, and treatment of this entity.*

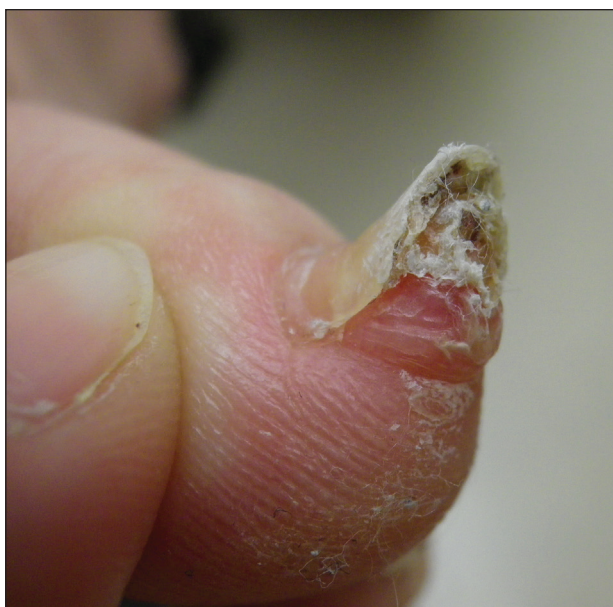*Cutis.* 2016;98:128-129.

## Case Report

A 41-year-old man with no dermatologic history presented for a skin examination. During a full-body skin examination, a lesion was identified on the right third toe that was partially visible underneath the nail plate. The patient stated that the lesion had been present for many years and did not appear to be

growing but did cause occasional pain. On examination a 1-cm verrucous, hyperkeratotic, tan papule was noted at the distal end of the nail bed causing partial onycholysis (Figure 1). It was not tender to palpation.

A shave biopsy was obtained of the visible portion of the lesion, which revealed hyperkeratosis, acanthosis, and a population of dermal spindle cells in a myxoid stroma that could not be definitively identified. Special stains were nondiagnostic. The patient was referred to dermatologic surgery for



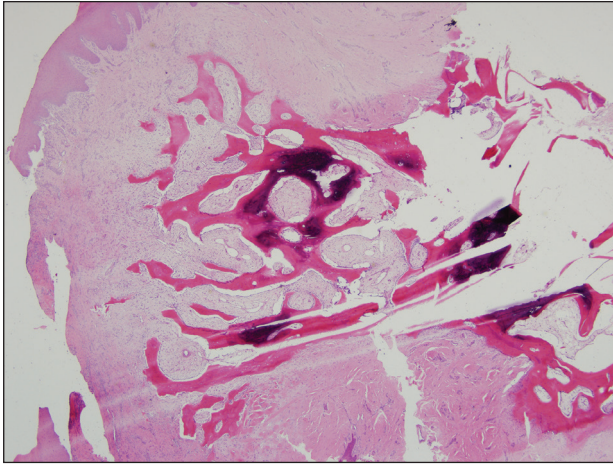
**Figure 1.** A 1-cm firm, hyperkeratotic subungual papule on the right third toe.

---

Drs. Russell and Nunley and Mr. Nance are from the Department of Dermatology, Virginia Commonwealth University, Richmond. Dr. Maher is from the Department of Dermatology, Saint Louis University, Missouri.

The authors report no conflict of interest.

Correspondence: James D. Russell, MD, Department of Dermatology, Virginia Commonwealth University, 401 N 11th St, Ste 520, Richmond, VA 23298 (DrJamesRussell@gmail.com).



**Figure 2.** Underneath a hyperkeratotic and acanthotic epidermis, a focus of mature bone was seen embedded in the dermis (H&E, original magnification  $\times 20$ ).

rebiopsy of the lesion after removal of the nail plate. Mature bone was seen embedded in the dermis (Figure 2), and a diagnosis of subungual exostosis was made. Radiography of the digit confirmed a bony excrescence from the tuft of the toe, and the patient was referred to orthopedic surgery for definitive excision. There was no evidence of recurrence at 1-year follow-up.

### Comment

Subungual exostosis is an uncommon benign bone tumor located beneath or adjacent to the nail bed on the dorsal aspect of the distal phalanx.<sup>1</sup> Although it can occur on any digit, 70% to 80% of cases have arisen on the distal phalanx of the hallux.<sup>2</sup> Both sexes are equally susceptible. The majority of lesions occur during the second or third decades of life and usually are asymptomatic unless there is trauma or infection. Growth of the lesion over time can cause lifting or deformity of the nail plate and can cause slight discomfort while walking if located on the great toe.<sup>3</sup> Common differential diagnoses include osteochondroma, wart, fibroma, paronychia, myositis ossificans, and pyogenic granuloma.<sup>3,4</sup> Diagnosis can be confirmed with radiography, which should be performed prior to any biopsy or invasive procedure. In our patient, initial radiography could have obviated the need for 2 biopsies prior to definitive excision. Histopathologic evaluation typically reveals mature trabecular bone (Figure 2) surrounded by a fibrocartilage cap.

Subungual exostosis begins as an area of proliferating fibrous tissue with cartilaginous metaplasia located beneath or adjacent to the nail bed on the

dorsal aspect of the distal phalanx.<sup>1</sup> This cartilage undergoes enchondral ossification and is converted to trabecular bone. As the lesion grows and matures, the cartilaginous cap blends imperceptibly with the nail bed and comes into continuity with the underlying distal phalanx.<sup>1,3</sup> This process continues until the lesion fuses completely with the distal phalanx.<sup>1</sup> Although the cause of subungual exostosis has not been clearly established, chronic irritation, trauma, and chronic infections are considered causative factors of fibrocartilaginous metaplasia.<sup>4</sup>

The most commonly accepted treatment of subungual exostosis is a localized excision. Partial or total removal of the nail has traditionally been advocated to ensure complete excision of the exostosis, a nail-sparing technique that has been shown to enhance cosmetic results.<sup>3</sup> Incomplete excision and incomplete maturation of the lesion have been reported to be responsible for almost 50% of recurrences.<sup>3</sup> This high recurrence rate is due to difficulty in ensuring a total excision because the gradual merging of the fibrocartilage cap with the overlying nail bed makes it impossible to develop a cleavage plane<sup>5</sup>; as a result, it has been suggested that excision should only be attempted after maturation of the tumor so the cleavage plane can fully develop. Other studies claim that delaying treatment can result in elevation and deformity of the nail, pain, and secondary periungual infection.<sup>3</sup>

### Conclusion

Subungual exostosis is a benign bony tumor of the distal phalanx that can cause pain and onycholysis. Radiography of the affected digit is a noninvasive way to confirm the diagnosis and should be part of the initial workup of any suspicious subungual tumor. Once identified, complete removal of the exostosis by excision has been shown to be an effective treatment with few complications.

### REFERENCES

1. Letts M, Davidson D, Nizalik E. Subungual exostosis: diagnosis and treatment in children. *J Trauma.* 1998;44:346-349.
2. Starnes A, Crosby K, Rowe DJ, et al. Subungual exostosis: a simple surgical technique. *Dermatol Surg.* 2012; 38:258-260.
3. Lokiec F, Ezra E, Krasin E, et al. A simple and efficient surgical technique for subungual exostosis. *J Pediatr Orthop.* 2001;21:76-79.
4. Turan H, Uslu M, Erdem H. A case of subungual exostosis. *Indian J Dermatol Venereol Leprol.* 2012;78:186.
5. Miller-Breslow A, Dorfman HD. Dupuytren's (subungual) exostosis. *Am J Surg Pathol.* 1988;12:368-378.