

# Cutaneous Metastasis of Endometrial Carcinoma: An Unusual and Dramatic Presentation

Benjamin Bashline, DO; Kelli Danowski, DO; Jessica Ghaferi, MD; Ann LaFond, MD

## PRACTICE POINTS

- Cutaneous metastases of endometrial carcinoma are extremely rare and typically present in areas of direct local spread.
- As with other cutaneous metastases, lesions often are nonspecific, making history and histopathology essential for diagnosis.

Endometrial carcinoma is a common gynecologic malignancy in the United States, but it rarely progresses to disseminated disease. Cutaneous metastases are rare because of routine gynecologic examinations and early surgical intervention when any atypia is identified. Lesions vary morphologically, often presenting as large, painless, hemorrhagic nodules, and are difficult to distinguish from other cutaneous metastases, requiring careful examination of the patient's history and histopathologic findings. We report a case of cutaneous metastasis of endometrial carcinoma 4 years following a hysterectomy and bilateral salpingo-oophorectomy.

*Cutis.* 2019;103:217-218.

## Case Report

A 62-year-old woman presented with multiple large friable tumors of the abdominal panniculus. The patient also reported an unintentional 75-lb weight loss over the last 9 months as well as vaginal bleeding and fecal discharge from the vagina of 2 weeks' duration. The patient had a surgical and medical history of a robotic-assisted hysterectomy and bilateral salpingo-oophorectomy performed 4 years prior to presentation. Final surgical pathology showed complex atypical endometrial hyperplasia with no adenocarcinoma identified.

Physical examination revealed multiple large, friable, exophytic tumors of the left side of the lower abdominal panniculus within close vicinity of the patient's

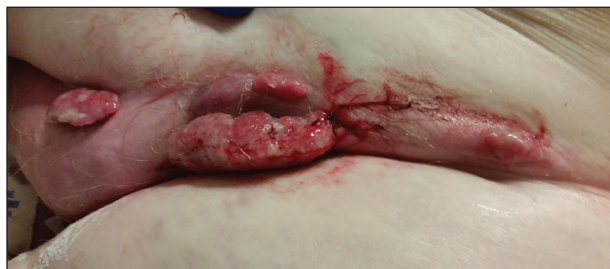abdominal hysterectomy scars (Figure 1). The largest lesion measured approximately 6 cm in length. Laboratory values were elevated for carcinoembryonic antigen (5.9 ng/mL [reference range, <3.0 ng/mL]) and cancer antigen 125 (202 U/mL [reference range, <35 U/mL]). Computed tomography of the abdomen and pelvis revealed diffuse metastatic disease.

Excisional biopsy revealed an exophytic tumor with focal ulceration with diffuse proliferation of atypical glandular epithelium and hemorrhage (Figure 2). Staining for cytokeratin (CK) 7 was diffusely positive (Figure 3), and staining for both CK20 and CDX2 was negative, suggesting a genitourinary origin of the primary tumor.

Based on the patient's medical history of atypical endometrial hyperplasia and the histopathologic findings, a diagnosis of metastatic endometrial carcinoma was made. Due to the extent of the metastases, the patient was placed on hospice care and died shortly thereafter.

## Comment

*Incidence and Pathogenesis*—Endometrial carcinoma is the most common gynecologic malignancy in the United States,

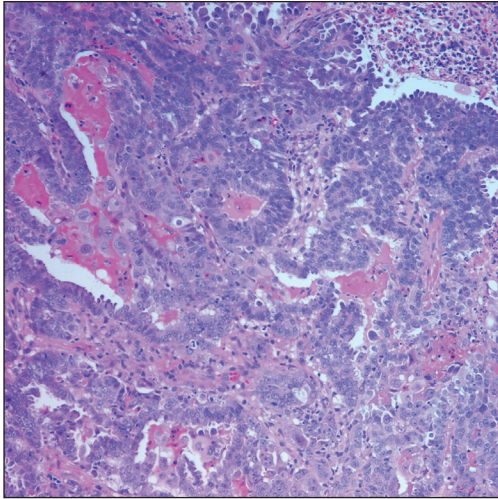


**FIGURE 1.** Metastatic endometrial carcinoma. Large, friable, exophytic tumors of the lower abdominal panniculus.

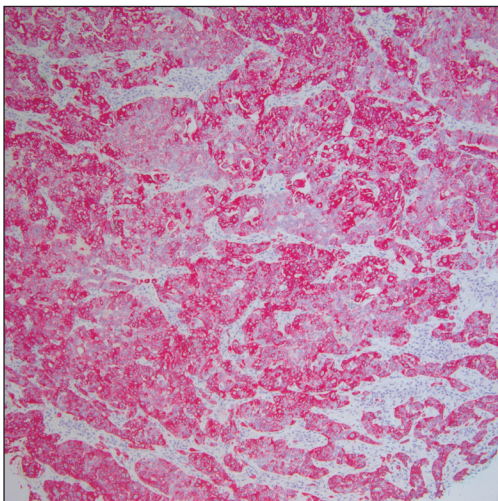
Dr. Bashline is from The Dermatology Group, West Orange, New Jersey. Dr. Danowski is from WellSpan Dermatology, York, Pennsylvania. Drs. Ghaferi and LaFond are from St. Joseph Mercy Hospital, Ann Arbor, Michigan.

The authors report no conflict of interest.

Correspondence: Benjamin Bashline, DO (benjamin.bashline@gmail.com).



**FIGURE 2.** Excisional biopsy revealed diffuse dermal proliferation of atypical glandular epithelium and hemorrhage (H&E, original magnification  $\times 20$ ).



**FIGURE 3.** Positive staining for cytokeratin 7 (original magnification  $\times 20$ ).

but it rarely progresses to disseminated disease because of routine gynecologic examinations and the low threshold for surgical intervention. Cutaneous metastases represent one of the rarest presentations of disseminated disease, occurring in only 0.8% of those diagnosed with endometrial carcinoma.<sup>1</sup> Cutaneous metastases occur almost exclusively in women older than 50 years and typically appear several months to years after hysterectomy. Although the exact pathogenesis is unknown, it is theorized that small foci of malignant cells may be seeded during surgery, leading to visceral and cutaneous involvement.

**Clinical Presentation**—Lesions vary morphologically, most commonly presenting as nonspecific, painless, hemorrhagic nodules. Lesions typically present in areas of direct local extension; prior radiotherapy; or areas of initial surgery, as was the case with our patient.<sup>2</sup> Approximately 20 cases of umbilical involvement (Sister Mary Joseph nodule) have been reported in the literature. These cases are thought to occur from direct local spread of disease from the peritoneum.<sup>3</sup> Hematogenous and lymphatic spread to distant sites such as the scalp and mandible also have been reported. More than 50% of patients will have underlying visceral metastatic disease at the time of diagnosis.<sup>3</sup>

**Histopathologic Findings**—Histopathology varies with the morphology of the underlying primary tumor, with endometrioid adenocarcinoma being the most common form associated with cutaneous metastasis, as was the case with our patient.<sup>4</sup> Histology is characterized by dermal proliferation of atypical glandular epithelium with diffuse hemorrhage. Staining typically is positive for CK7 and negative for CK20 and CDX2.<sup>5</sup> Histopathology and immunohistochemical staining are not specific for diagnosis and must be correlated with clinical history.

**Management and Prognosis**—Similar to cutaneous metastasis in other internal malignancies, prognosis is poor, as widespread dissemination of the underlying malignancy typically is present. Mean life expectancy is 4 to 12 months.<sup>6</sup> Treatment is primarily palliative, as chemotherapy and radiotherapy are largely ineffective.

## Conclusion

Our patient represents a dramatic form of cutaneous extension of a common disease. Dermatologists often are consulted because of the nonspecific nature of the lesions and must be conscious of this entity. As with other cutaneous metastases, a thorough medical and surgical history in conjunction with histopathology are necessary for an accurate diagnosis.

## REFERENCES

1. Atallah D, el Kassab N, Lutfallah F, et al. Cutaneous metastasis in endometrial cancer: once in a blue moon—case report. *World J Surg Oncol.* 2014;12:86.
2. Temkin SM, Hellman M, Lee YC, et al. Surgical resection of vulvar metastases of endometrial cancer: a presentation of two cases. *J Low Genit Tract Dis.* 2007;11:118-121.
3. Kushner DM, Lurain JR, Fu TS, et al. Endometrial adenocarcinoma metastatic to the scalp: case report and literature review. *Gynecol Oncol.* 1997;65:530-533.
4. El M'rabet FZ, Hottinger A, George AC. Cutaneous metastasis of endometrial carcinoma: a case report and literature review. *J Clin Gynecol Obstet.* 2012;1:19-23.
5. Stonard CM, Manek S. Cutaneous metastasis from an endometrial carcinoma: a case history and review of the literature. *Histopathology.* 2003;43:201-203.
6. Damewood MD, Rosenshein NB, Grumbine FC, et al. Cutaneous metastasis of endometrial carcinoma. *Cancer.* 1980;46:1471-1477.