

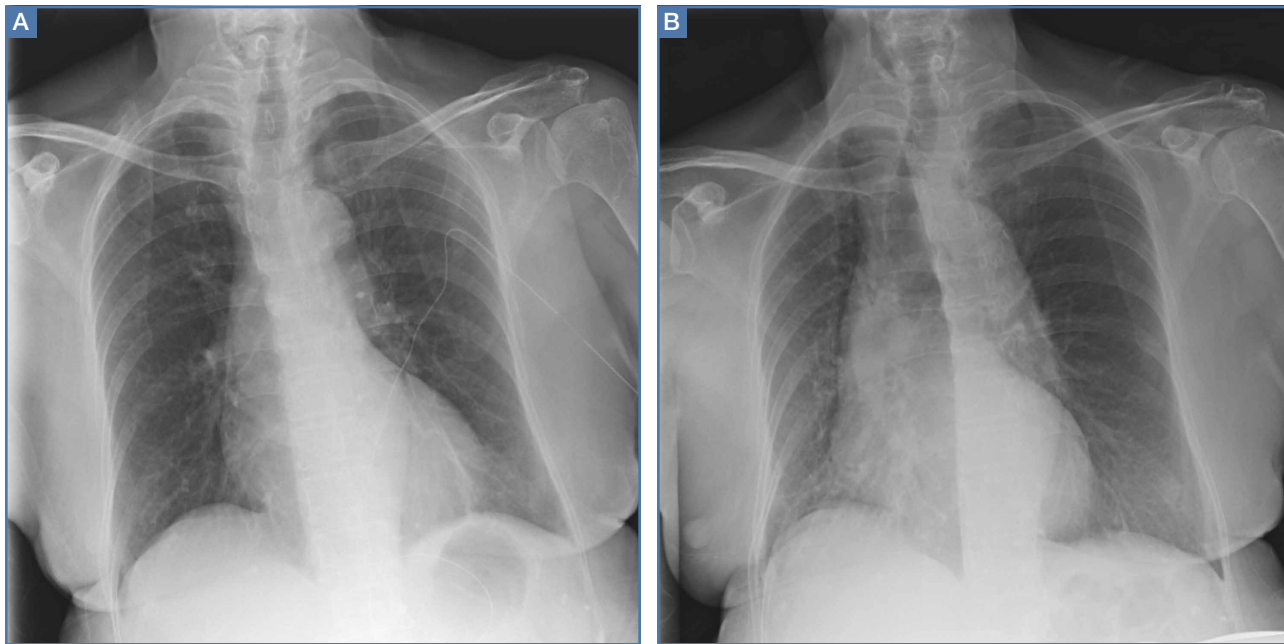Figure 1

A 79-year-old woman presented for evaluation of acute shortness of breath.

A 79-year-old woman presented to the ED with acute shortness of breath. Of note, she had been recently discharged from our hospital after an open reduction and internal fixation of an intertrochanteric fracture of the right hip. The patient's postoperative course was uncomplicated, and she was discharged home after a brief inpatient stay.

On physical examination, the patient was diaphoretic and tachypneic; oxygen saturation was 68% on room air, but increased to 100% saturation with supplemental oxygen through a nonrebreather mask. Radiographs from the patient's inpatient hospital stay (**Figure 1a**) as well as ED visit (**Figure 1b**) were reviewed; representative images are shown above.

What is the diagnosis? What additional imaging tests may be useful to confirm the diagnosis?

Dr Dean is a resident, department of radiology, Weill Cornell Medical Center, New York, New York. **Dr Hentel** is an associate professor of clinical radiology, Weill Cornell Medical College, New York, New York. He is also chief of emergency/musculoskeletal imaging and executive vice chairman, department of radiology, New York-Presbyterian Hospital/Weill Cornell Medical Center; and associate editor, imaging, of EMERGENCY MEDICINE. **Dr Fisher** is an assistant professor of radiology, Weill Cornell Medical College, New York, New York.

DOI: 10.12788/emed.2016.0048

■ Answer

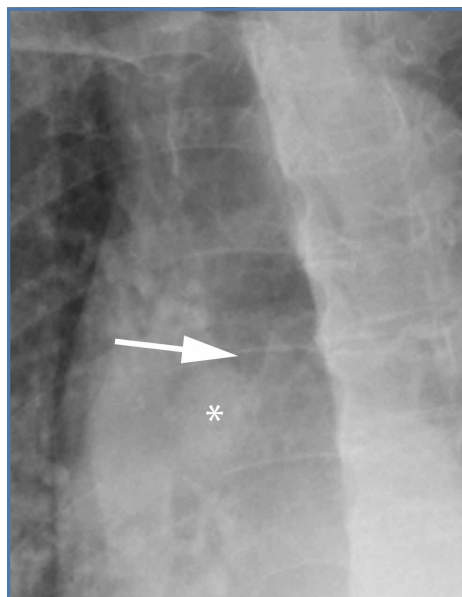


Figure 2

The radiographs taken at the time of the patient's discharge were normal. The radiograph of the chest obtained in the ED, however, demonstrated a distinct cut-off of the right mainstem bronchus, referred to as a bronchial cut-off sign (**white arrow, Figure 2**), with a rounded density projecting over the right mainstem bronchus (**white asterisk, Figure 2**). These radiographic appearances suggested the presence of an aspirated foreign body.

A computed tomography (CT) scan of the chest with contrast was performed to further evaluate the radiographic opacity and to exclude pulmonary embolism (PE), as this patient was at risk for such. The CT scan revealed no evidence of PE but confirmed the diagnosis of an aspirated foreign body. A high-density tablet (**black asterisk, Figure 3**) was noted to be completely occluding the right mainstem bronchus (**white arrow, Figure 3**) with resultant mild hyperinflation of the right lung. Upon further questioning, the patient stated that she had choked on a calcium tablet earlier in the day, but thought that the pill had finally "gone down."

Since aspiration of foreign bodies is far more common in children,^{1,2} the diagnosis often is not considered in adults who present with acute onset of shortness of breath. In adults, the most significant predisposing factor to aspiration is alcoholism. However, foreign body aspiration may arise in various clinical scenarios, including in patients with structural abnormalities, in those with neuromuscular disease, and in the postoperative setting. The most common aspirated foreign bodies are food and broken tooth fragments/periodontal devices (eg, periodontal splint).²

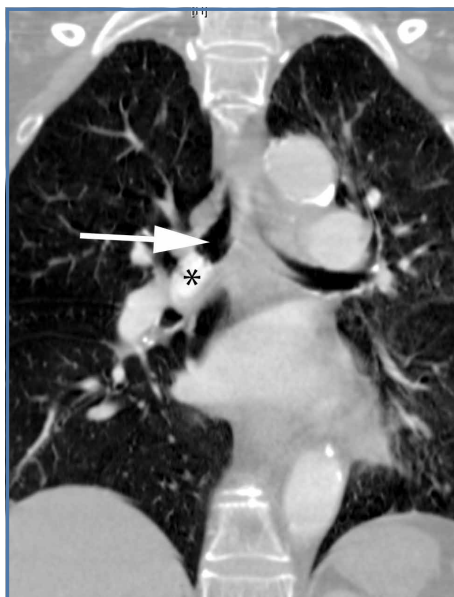

Figure 3

Presentation is varied and depends upon the nature and volume of the aspirated foreign body, which may contribute to the airway obstruction or an inflammatory bronchopneumonia. The posterior segment of the upper lobes and the superior segments of the lower lobes are the most commonly involved sites, with the right lung preferentially involved over the left lung.³

The diagnosis of foreign body aspiration begins with an appropriate clinical history. Given our patient's recent orthopedic surgery, PE was an understandable diagnostic consideration. As with any patient acutely short of breath, radiographs are the initial diagnostic imaging study of choice. An abrupt truncation of a bronchus on radiography suggests obstruction related to a mucous plugging, cancer, or foreign body aspiration. Other findings of foreign body aspiration include segmental/lobar hyperinflation and/or atelectasis.³ In many scenarios, the aspirated foreign body may not be radiodense, which limits the utility and diagnostic accuracy of radiography. Computed tomography improves diagnostic precision and time to diagnosis by directly visualizing the airway lumen and improving visualization of radiolucent objects.⁴

Treatment for obstructive aspiration depends upon the location and nature of the aspirated object. However, bedside bronchoscopy and extraction of the foreign object is the mainstay of treatment, and is how this patient was treated. Rapid diagnosis and treatment is key to alleviating obstruction and preventing potential complications of hemoptysis and infection.

References

1. Marom EM, McAdams HP, Erasmus JJ, Goodman PC. The many faces of pulmonary aspiration. *AJR Am J Roentgenol*. 1999;172(1):121-128.
2. McQuirt WF, Holmes KD, Feehs R, Browne JD. Tracheobronchial foreign bodies. *Laryngoscope*. 1988;98(6 Pt 1):615-618.
3. Franquet T, Giménez A, Rosón N, Torrubia S, Sabaté JM, Pérez C. Aspiration diseases: Findings, pitfalls, and differential diagnosis. *Radiographics*. 2000;20(3):673-685.
4. Newton JP, Abel RW, Lloyd CH, Yemm R. The use of computed tomography in the detection of radiolucent denture base material in the chest. *J Oral Rehabil*. 1987;14(2):193-202.