

Sequential Targeted Treatment for a Geriatric Patient with Acute Myeloid Leukemia with Concurrent FLT3-TKD and IDH1 Mutations

Targeting and monitoring several acute myeloid leukemia mutations sequentially provides insights into optimal treatment plans.

Ryan S. Chiang, MD; Daphne R. Friedman, MD; Kelsey McHugh, MD; Sendhilnathan Ramalingam, MD; and Vishal Vashistha, MD

Author affiliations are listed at the end of the article.

Correspondence:

Vishal Vashistha
(vishal.vashistha@va.gov)

Fed Pract. 2020;38(1): 40-43.
doi:10.12788/fp.0073

Nearly 20,000 patients are diagnosed with acute myeloid leukemia (AML) in the US annually.¹ Despite the use of aggressive chemotherapeutic agents, the prognosis remains poor, with a mean 5-year survival of 28.3%.² Fortunately, with the refinement of next-generation sequencing (NGS) hematology panels and development of systemic targeted therapies, the treatment landscape for eligible patients has improved, both in frontline and relapsed or refractory (R/R) patients.

Specifically, investigations into alterations within the FMS-like tyrosine kinase (*FLT3*) and isocitrate dehydrogenase (*IDH*) genes have led to the discovery of a number of targeted treatments. Midostaurin is US Food and Drug Administration (FDA)-approved for use in combination with induction chemotherapy for patients with internal tandem duplication of the *FLT3* (*FLT3-ITD*) gene or mutations within the tyrosine kinase domain (*FLT3-TKD*).³ Ivosidenib is indicated for frontline treatment for those who are poor candidates for induction chemotherapy, and R/R patients who have an R132H mutation in *IDH1*.^{4,5} Enasidenib is FDA-approved for R/R patients with R140Q, R172S, and R172K mutations in *IDH2*.⁶

The optimal treatment for patients with AML with ≥ 2 clinically actionable mutations has not been established. In this article we describe a geriatric patient who initially was diagnosed with AML with concurrent FLT3-TKD and IDH1 mutations and received targeted, sequential management. We detail changes in dis-

ease phenotype and mutational status by repeating an NGS hematology panel and cytogenetic studies after each stage of therapy. Lastly, we discuss the clonal evolution apparent within leukemic cells with use of ≥ 1 or more targeted agents.

CASE PRESENTATION

A 68-year-old man presented to the Emergency Department at The Durham Veterans Affairs Medical Center in North Carolina with fatigue and light-headedness. Because of his symptoms and pancytopenia, a bone marrow aspiration and trephine biopsy were performed, which showed 57% myeloblasts, 12% promyelocytes/myelocytes, and 2% metamyelocytes in 20 to 30% cellular bone marrow. Flow cytometry confirmed a blast population consistent with AML. A LeukoVantage (Quest Diagnostics) hematologic NGS panel revealed the presence of FLT3-TKD, IDH1, RUNX1, BCOR-E1477, and SF3B1 mutations (Table). Initial fluorescence in situ hybridization (FISH) results showed a normal pattern of hybridization with no translocations. His disease was deemed to be intermediate-high risk because of the presence of FLT3-TKD and RUNX1 mutations, despite the normal cytogenetic profile and absence of additional clinical features.

Induction chemotherapy was started with idarubicin, 12 mg/m², on days 1 to 3 and cytarabine, 200 mg/m², on days 1 to 7. Because of the presence of a FLT3-TKD mutation, midostaurin was planned for days 8 to 21. After induction chemotherapy, a bone marrow biopsy on day 14 revealed an acellular marrow

with no observed myeloblasts. A bone marrow biopsy conducted before initiating consolidation therapy, revealed 30% cellularity with morphologic remission. However, flow cytometry found 5% myeloblasts expressing CD34, CD117, CD13, CD38, and HLA-DR, consistent with measurable residual disease. He received 2 cycles of consolidation therapy with high-dose cytarabine combined with midostaurin. After the patient's second cycle of consolidation, he continued to experience transfusion-dependent cytopenias. Another bone marrow evaluation demonstrated 10% cellularity with nearly all cells appearing to be myeloblasts. A repeat LeukoVantage NGS panel demonstrated undetectable FLT3-TKD mutation and persistent IDH1-R123C mutation. FISH studies revealed a complex karyotype with monosomy of chromosomes 5 and 7 and trisomy of chromosome 8.

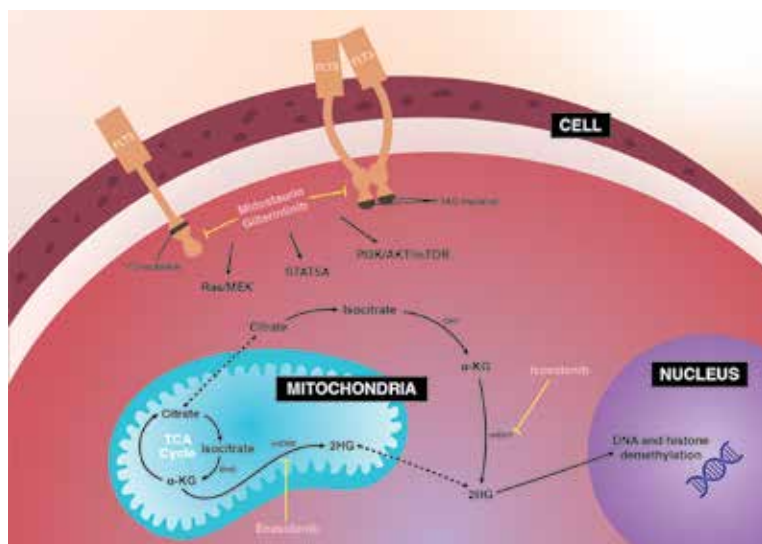
We discussed with the patient and his family the options available, which included initiating targeted therapy for his IDH1 mutation, administering hypomethylation therapy with or without venetoclax, or pursuing palliative measures. We collectively decided to pursue therapy with single-agent oral ivosidenib, 500 mg daily. After 1 month of treatment, our patient developed worsening fatigue. His white blood cell count had increased to > 43 k/cm³, raising concern for differentiation syndrome.

A review of the peripheral smear showed a wide-spectrum of maturing granulocytes, with a large percentage of blasts. Peripheral flow cytometry confirmed a blast population of 15%. After a short period of symptom improvement with steroids, the patient developed worsening confusion. Brain imaging identified 2 subdural hemorrhages. Because of a significant peripheral blast population and the development of these hemorrhages, palliative measures were pursued, and the patient was discharged to an inpatient hospice facility. A final NGS panel performed from peripheral blood detected mutations in *IDH1*, *RUNX1*, *PTPN11*, *NRAS*, *BCOR-E1443*, and *SF3B1* genes.

DISCUSSION

To our knowledge, this is the first reported case of a patient who sequentially received targeted treatments directed against both FLT3 and IDH1 mutations. Initial man-

FIGURE Mechanism of Action for Therapies Used in Treatment of Patients With AML With FLT3, IDH1, and IDH2 Mutations



Abbreviations: 2HG, 2-hydroxyglutarate; α-KG, α-ketoglutarate; AML, acute myeloid leukemia; FLT3, FMS-like tyrosine kinase; IDH, isocitrate dehydrogenase; mTOR, mechanistic target of rapamycin kinase; PI3K, phosphoinositide 3-kinases; Ras/MEK, reticular activating system/Mitogen-activated protein kinase; STAT5A, Signal transducer and activator of transcription 5A; TCA, tricarboxylic acid; TKD, tyrosine kinase domain.

agement with midostaurin and cytarabine resulted in sustained remission of his FLT3-TKD mutation. However, despite receiving prompt standard of care with combination induction chemotherapy and targeted therapy, the patient experienced unfavorable clonal evolution based upon his molecular and cytogenetic testing. Addition of ivosidenib as a second targeting agent for his IDH1 mutation did not achieve a second remission.

Clonal evolution is a well-described phenomenon in hematology. Indolent conditions, such as clonal hematopoiesis of intermediate potential, or malignancies, such as myelodysplastic syndromes and myeloproliferative neoplasms, could transform into acute leukemia through the accumulation of driver mutations and/or cytogenetic abnormalities. Clonal evolution often is viewed as the culprit in patients with AML whose disease relapses after remission with initial chemotherapy.⁷⁻¹⁰ With the increasing availability of commercial NGS panels designed to assess mutations among patients experiencing hematologic malignancies, patterns of relapse, and, models of clonal evolution could be observed closely in patients with AML.

TABLE Patient's Detected Clonal Evolution of Genetic Mutations with Allele Fractions

Mutations (Test mo/y)	Bone Marrow (01/2019), %	Peripheral Blood (04/2019), %	Bone Marrow (08/2019), %	Peripheral Blood (09/2019), %	Peripheral Blood (12/2019), %
FLT3-D835Y	17.0	-	-	-	-
IDH1-R132C	20.0	-	-	27.0	44.6
BCOR-E1477	86.0	-	-	-	-
RUNX1-S318fs*282	40.0	-	-	37.0	44.5
SF3B1-K700E	42.0	-	-	39.0	43.9
BCOR-E1443	-	3.1	-	75.0	88.7
CEBPA-Y181	-	-	-	8.1	-
NRAS-G13D	-	-	-	3.4	-
NRAS-G13R	-	-	-	-	6.5
NRAS-Q61H	-	-	-	-	16.5
PTPN11-D61A	-	-	-	10.5	5.5
WT1-R370fs*15	-	-	-	6.9	-

We were able to monitor molecular changes within our patient's predominant clonal populations by repeating peripheral comprehensive NGS panels after lines of targeted therapies. The repeated sequencing revealed that clones with FLT3-TKD mutations responded to midostaurin with first-line chemotherapy whereas it was unclear whether clones with IDH1 mutation responded to ivosidenib. Development of complex cytogenetic findings along with the clonal expansion of BCOR mutation-harboring cells likely contributed to our patient's acutely worsening condition. Several studies have found that the presence of a BCOR mutation in adults with AML leads to lower overall survival and relapse-free survival.^{11,12} As of now, there are no treatments specifically targeting BCOR mutations.

Although there are novel targeting agents with proven efficacy for both FLT3 and IDH1 mutations (Figure), it is difficult to determine which pathogenic mutation drives disease onset. No evidence suggests that these drugs could be administered in tandem. At the present time, interest is directed towards targeting all AML subclones simultaneously, which could reduce the likelihood of evolution among founder clones.^{7,10,13} In their comparison between

molecular profiles and outcomes of patients with AML, Papaemmanuil and colleagues observed that > 80% of patients with AML harbor ≥ 2 driver mutations concurrently.¹⁴ Moreover, FLT3-ITD and IDH1 mutations tend to co-occur in approximately 9 to 27% of AML cases.¹⁵⁻¹⁸ Available targeted agents for AML are relatively new and hematologists' familiarity with these drugs is continuing to grow. As the number of novel agents increases, investigations directed toward assessing the safety profile and efficacy of combining targeted agents will be beneficial for patients with AML with ≥ 1 driver mutation.

CONCLUSIONS

For our patient with AML, sequential targeted management of FLT3-TKD and IDH1 mutations was not beneficial. Higher-risk disease features, such as the development of a complex karyotype, likely contributed to our patient's poor response to second-line ivosidenib. The sequential NGS malignant hematology panels allowed us to closely monitor changes to the molecular structure of our patient's AML after each line of targeted therapy. Future investigations of combining targeted agents for patients with AML with concurrent actionable

mutations would provide insight into outcomes of treating multiple clonal populations simultaneously.

Author affiliations

Ryan Chiang is a Resident at Stanford University Medical Center, Department of Medicine in Stanford, California. **Daphne Friedman** is a Staff Physician and **Sendhilnathan Ramalingam** is a Fellow, both at Durham Veterans Affairs Medical Center in North Carolina. **Kelsey McHugh** is a Staff Pathologist at Cleveland Clinic Foundation, Department of Pathology in Cleveland, Ohio. **Vishal Vashistha** is a Staff Physician at Raymond G. Murphy New Mexico Veterans Affairs Medical Center, Section of Hematology and Oncology in Albuquerque, New Mexico. Daphne Friedman is an Associate Professor of Medicine and Sendhilnathan Ramalingam is a Fellow, both at Duke University Medical Center in Durham, North Carolina.

Disclaimer

The opinions expressed herein are those of the authors and do not necessarily reflect those of *Federal Practitioner*, Frontline Medical Communications Inc., the US Government, or any of its agencies. This article may discuss unlabeled or investigational use of certain drugs. Please review the complete prescribing information for specific drugs or drug combinations—including indications, contraindications, warnings, and adverse effects—before administering pharmacologic therapy to patients.

Author disclosures

The authors report no actual or potential conflicts of interest with regard to this article.

References

- De Kouchkovsky I, Abdul-Hay M. Acute myeloid leukemia: a comprehensive review and 2016 update. *Blood Cancer J*. 2016;6(7):e441. doi:10.1038/bcj.2016.50.
- National Cancer Institute. Cancer Stat Facts: Leukemia — acute myeloid leukemia (AML). Accessed November 4, 2020. <https://seer.cancer.gov/statfacts/html/amyl.html>
- Stone RM, Mandrekar SJ, Sanford BL, et al. Midostaurin plus chemotherapy for acute myeloid leukemia with a FLT3 mutation. *N Engl J Med*. 2017;377(5):454-464. doi:10.1056/NEJMoa1614359.
- DiNardo CD, Stein EM, de Botton S, et al. Durable remissions with ivosidenib in IDH1-mutated relapsed or refractory AML. *N Engl J Med*. 2018;378(25):2386-2398. doi:10.1056/NEJMoa1716984.
- Roboz GJ, DiNardo CD, Stein EM, et al. Ivosidenib induces deep durable remissions in patients with newly diagnosed IDH1-mutant acute myeloid leukemia. *Blood*. 2019;135(7):463-471. doi: 10.1182/blood.2019002140
- Stein EM, DiNardo CD, Pollyea DA, et al. Enasidenib in mutant IDH2 relapsed or refractory acute myeloid leukemia. *Blood*. 2017;130(6):722-731. doi:10.1182/blood-2017-04-779405.
- Jan M, Majeti R. Clonal evolution of acute leukemia genomes. *Oncogene*. 2013;32(2):135-140. doi:10.1038/onc.2012.48.
- Grove CS, Vassiliou GS. Acute myeloid leukaemia: a paradigm for the clonal evolution of cancer? *Dis Model Mech*. 2014;7(8):941-951. doi:10.1242/dmm.015974.
- Anderson K, Lutz C, van Delft FW, et al. Genetic variation of clonal architecture and propagating cells in leukaemia. *Nature*. 2011;469(7330):356-561. doi: 10.1038/nature09650.
- Ding L, Ley TJ, Larson DE, et al. Clonal evolution in relapsed acute myeloid leukaemia revealed by whole-genome sequencing. *Nature*. 2012;481(7382):506-510. doi:10.1038/nature10738.
- Terada K, Yamaguchi H, Ueki T, et al. Usefulness of BCOR gene mutation as a prognostic factor in acute myeloid leukemia with intermediate cytogenetic prognosis. *Genes Chromosomes Cancer*. 2018;57(8):401-408. doi:10.1002/gcc.22542.
- Grossmann V, Tiacci E, Holmes AB, et al. Whole-exome sequencing identifies somatic mutations of BCOR in acute myeloid leukemia with normal karyotype. *Blood*. 2011;118(23):6153-6163. doi:10.1182/blood-2011-07-365320.
- Parkin B, Ouillette P, Li Y, et al. Clonal evolution and devolution after chemotherapy in adult acute myelogenous leukemia. *Blood*. 2013;121(2):369-377. doi:10.1182/blood-2012-04-427039.
- Papaemmanuil E, Gerstung M, Bullinger L, et al. Genomic classification and prognosis in acute myeloid leukemia. *N Engl J Med*. 2016;374(23):2209-2221. doi:10.1056/NEJMoa1516192.
- DiNardo CD, Ravandi F, Agresta S, et al. Characteristics, clinical outcome, and prognostic significance of IDH mutations in AML. *Am J Hematol*. 2015;90(8):732-736. doi:10.1002/ajh.24072.
- Rakheja D, Konoplev S, Medeiros LJ, Chen W. IDH mutations in acute myeloid leukemia. *Hum Pathol*. 2012;43(10):1541-1551. doi:10.1016/j.humpath.2012.05.003.
- Lai C, Doucette K, Norsworthy K. Recent drug approvals for acute myeloid leukemia. *J H Oncol*. 2019;12(1):100. doi:10.1186/s13045-019-0774-x.
- Boddu P, Takahashi K, Pemmaraju N, et al. Influence of IDH on FLT3-ITD status in newly diagnosed AML. *Leukemia*. 2017;31(11):2526-2529. doi:10.1038/leu.2017.244.